



Paper Accepted*

ISSN Online 2406-0895

Case Report / Приказ случаја

Zoran Dudvarski^{1,2,†}, Nenad Arsović^{1,2}, Snežana Ješić^{1,2},
Vladimir Nešić^{1,2}, Biljana Međo^{1,3}, Dimitrije Nikolić^{1,4}

**Meningoencephalitis as a complication of acute otitis media
in a 11-year-old child**

Менингоенцефалитис као компликација акутног запаљења средњег ува
код 11-годишњег детета

¹ Faculty of Medicine, University of Belgrade, Belgrade, Serbia;

² Clinic of Otorhinolaryngology and Maxillofacial Surgery, Clinical Center of Serbia, Belgrade, Serbia;

³ The Intensive Care Unit, University Children's Hospital, Belgrade, Serbia;

⁴ Department of Neurology, University Children's Hospital, Belgrade, Serbia

Received: May 23, 2017

Accepted: August 18, 2017

Online First: August 25, 2017

DOI: <https://doi.org/10.2298/SARH170523164D>

* **Accepted papers** are articles in press that have gone through due peer review process and have been accepted for publication by the Editorial Board of the *Serbian Archives of Medicine*. They have not yet been copy edited and/or formatted in the publication house style, and the text may be changed before the final publication.

Although accepted papers do not yet have all the accompanying bibliographic details available, they can already be cited using the year of online publication and the DOI, as follows: the author's last name and initial of the first name, article title, journal title, online first publication month and year, and the DOI; e.g.: Petrović P, Jovanović J. The title of the article. *Srp Arh Celok Lek*. Online First, February 2017.

When the final article is assigned to volumes/issues of the journal, the Article in Press version will be removed and the final version will appear in the associated published volumes/issues of the journal.

The date the article was made available online first will be carried over.

† **Correspondence to:**

Zoran DUDVARSKI

Clinic of Otorhinolaryngology and Maxillofacial Surgery,

2 Pasterova Street, 11000 Belgrade, Serbia

E-mail: zdudvarski@open.telekom.rs

Meningoencephalitis as a complication of acute otitis media in a 11-year-old child

Менингоенцефалитис као компликација акутног запаљења средњег уха код 11-годишњег детета

SUMMARY

Introduction Acute otitis media is a very common disease in the early childhood age. Orogenic complications are divided into extracranial and intracranial. Although the introduction of antibiotics has significantly reduced the incidence of intracranial complications, they are still present. In these situations clinical picture usually develops fast, with the predominance of neurologic symptoms.

Case outline A 11-year-old boy was admitted to a tertiary health care children's hospital because of fever, agitation, altered behavior and disorder of consciousness. Based on the anamnesis, clinical examination, CT, MR and lumbar puncture, it has been established that it is a case of meningoencephalitis as a result of the complications of acute otitis media. Besides intense antibiotic and symptomatic therapy, surgical treatment was conducted as well. Firstly, mastoidectomy with the implantation of ventilation tube was done, followed by radical tympanomastoidectomy, due to the fact that there was no expected improvement. The treatment of this patient was followed by numerous complications, such as toxic hepatitis, *Mycoplasma pneumoniae* infection, and hemolytic anemia. The treatment lasted for 71 days, and the patient was discharged from the hospital in a good general condition, without the focal motor failure.

Conclusion Meningoencephalitis is unusual and rare complication of acute otitis media that requires urgent diagnostic procedure and multidisciplinary approach to the treatment. Surgical treatment of the ear should not be postponed, and the choice of surgical method must be adapted to each patient individually. Hospital treatment of these patients is often prolonged, and auditory and neurological sequelae are substantial and require long-term treatment.

Keywords: acute otitis media; intracranial complications; children

САЖЕТАК

Увод Акутно запаљење средњег уха је веома често обољење у раном дечјем узрасту. Отогене компликације се деле на екстракранијалне и интракранијалне. Увођење антибиотика је значајно смањило учесталост интракранијалних компликација, али оне још увек постоје. Клиничка слика се обично брзо развија уз преминацију неуролошких симптома.

Приказ болесника Дечак стар 11 година је примљен у терцијерну здравствену установу због повишене телесне температуре, узнемирености, измењеног понашања и поремећаја стања свести. На основу анамнезе, клиничког прегледа, КТ, МР и лумбалне пункције, утврђено је да се ради о менингоенцефалитису као компликацији акутног запаљења средњег уха. Осим интензивне антибиотске и симптоматске терапије, спроведено је и хируршко лечење: најпре мастоидектомија са имплантацијом вентилационе цевчице, а потом радикална тимпаномастоидектомија јер није дошло до очекиваног побољшања. Лечење је било праћено бројним компликацијама, као што су токсични хепатитис, инфекција са *Mycoplasma pneumoniae* и хемолитичка анемија. Лечење је трајало 71 дан, а отпуштен је из болнице у добром општем стању, без фокалних моторних испада.

Закључак Менингоенцефалитис је неуобичајена и ретка компликација акутног запаљења средњег уха која захтева хитну дијагностику и мултидисциплинарни приступ у лечењу. Хируршко лечење уха не треба одлагати, а избор хируршке методе мора бити прилагођен. Болничко лечење је често продужено, а аудиторне и неуролошке секвеле су значајне и захтевају дуготрајан третман.

Кључне речи: акутно запаљење средњег уха; интракранијалне компликације; деца

INTRODUCTION

Acute otitis media (AOM) is characterised by a sudden onset of symptoms and signs of the middle ear inflammation. This disease is very common in the early childhood, and typical symptoms are otalgia and fever. Otosopic finding of hyperemic, bulging or perforated tympanic membrane with secretion, indicate AOM. When AOM diagnosis is uncertain, it is necessary to perform pneumatic otoscopy or tympanometry in order to assess the presence of secretion in the middle ear. The application of the adequate guides greatly helps the diagnostics and treatment of AOM, and represents the integral part of a routine clinical practice [1,2]. The occurrence of complications in AOM depends

on several factors, such as age, virulence of pathogens, immunological system of the patient, presence of comorbidities and previous therapy. Otogenic complications are most common in recurrent acute bacterial otitis and exacerbation of chronic inflammatory processes of the middle ear. Sometimes they can be the first sign of inflammation of the middle ear. The most common extracranial complications (ECC) of AOM are mastoiditis and subperiosteal abscess, while the most common intracranial complications (ICC) of AOM are meningitis, cerebral abscess, epidural abscess and sigmoid sinus thrombosis [3,4].

Despite the introduction of effective antibiotic therapy, the rate of otogenic ICC is still about 8%, and the mortality rate is 5-26% [5,6]. Symptoms and signs that indicate the development of otogenic ICC are dizziness, instability of walk, headache, vomiting, fever, visual field disorders, altered behavior and disorder of consciousness. In cases of AOM with ICC, clinical picture usually develops quickly, with a predominance of neurological symptoms. High level of clinical suspicion of ICC, computed tomography (CT) with intravenous contrast, magnetic resonance imaging (MRI) with venography and lumbar puncture with the analysis of cerebrospinal fluid enable an early diagnosis. Therapeutic approach in these cases has to be multidisciplinary and adapted to each patient individually, and besides intense antibiotic and symptomatic therapy, surgical treatment is required as well. In spite of all measures taken in treatment, the prognosis is sometimes uncertain.

The objective of this paper is to show fulminant course of AOM with the development of meningoencephalitis in a 11-year-old boy, dilemmas and complications that existed during treatment, as well as significant auditory and neurological sequelae.

CASE REPORT

A 11-year-old boy was admitted to a tertiary-care children's hospital in the early morning hours in December, 2014 because of fever, agitation, altered behavior and disorder of consciousness. The score on the Glasgow Coma Scale was 5/15. The previous day, the patient complained of headache and pain in the left ear, and then he vomited. During the night, the boy woke up confused, agitated, and vomited again. Except for that, personal and family history of the patient had no particularities, no data about previous ear disease, and he was regularly vaccinated according to the calendar of vaccination. Laboratory analysis of blood on admission: total leukocytes $12.3 \times 10^9/L$ (94.5% neutrophils), C-reactive protein 249 mg/L, Procalcitonin 51.2 ng/mL. CT scan showed moderate diffuse cerebral edema and signs of inflammation in the left middle ear, mastoid and petrosal apex, without tegmen erosion (Figure 1). After that, lumbar puncture was performed: cerebrospinal fluid was turbid with a mass of leukocytes (94% polymorphonuclear). Treatment was started with Vancomycin, Meropenem and Metronidazole, according to recommendations from the literature [7].

In the cerebrospinal and blood samples cause of infection was not detected. On the second day after admission, there was a spontaneous perforation of the tympanic membrane and purulent

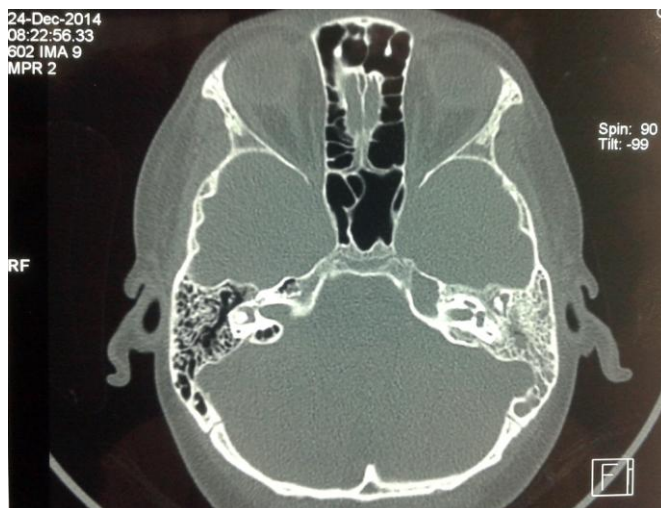


Figure 1. Axial CT scan showed soft tissue opacity of the middle ear, mastoid and petrosal apex on the left side.

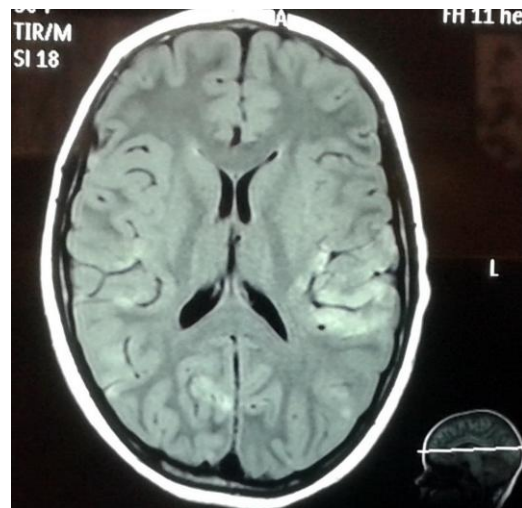

Figure 2. Axial MRI showed multiple inflammatory and ischemic changes in brain tissue.

secretion from the left ear. *Streptococcus pneumoniae* was detected in swab taken from the left ear. Due to the appearance of convulsions, Phenobarbital and Midazolam were introduced into therapy. Electroencephalography showed signs of severe encephalopathy. Cerebral MRI with angiography showed meningitis and disseminated multiple inflammatory and ischemic changes in brain tissue. Cranial venous sinuses had a normal caliber and blood flow, with no signs of thrombosis (Figure 2).

On the fifth day after admission mastoidectomy with myringotomy and implantation of ventilation tube was done. During the surgery, we found that tympanic membrane had healed in place of spontaneous perforation and after myringotomy, abundant purulent content from the middle ear was obtained. Mastoid cavity was completely filled with inflamed mucosa and granulation tissue. Osteolytic changes were present in the intercellular septa, but bone integrity to the middle and posterior cranial fossa was preserved. Histopathologic findings pointed to a non-specific granulation tissue. Postoperatively, the patient showed an improvement in the state of consciousness and motor skills, but after a few days, we registered an increase in laboratory parameters of inflammation and fever. Antibiotic therapy is changed to Cefepime and Clindamycin, but without significant improvement in the clinical picture. Medical advisory board decided that radical tympanomastoidectomy must be performed in order to provide a more complete removal of the pathological process, and it was done 8 days after the first operation.

During hospitalization, the patient received parenteral antibiotic therapy for 7 weeks. As a result of long-term antibiotic treatment, toxic hepatitis has been developed (AST 620 U/L, ALT 575 U/L). One of the complications during hospitalization was serologically proven *Mycoplasma pneumoniae* infection, when Azithromycin was included in the treatment. Infection had been complicated with hemolytic anemia and the patient received 2 doses of concentrated red blood cells.

The patient spent 71 days in hospital. He was discharged from the hospital in a good general condition, without the focal motor failure. By applying intensive physical therapy the patient was able

to walk independently, sphincter control was normal, he understood orders, but aphasia was present. Due to the inability of oral feeding, the patient was discharged with nasogastric tube that is well tolerated. Finally, the immunological tests performed during hospitalization showed that the patient was immunocompetent.

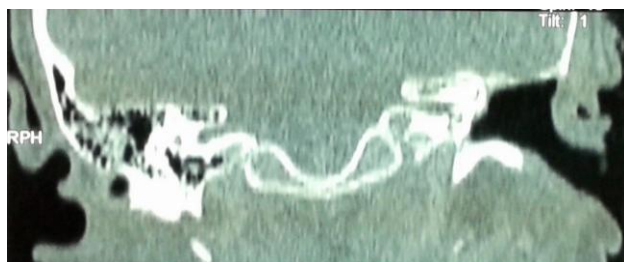

Figure 3. Coronal CT scan after radical tympanomastoidectomy showed normal findings.

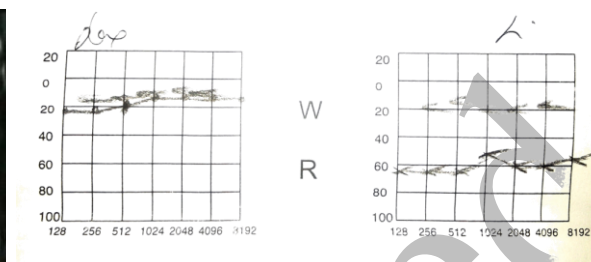


Figure 4. Pure tone audiogram after treatment showed moderate conductive hearing loss in the left ear.

After discharge from the hospital our patient began intensive therapy with a psychologist and speech therapist. The results were good and this boy has successfully completed the 5th grade of primary school. On the last medical checkup that was done a year and a half after hospital treatment, clinical and CT findings (Figure 3) were normal and audiometric finding corresponded to surgery performed (Figure 4).

DISCUSSION

The diagnosis of AOM is not always easy, especially when considering the facts that this disease is most common in the first two years of life, and that clinical picture can be dominated by symptoms of respiratory and gastrointestinal tract. For children older than 6 months with the presence of very prominent symptoms and signs of AOM (intense pain that lasts more than 48 hours and body temperature $\geq 39^{\circ}\text{C}$), as well as for children of 6-23 months with bilateral AOM and moderate symptoms and signs of disease, the antibiotic therapy is recommended. Also, the choice of antibiotics, adequate dose and the length of therapy are very important [1, 2]. Unfortunately, we are still not able to predict which patient will have a poor response or which will develop severe complications.

Streptococcus pneumoniae is the most common cause of complications of AOM in children and some studies present disturbing data on increasing resistance to antibiotics [4, 8, 9]. Recent studies confirm hypothesis that serotypes with high invasive potential causes invasive pneumococcal disease in younger patients with less comorbidity [10]. In our case, *Streptococcus pneumoniae* was isolated from the secretions of the left ear, but serotyping had not been done for technical reasons. Clinicians should recommend pneumococcal conjugate vaccine and annual influenza vaccine to all children according to updated schedules [1].

According to literature data, other causes of complications in AOM are *Pseudomonas aeruginosa*, *Streptococcus pyogenes*, *Haemophilus influenzae* and *Staphylococcus aureus* [3, 4].

Some researches indicate a possible role of anaerobic bacteria in the occurrence of ICC in pediatric population with acute mastoiditis [8].

The development of otogenic ICC is thought to occur by one of three pathophysiological mechanisms: direct extension of infection through bone weakened by osteomyelitis or cholesteatoma; retrograde spread of infection by thrombophlebitis; or extension of infection along preformed pathways, such as the oval and round windows, or through dehiscence that is the result of congenital malformations. Histological researches on temporal bones of the infants who died due to otogenic meningitis have shown the presence of chronic inflammatory cells in the round window membrane, perilymph, modiolus and cochlear aqueduct, which indicates a possible „silent“ route of the infection spread from the middle ear towards the endocranium [11]. Later researches on temporal bones indicate the connection between the presence of bacteria in fibrous matrix in the ear with chronic pathologic changes and tympanogenic meningitis in infants. In 82% of the cases the presence of bacteria was detected in fibrous matrix at different locations in the middle and inner ear, and most often around oval and round window [12]. Chronic inflammatory changes in the middle ear behind the intact eardrum and the absence of otologic symptoms can lead to occurrence of serious complications in infants [11, 12]. In our case, the fulminant course of disease indicates a possible hematogenic spread of the infection from the middle ear to the endocranium, with the occurrence of a severe form of meningoencephalitis. All data point at an accidental infection in an immunocompetent child.

Chronic otitis media with cholesteatoma is the most common cause of ICC [13, 14]. Djeric et al. [13] in an extensive retrospective study recorded 114 cases of otogenic ICC over the time period of 23 years. The most common was meningitis, followed by brain abscess and lateral sinus thrombosis. Half of the patients had two or more complications at the same time, and otogenic abscess were often combined with meningitis. For that reason, the authors emphasize the importance of CT scan in the diagnostics of the ICC, especially in the abscesses of a „silent“ clinical course, when the treatment of the active phase of chronic otitis with antibiotics can conceal early symptoms of the occurrence of this complication [15]. Dankuc et al. [16] describe a simultaneous existence of ECC and ICC in the adult patient with the exacerbation of chronic suppurative otitis. The authors describe the protective role of dura mater in the localization of subdural abscess, but also a possibility of further spread of the infection by hematogenic way into the brain tissue with the creation of the encephalitis focus and brain abscess later.

In the era of antibiotics, ICC of AOM is rarely seen. De Oliveira Penido et al. [3] recorded only 10 cases of AOM with ICC during the period of 22 years, and observed that the complications generally occur in people younger than 15 years, as well as in the elderly population. Mattos et al. [4] recorded 26 cases of ICC in children with AOM during the 15-year period. Interestingly, meningitis was recorded only in one case, while encephalitis is not recorded in any case. Leskinen and Jero [17] in the 10-year retrospective study at pediatric population describes extradural abscess with meningitis

as the only ICC of AOM. Zernotti et al. [18] describe one case of encephalitis and subdural empyema as a complication of AOM. In contrast, Krivopalov et al. [19] recorded meningoenephalitis as a complication of AOM in 15.4% of adult patients.

During the treatment of our patient we were faced with several dilemmas. How long it takes to wait for surgical treatment, because it is about a comatose patient? Then, which surgical method is the right choice in such a case? Zanetti et al. [20] in a study of 45 children with acute mastoiditis discover ICC in 28.9% of cases. They advise mastoidectomy in the first 48-72 hours, if neurological status allows this. In 2 cases with severe ICC canal wall down surgery was performed. Other authors also propose extended mastoidectomy in the treatment of meningoenephalitis, which is the result of AOM [19]. In a study published by De Oliveira Penido et al. [3] all patients with AOM and ICC were surgically treated. Neurosurgical treatment was performed in 6 patients in order to evacuate the cerebral abscess, while 4 patients were treated with otosurgical procedures (tympanocentesis in 3 patients and tympanomastoidectomy in one patient). In our case, convulsive seizures and neurological status did not allow the surgery in the first few days, and mastoidectomy with the implantation of ventilation tube did not lead to an improvement of consciousness and general condition of the patient. Consequently, it raises the following question whether it was necessary to immediately perform radical surgery in order to have a more complete removal of the pathological process, considering cause of infection and inflammation which is affecting deep retrofacial and infracochlear cell tract together with retrolabyrinthine cells and petrous apex.

During the treatment of our patient we met a number of complications, such as inability of oral feeding, inability to control sphincter, confinement to bed, toxic hepatitis, infection by *Mycoplasma pneumoniae*, and hemolytic anemia. Considering all the above, it is not surprising that our patient stayed in the hospital for 71 days, which is significantly higher compared to some data from the literature [3]. Some authors recorded that 29.4% of patients with otogenic ICC has neurological sequelae in the form of abducens nerve palsy, reduction of intellectual capacity, dysmetria and dysarthria [3]. In our patient neurological sequelae in the form of occasional agitation and aphasia significantly improved by adequate teamwork, while unilateral conductive hearing loss is only auditory sequelae.

In conclusion, meningoenephalitis is unusual and rare complication of AOM. Fulminant course of disease requires urgent diagnostic procedure and multidisciplinary approach to the treatment. Surgical treatment of the ear which caused the complication should not be delayed, and the choice of surgical method must be adapted to each patient individually. Hospital treatment of these patients is often prolonged, and auditory and neurological sequelae are substantial and require long-term treatment.

REFERENCES

1. Lieberthal AS, Carroll AE, Chonmaitree T, Ganiats TG, Hoberman A, Jackson MA, et al. The diagnosis and management of acute otitis media. *Pediatrics*. 2013; 131(3): 964–99.
2. Le Saux N, Robinson JL, Canadian Paediatric Society Infectious Diseases and Immunization Committee. Management of acute otitis media in children six months of age and older. *Paediatr Child Health* 2016; 21(1): 39–44.
3. De Oliveira Penido N, Chandrasekhar SS, Borin A, De Albuquerque Maranhao AS, Gurgel Testa JR. Complications of otitis media - a potentially lethal problem still present. *Braz J Otorhinolaryngol*. 2016; 82(3): 253–62.
4. Mattos JL, Colman KL, Casselbrant ML, Chi DH. Intratemporal and intracranial complications of acute otitis media in a pediatric population. *Int J Pediatr Otorhinolaryngol*. 2014; 78(12): 2161–4.
5. Yorgancilar E, Yildirim M, Gun R, Bakir S, Tekin R, Gocmez C, et al. Complications of chronic suppurative otitis media: a retrospective review *Eur Arch Otorhinolaryngol* 2013; 270(1): 69–76.
6. Osmar U, Cureoglu S, Hosoglu S. The complications of chronic otitis media: report of 93 cases. *J Laryngol Otol* 2000; 114(2): 97–100.
7. Dowell SF, Butler JC, Giebink GS, Jacobs MR, Jernigan D, Musher DM, et al. Acute otitis media: management and surveillance in an era of pneumococcal resistance – a reports form the drug-resistant Streptococcus pneumoniae Therapeutic Working Group. *Pediatr Infect Dis J*. 1999; 18(1): 1–9.
8. Zevallos JP, Vrabec JT, Williamson RA, Giannoni C, Larrier D, Sulek M, et al. Advanced pediatric mastoiditis with and without intracranial complications. *Laryngoscope*. 2009; 119(8): 1610–5.
9. Anthonsen K, Høstmark K, Hansen S, Andreassen K, Juhlin J, Homøe P, et al. Acute mastoiditis in children: a 10-year retrospective and validated multicenter study. *Pediatr Infect Dis J*. 2013; 32(5): 436–40.
10. Ahl J, Littorin N, Forsgren A, Odenholt I, Resman F, Riesbeck K. High incidence of septic shock caused by Streptococcus pneumoniae serotype 3 - a retrospective epidemiological study. *BMC Infect Dis*. 2013; 13: 492–9.
11. Djeric D, Schachern P, Paparella M, Jaramillo M, Haruna S, Bassioni M. Otitis media (silent): a potential cause of childhood meningitis. *Laryngoscope* 1994; 104(12): 1453–60.
12. Yildirim-Baylan M, Schachern P, Tsuprun V, Shiabata D, Paparella M, Cureoglu S. The pathology of silent otitis media: A predecessor to tympanogenic meningitis in infants. *Int J Pediatr Otorhinolaryngol* 2014; 78(3): 451–4.
13. Đerić D, Arsović N, Đorđević V. Pathogenesis and methods of treatment of otogenic brain abscess. *Med Pregl*. 1998; 51(1-2): 51–5.
14. Nešić V, Janošević Lj, Stojičić G, Janošević S, Rasulić L, Babac S, Sladoje R. Otogenic brain abscess. *Srp Arh Celok Lek* 2002; 130: 389–93.
15. Đerić D, Đorđević V, Đurović B. A quiet clinical course in an otogenic brain abscess. *Med Pregl*. 1999; 52(11–12): 505–7.
16. Dankuc D, Milošević D, Savić L. Simultaneous extracranial and intracranial otogenic complications. *Med Pregl*. 2000; 53(7–8): 409–12.
17. Leskinen K, Jero J. Complications of acute otitis media in children in southern Finland. *Int J Pediatr Otorhinolaryngol*. 2004; 68(3): 317–24.
18. Zernotti ME, Casarotto C, Tosello ML, Zernotti M. Incidence of complications of otitis media. *Acta Otorrinolaringol Esp*. 2005; 56(2): 59–62.
19. Krivopalov AA, Yanov YK, Astashchenko SV, Shcherbuk AY, Artyushkin SA, Vakhrushev SG, et al. Features of otogenic intracranial complications at the present stage. *Vestn Khir Im I I Grek*. 2015; 174(6): 68–79.
20. Zanetti D, Nassif N. Indications for surgery in acute mastoiditis and their complications in children. *Int J Pediatr Otorhinolaryngol*. 2006; 70(7): 1175–82.