



Paper Accepted\*

ISSN Online 2406-0895

**Preliminary Report / Претходно саопштење**

Dragan Krasić<sup>1,2</sup>, Zoran Pešić<sup>1,2</sup>, Dragan Mihailović<sup>1,3</sup>,  
Miloš Trajković<sup>2</sup>, Nikola Živković<sup>1,3,†</sup>, Staša Krasić<sup>4</sup>

**Clinical analysis and surgical treatment of frontal sinus mucoceles: 10  
years experience with seven cases**

Клиничка анализа и хируршко лечење мукокела чеоног синуса: 10 година  
искуства са седам болесника

<sup>1</sup>University of Niš, Faculty of Medicine, Niš, Serbia;

<sup>2</sup>Clinic of Dentistry, Niš, Niš, Serbia;

<sup>3</sup>Institute for Pathology, Niš, Serbia;

<sup>4</sup>University of Belgrade, School of Medicine, Belgrade, Serbia

**Received: October 7, 2016**

**Accepted: May 24, 2017**

**Online First: May 30, 2017**

**DOI: <https://doi.org/10.2298/SARH161007118K>**

\* **Accepted papers** are articles in press that have gone through due peer review process and have been accepted for publication by the Editorial Board of the *Serbian Archives of Medicine*. They have not yet been copy edited and/or formatted in the publication house style, and the text may be changed before the final publication.

Although accepted papers do not yet have all the accompanying bibliographic details available, they can already be cited using the year of online publication and the DOI, as follows: the author's last name and initial of the first name, article title, journal title, online first publication month and year, and the DOI; e.g.: Petrović P, Jovanović J. The title of the article. *Srp Arh Celok Lek*. Online First, February 2017.

When the final article is assigned to volumes/issues of the journal, the Article in Press version will be removed and the final version will appear in the associated published volumes/issues of the journal. The date the article was made available online first will be carried over.

† **Correspondence to:**

Nikola Živković, PhD, MD

Department of Pathology, Blvd. dr Zorana Djindjica 81, 18000 Niš, Serbia

E-mail: [nikolazivkovich@gmail.com](mailto:nikolazivkovich@gmail.com)

## Clinical analysis and surgical treatment of frontal sinus mucocoeles: 10 years experience with seven cases

Клиничка анализа и хируршко лечење мукокела чеоног синуса: 10 година искуства са седам болесника

### SUMMARY

**Introduction/Objective** A mucocoele is a benign cystic, but extremely expansive change in paranasal cavities. The etiology of mucocoeles is still a subject of discussions. It is assumed that the obstruction of the frontal sinus duct and drainage impairment into the middle nasal meatus, as a consequence of a chronic infection, trauma or tumor.

The aim of this study was to describe clinical properties and surgical treatment of frontal sinus mucocoeles.

**Methods** Our retrospective study covered a period of 10 years during which seven patients with mucocoele in the frontal sinus.

**Results** Predisposing factors for the appearance of frontal sinus mucocoeles were observed in 6 out of 7 patients: the existence of a previous surgical intervention in 2, the existence of a previous injury in 4, one patient does not exhibit the existence of predisposing factors. 4 out of 7 mucocoeles were located in the rear segments of the frontal sinus. The destruction of the anterior sinus wall was observed in one patient, while in 3 the process propagation toward the endocranium and the orbit was present. In 2 out of 3 patients with transfacial approaches, postoperative epistaxis was noted.

**Conclusion** Transcranial and transfacial approaches stand for treatment methods for advanced mucocoeles with a present intraorbital, intracranial and endonasal process propagation.

**Keywords:** mucocoeles, frontal sinus, diagnostic, surgery treatment

### САЖЕТАК

**Увод/Циљ** Мукокела је бенигна цистична, али веома пространа промена у параназалним шупљинама. Етиологија је још предмет дискусије, а претпоставља се да је опструкција дренаже фронталног синуса, оштећења у средњем носном меатусу, или последица хроничне инфекције, траума или тумора.

Циљ овог истраживања је био да се опише клиничке карактеристике и хируршко лечење мукокела фронталног синуса.

**Метод** Ретроспективна студија за период од 10 година и седам болесника са мукокелама фронталног синуса.

**Резултати** Предиспонирајући фактори за настанак мукокеле фронталног синуса су уочене у 6 болесника: претходна хируршке интервенције у 2, претходна повреда у 4, а код једног не постоје предиспонирајући фактори. Четири мукокела се налазило у задњим сегментима фронталног синуса. Уништење предњег синусног зида уочено је код једног болесника, а код три процес се простирао у ендокранијум и орбиту. У два од три болесника са трансфацијалним приступом, јавила се постоперативна епистакса.

**Закључак** Транскранијални и трансфацијални приступи су методе лечења за мукокеле са интраорбиталном, интракранијалном и ендоназалном пропацијом.

**Кључне речи:** мукокела, фронтални синус, дијагностика, хируршко лечење

### INTRODUCTION

A mucocoele is a benign cystic, but extremely expansive change in paranasal cavities, first described in literature by Langenbeck in 1820 [1].

The etiology of mucocoeles is still a subject of discussions and debates in scientific circles and it has not been defined in great detail. It is assumed that the obstruction of the frontal sinus duct and drainage impairment into the middle nasal meatus, as a consequence of a chronic infection, trauma or tumor, represent one of the main causes of their occurrence [2].

The growth and development of mucocoeles are very slow and can last for several years. The appearance of symptoms is associated with complications of the process spreading outside the sinuses, as a consequence of bone destruction, or with a secondary infection when we talk about mucopyocoele [3].

Given the direct contact of the frontal sinus with the brain parenchyma, orbit and nasal cavity, a possible extension of mucocoeles towards them represents one of the complications of advanced and, in most cases, late diagnosed mucocoeles.

Ophthalmological disorders in terms of diplopia, upper lid ptosis, proptosis, bulbus dislocation and periorbital swelling stand for the symptoms of the process spreading toward the orbit [4]. Intracranial extension developed as a consequence of the posterior sinus wall destruction may cause meningitis, meningoencephalitis, pneumocephalus, brain abscess and cerebrospinal liquid extravasation [5]. Mucocoele expansion towards the nasal cavity leads to nose obstruction and the appearance of anosmia [6]. Headaches and swelling in the orbit area represent key reasons why patients turn to doctors.

The aim of this study was to describe ophthalmological and clinical properties of these lesions, analyze used surgical approaches, and present the incidence of recurrence and complications of surgical treatments.

## **METHODS**

The conducted study is retrospective. It covered a period of 10 years during which, after surgical examinations, complete diagnostics and preparation, seven patients with pathohistologically confirmed mucocoele in the frontal sinus were operated on. All patients were operated on using endotracheal anesthesia at the Department of Maxillofacial Surgery, Dental Clinic, the Faculty of Medicine in Niš, between 2002 and 2012. The analysis included the gender and age of patients, the presence of a chronic disease, predisposing factors, clinical characteristics, surgical approach type, recurrence and postoperative complications of all patients. The minimal period of monitoring each patient was two years.

Prior to surgical treatments, in the observation stage, multi-slice computed tomography (MSCT) was done in all patients to determine the location of mucocoeles, the presence of bone destruction of sinus walls and the extension rate toward the orbit, brain parenchyma or nasal cavity.

## **RESULTS**

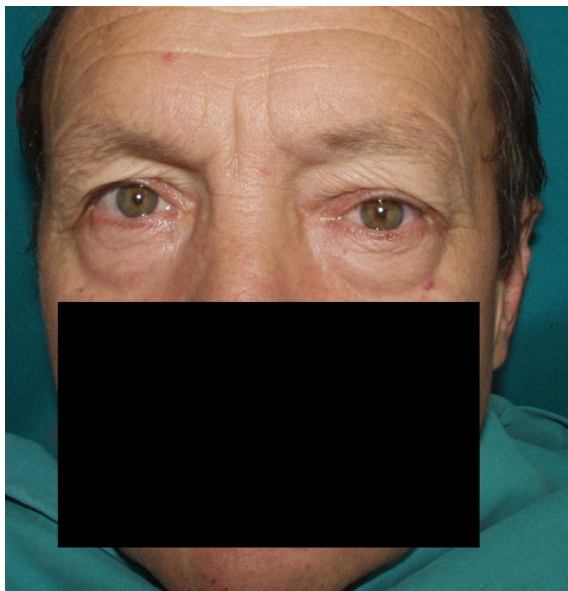The mean age of the mentioned group of patients was 56 with age interval from 28 to 65 years. As for gender, 4 out of 7 patients were males, whereas 3 out of 7 patients included in the study were females.

The presence of chronic diseases was noted in 6 out of 7 patients, chronic artery hypertension in 5 out of 6 patients, Diabetes Mellitus in 2 out of 6 patients, and chronic obstructive pulmonary disease in only one patient, 14%.

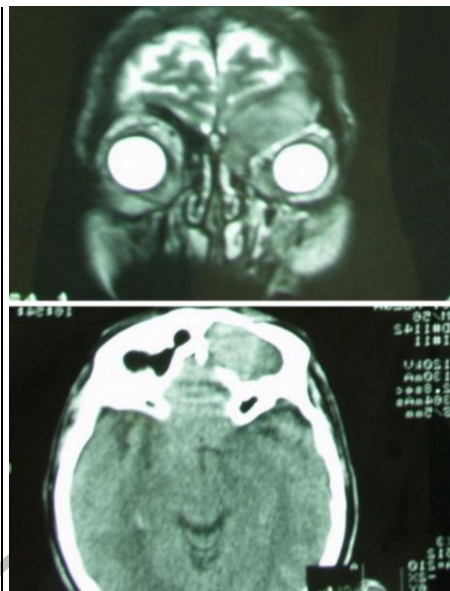
Predisposing factors for the appearance of frontal sinus mucocoeles were observed in 6 out of 7 patients, the existence of a previous surgical intervention in 2 out of 7 patients, the existence of a

previous injury in 4 out of 7 patients, whereas one patient does not exhibit the existence of predisposing factors.

4 out of 7 mucoceles were located in the rear segments of the frontal sinus. The destruction of the anterior sinus wall, dura infiltration and intracranial propagation process were observed in one patient, while in 3 out of 7 patients, the process propagation toward the endocranium and the orbit was present (Figures 1, 2).

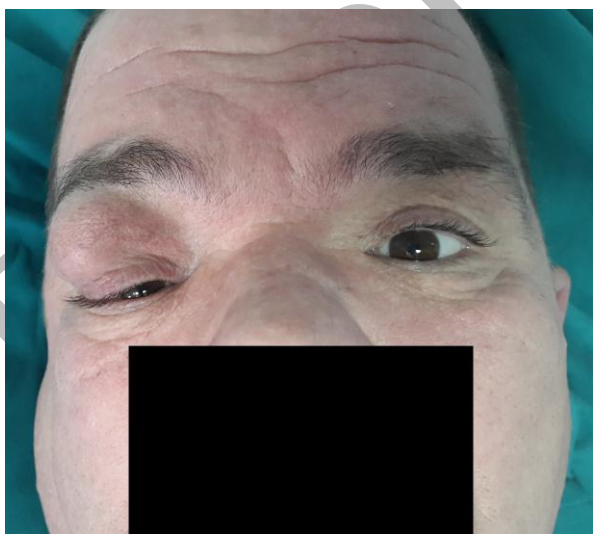

**Figure 1.** Temporal sinus mucocele with endocranial and intraorbital propagation. The presence of exophthalmos accompanied by inferior dislocation of bulbus with no defects in the visual field.

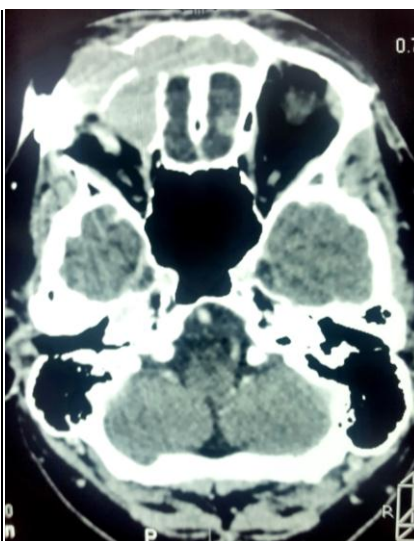


**Figure 2.** Hypodense formation in the left frontal sinus and left orbit. Process extension present frontobasally and toward the left orbit.

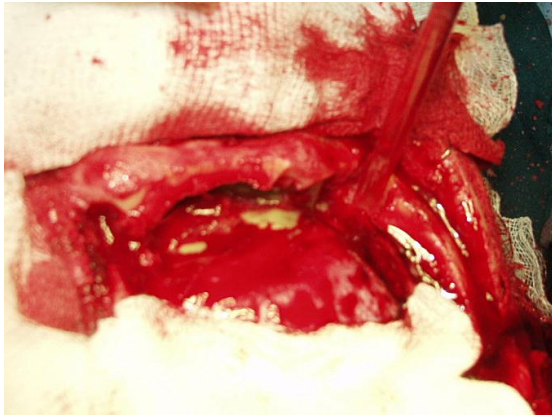
In 3 out of 7 cases, the process extension toward the orbit was present along with the mentioned ophthalmological disorders (Figures 3, 4). The occurrence of diplopia was observed in 2 cases.



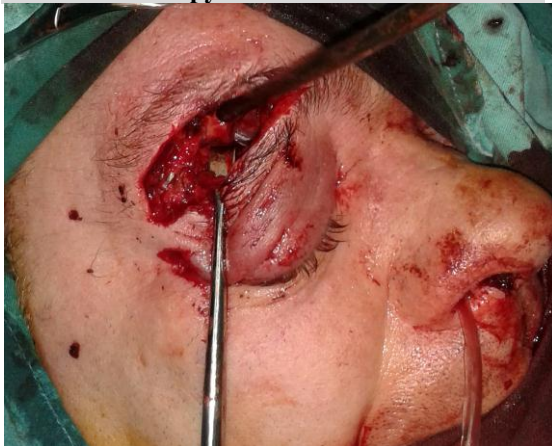**Figure 3.** Frontal sinus mucocele with intraorbital extension. The presence of enophthalmos, inferior dislocation of bulbus without diplopia and defects in the visual field area.



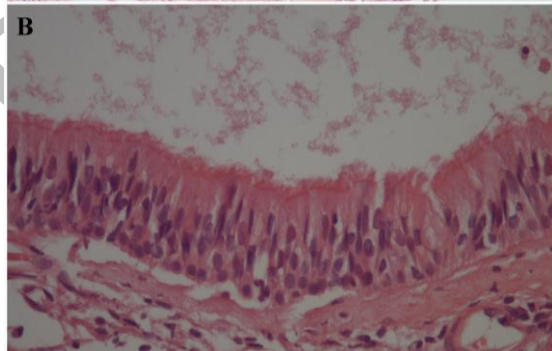
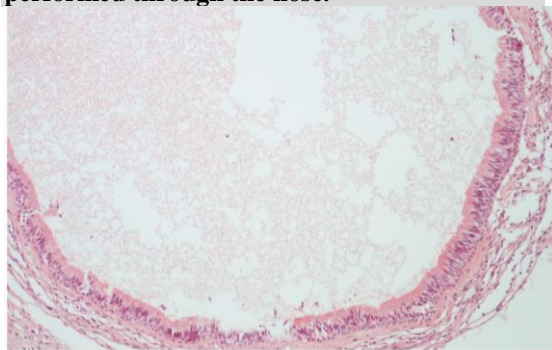
**Figure 4.** Hypodense formation in the right frontal sinus with signs of the sinus floor destruction and penetration into the right orbit



**Figure 5. Post bifrontal craniotomy condition. Mucopyocele in the left frontal sinus.**



**Figure 6. Post frontal sinus mucocele and orbit extirpation condition. Drainage performed through the nose.**



**Figure 7. Cyst showing pseudostratified columnar ciliated epithelium containing mucous cells (H&E; A:  $\times 4$ ; B:  $\times 20$ )**

In 4 out of 7 patients, bifrontal craniotomy was performed after the bicorony approach due to possible exploration of the anterior cranial fossa, frontal sinuses and orbits. The tumor formation was completely separated from the dura, periorbital tissue and orbit content. Bone defects in the area of the frontal sinus posterior wall, orbit roof and upper third of the medial orbit wall. The posterior sinus wall was reconstructed with biosynthetic material palakost, placed between the dura of the posterior sinus wall. Bone defects in the orbit roof and medial wall area were reconstructed with free bone transplants from calvaria and titanium meat. Dura defects were reconstructed with fascia lata (Figure 5). A pericranial flap characterized by good vascularization, appropriate voluminosity and minimal morbidity of the donor site was placed on the sinus floor over the nasofrontal opening in order to separate the sinus from the nasal cavity and thus prevent infection.

In 3 out of 7 patients, the transfacial approach according to Lynch-Howarth was used, with the extension toward the lateral border of the supraciliary region. The mucocele tissue was separated from the periorbital tissue, with lacrimal glands and oculogyric muscles preserved. The average size of the orbit roof and frontal sinus floor defects was 2x1 cm. The existing bone defect in all cases was reconstructed with titanium meat. Moreover, in all patients, a silastic tube was placed endonasally to keep the sinus duct passable, and then removed after 6 weeks (Figure 6).

Histologically, lesion characterized by dilated epithelium lined ducts filled with mucin, often associated with extravasation of mucin into the stroma. Cysts lined by flat or low cuboidal epithelium (Figure 7).

The appearance of major postoperative complications was not recorded. In 2 out of 3 patients treated with transfacial approaches, postoperative epistaxis was noted and stopped using frontal nose tamponade.

Recurrence was observed in 1 out of 3 cases treated with the transfacial approach. After a performed reintervention and a three-year long monitoring of patients, recurrence was not recorded. Recurrence in patients treated with the transcranial approach was not recorded.

There were no cases of endonasal spreading of the frontal sinus mucocele in the study.

## DISCUSSION

Mucoceles are most often located in the frontal sinus (60 – 89%), ethmoid sinus (16%), whereas they are extremely rare in the maxillary (3%) and sphenoidal (1%) sinus [7]. This conclusion is supported by the fact that the frontal sinus excretory duct is 15-20 cm long, and 1-2 mm wide, often with the uneven lumen. A greater frequency is in men. The highest incidence is among the population between 55 and 65 years of age [8].

The etiology of frontal sinus mucoceles is multifactorial and still has not been clarified in detail. Pathological entities whose presence may lead to disorders of drainage through the nasofrontal duct represent a dominant factor in their occurrence. Most often, they include chronic sinusitis, allergic reactions on the level of sinus mucosa, injuries, anatomic sinus and excretory duct anomalies, tumors, etc.

In a retrospective study which included 72 patients with mucoceles in paranasal cavities, Obeso et al. determined that 35% of their examinees stated they had underwent previous surgical interventions on the sinuses, thus indicating a possible iatrogenic cause of their occurrence [9].

The most common mechanism of bone destruction of sinus walls is a continuous pressure which leads to bone ischemia, necrosis and resorption. The obstruction of the sinus excretory duct and a consequent infection result in the accumulation of lymphocytes and neutrophils which, by creating cytokine molecules, lead to enzymatic osteolysis of sinus walls [10]. It has been determined that the fibroblasts from paranasal cavities with existing signs of an infection create greater amounts of prostaglandin E2 and collagenases, compared to the mucosal fibroblasts with physiological characteristics that have a key role in increased osteolysis processes of sinus walls and a consequent mucocele expansion [11].

Bacteriological findings of mucoceles are negative in most cases. In cases of a present infection, the presence of *Staphylococcus aureus*, *Haemophilus* species and gram-negative bacilli types was determined. Dominant anaerobic bacilli include *Propionibacterium acnes*, *Peptostreptococcus*, *Prevotella* and *Fusobacterium* species [12].

The diagnostics of mucoceles includes a detailed anamnesis, clinical examination and the use of additional radiological methods, computed tomography (CT) and magnetic resonance imaging (MRI) above all. CT with contrast is the most reliable and most used method for the determination of the

bone destruction rate, whereas MRI is used for complicated cases with intracranial process spreading or a present infection due to its ability to precisely determine the contact of a mucocele with the brain parenchyma and orbit content [13]. CT findings are characterized by the appearance of the so-called jagged bone, formed as a consequence of alternating bone remodeling processes.

Bulbus proptosis, 85% of cases, is a pathognomonic sign of mucocele spreading toward the orbit [14]. The spreading of the process from the direction of the sinuses leads to anterior dislocation of the bulbus, while processes from the ethmoidal sinus lead to lateral dislocation.

Dermoid cysts, histiocytosis, tuberculosis, fungal infections, fronto-orbital cholesterol granulomatosis, secondary deposits, orbit and sinus tumors represent pathological entities which are included in the differential analysis of frontal sinus mucoceles [15].

The treatment of frontal sinus mucoceles is surgical, with the aim to establish the anatomical and functional integrity of sinuses. Depending on the size of the process and the engagement of surrounding anatomic structures, the extensity of a surgical intervention ranges from a minimal invasive endoscopic surgery to craniotomy with or without sinus obliteration [16].

Inability to completely remove mucoceles and establish patency of the nasolacrimal duct, as well as the extension of the process toward the orbit or brain parenchyma, represent indicators for open approaches [17].

The aim of a surgical treatment is to entirely remove changes along with the repair of intraorbital and intracranial complications, form drainage into the nose through the nasofrontal duct or to remove the whole mucosa with duct and sinus obturation. In case of posterior sinus wall erosion and dura involvement, the bicorony approach, radical mucocele removal, cranialization and obturation of the nasofrontal duct are indicated [18]. Transfacial approaches are indicated in case of the process extension toward the orbit and nose with crucial preservation of posterior sinus wall continuity [19].

The advantages of transfacial and transcranial approaches compared to endoscopic approaches are reflected in the possibility to explore the whole sinus, prevent blind curettage and possible dura damage, create adequate space for possible sinus obliteration, and prevent recurrence.

The prognosis of frontal sinus mucoceles is usually good, with an extremely low recurrence rate (10%) [20]. Regardless of the previous statement, a long-term monitoring of patients after surgical treatments is recommended.

## CONCLUSION

The specificity of the anatomic region represents one of the reasons for the spreading of mucoceles toward the orbit, nasal cavity and anterior cranial fossa, as well as for the occurrence of symptoms due to which patients initially consult doctors.

The treatment of frontal sinus mucoceles is always surgical. Endoscopic surgery and marsupialization of a change are an indicator for smaller, early-diagnosed mucoceles. Transcranial

and transfacial approaches stand for treatment methods for advanced mucoceles with a present intraorbital, intracranial and endonasal process propagation.

## REFERENCES

1. Alberti PW, Marshall HF, Black JI. Fronto-ethmoidal mucocele as a cause of unilateral proptosis. *Br J Ophthalmol*. 1968; 52: 833–8.
2. Pierse J, Stern A. Benign cysts and tumors of the paranasal sinuses. *Oral Maxillofac Surg Clin North Am*. 2012; 24: 249–64.
3. Meer S, Altini M. Cysts and pseudocysts of the maxillary antrum revisited. *SADJ*. 2006; 61:10–3.
4. Hayasaka S, Shibasaki H, Sekimoto M, Setogawa T, Wakutani T. Ophthalmic complications in patients with paranasal sinus mucopyoceles. *Ophthalmologica*. 1991; 203: 57–63.
5. Mourouzis C, Evans B, Shenouda E. Late presentation of a mucocele of the frontal sinus: 50 Years postinjury. *J Oral Maxillofac Surg*. 2008; 66: 1510–3.
6. Weitzel EK, Hollier LH, Calzada G, Manolidis S. Single stage management of complex fronto-orbital mucoceles. *J Craniofac Surg*. 2002; 13: 739–45.
7. Pilch ZB. *Head and neck surgical pathology*, 1st edition. London:Lippincott Williams & Wilkins; 2000.
8. Arrué P, Kany MT, Serrano E, Lacroix F, Percodani J, Yardeni E, et al. Mucoceles of the paranasal sinuses: Uncommon location. *J Laryngol Otol*. 1998; 112: 840–4.
9. Obeso S, Llorente JL, Pablo Rodrigo J, Sánchez R, Mancebo G, Suárez C. Paranasal sinuses mucoceles: Our experience in 72 patients. *Acta Otorrinolaringol Esp*. 2009; 60: 332–9.
10. Lund VJ, Milroy CM. Fronto-ethmoidal mucoceles: A histopathological analysis. *J Laryngol Otol*. 1991; 105: 921–3.
11. Lund VJ, Harvey W, Meghji S, Harris M. Prostaglandin synthesis in the pathogenesis of fronto-ethmoidal mucoceles. *Acta Otolaryngol*. 1988; 106: 145–51.
12. Brook I, Frazier EH. The microbiology of mucopyocele. *Laryngoscope*. 2001; 111: 1771–3.
13. Gavioli C, Grasso DL, Carinci F, Amoroso C, Pastore A. Mucoceles of the frontal sinus. Clinical and therapeutical considerations. *Minerva Stomatol*. 2002; 51: 385–90.
14. Edelman RR, Hesselink JR, Zlatkin MB, Cruess JV. *Clinical Magnetic Resonance Imaging*, 3rd edition. Philadelphia: Elsevier; 2006. p. 2035–7.
15. Tan CS, Yong VK, Yip LW, Amrith S. An unusual presentation of a giant frontal sinus mucocele manifesting with a subcutaneous forehead mass. *Ann Acad Med Singapore*. 2005; 34: 397–8.
16. Constantinidis J, Steinhart H, Schwerdtfeger K, Zenk J, Iro H. Therapy of invasive mucoceles of the frontal sinus. *Rhinology*. 2001; 39: 33–8.
17. Park CM, Stoffella E, Gile J, Roberts J, Herford AS. Osteoplasty flap technique for repair of latent (30-year) post-traumatic frontal sinus mucocele: Case report and review of the literature. *J Oral Maxillofac Surg*. 2012; 70: 2092–6.
18. Suri A, Mahapatra AK, Gaikwad S, Sarkar C. Giant mucoceles of the frontal sinus: series and review. *J Clin Neurosci*. 2004; 11: 214–18.
19. Sama A, McClelland L, Constable J. Frontal sinus mucoceles: New algorithm for surgical management. *Rhinology*. 2014; 52: 267–75.
20. Weitzel EK, Hollier LH, Calzada G, Manolidis S. Single stage management of complex fronto-orbital mucoceles. *J Craniofac Surg*. 2002; 13: 739–45.