



Paper Accepted*

ISSN Online 2406-0895

Case Report / Приказ болесника

Anđelka Stojković^{1,2†}, Dragan Milovanović^{1,3}, Stevan Stojanović^{1,4}, Katerina Dajić¹, Zlatan Elek⁵, Maја Vulović⁶, Aleksandra Simović^{1,2}

The treatment of hemangioma of the larynx in children is still a dilemma

Лечење хемангиома ларингса у деце је још увек дилема

¹University of Kragujevac, Faculty of Medical Sciences, Department of Paediatrics, Kragujevac, Serbia;

²Clinical Centre of Kragujevac, Pediatric Clinic, Kragujevac, Serbia;

³Clinical Centre of Kragujevac, Department of Clinical Pharmacology, Kragujevac, Serbia;

⁴Clinical Centre of Kragujevac, Clinic for Otorhinolaryngology, Kragujevac, Serbia;

⁵Clinical Hospital Center, Department of Child Surgery, Kosovska Mitrovica, Serbia;

⁶University of Kragujevac, Faculty of Medical Sciences, Department of Anatomy, Kragujevac, Serbia

Received: February 9, 2018

Revised: August 20, 2018

Accepted: September 21, 2018

Online First: October 11, 2018

DOI: <https://doi.org/10.2298/SARH180209059S>

* **Accepted papers** are articles in press that have gone through due peer review process and have been accepted for publication by the Editorial Board of the *Serbian Archives of Medicine*. They have not yet been copy edited and/or formatted in the publication house style, and the text may be changed before the final publication.

Although accepted papers do not yet have all the accompanying bibliographic details available, they can already be cited using the year of online publication and the DOI, as follows: the author's last name and initial of the first name, article title, journal title, online first publication month and year, and the DOI; e.g.: Petrović P, Jovanović J. The title of the article. *Srp Arh Celok Lek*. Online First, February 2017.

When the final article is assigned to volumes/issues of the journal, the Article in Press version will be removed and the final version will appear in the associated published volumes/issues of the journal.

The date the article was made available online first will be carried over.

† **Correspondence to:**

Anđelka STOJKOVIĆ

University of Kragujevac, Faculty of Medical Sciences, Kragujevac Clinical Centre, Paediatric Clinic, Zmaj

Jovina 30, 34000 Kragujevac, Serbia

Email: andja410@mts.rs

The treatment of hemangioma of the larynx in children is still a dilemma

Лечење хемангиома ларинкса у деце је још увек дилема

SUMMARY

Introduction The juvenile laryngeal hemangioma is benign vascular neoplasm but with malignant localization.

Case outline After two weeks of corticosteroid treatment in a 15-month-old boy, the desired results were not achieved. This case report is a small contribution to the research of targeted propranolol treatment in juvenile laryngeal hemangioma and the role of epinephrine in the initial treatment in life threatening conditions.

Conclusion When laryngeal hemangioma has "bad" localization and any surgical treatment is denied in spite of the vital risk, the choice of treatment is epinephrine (first) and propranolol.

Keywords: laryngeal disease; neoplasm; vascular tissue; child

САЖЕТАК

Увод Хемангиом ларинкса у деце је бенигна васкуларна неоплазма али по локализацији малигна.

Приказ болесника У току 2 недеље кортикостероидне терапије није било жељеног ефекта у дечака старог 15 месеци. Овај приказ случаја је мали допринос истраживању о хемангиому у деце и циљаној терапији пропранололом. Поред овога, расветлили смо улогу епинефрина у иницијалној терапији хемангиома ларинкса у животно угрожене деце.

Закључак Када хемангиом има "лошу" локализацију и није индиковано хируршко лечење упркос виталном ризику, терапија избора су епинефрин (први избор) и пропранолол.

Кључне речи: обољење гркљана; неоплазма; васкуларно ткиво; дете

INTRODUCTION

The hemangioma of the larynx in children is rare benign vascular neoplasm, which by its localization may have malign clinical course. Last year the American Academy of Pediatrics (AAP) [1] has made recommendations for the treatment of infantile hemangioma while calling for additional research of the treatment of hemangioma in airways in young children.

CASE REPORT

We have rarely diagnosed hemangioma of the larynx in a male child aged 15 months especially if there is no accompanying hemangioma of the skin [2]. We can be even more confused by normal findings of fiber-laryngoscopy. However, the pediatricians must treat the child until fiber-bronchoscopy is performed. The question is which drug to use and which drug may contribute to a successful differential diagnosis of the mentioned condition in primary health care and before fiber-bronchoscopy is done, and whether the AAP recommendations are absolutely relevant [1]?

A brief description of the clinical course of hemangioma of the larynx in a boy will be the basis for monitoring the treatment course and making conclusions. Before the admission at the Pediatric Clinic the 15-month-old boy had cough, breathing difficulty and a fever of 38.6°C, which was treated by nebulized bronchodilator FIB (fenoterol + ipratropium bromide) and a steroid (Table

1). At the admission, the boy had signs of respiratory insufficiency. The majority of biochemical, hematological and microbiological analyses (Table 2) were within border references for child's age [3]. At BF chest X-ray in the projection of the larynx a hyperdense zone could be seen (Figure 1), asymmetrical, with successive extensions first to the left then to the right, followed with air bronchogram and the strip-blotchy shadows in the lung parenchyma on both sides. X-ray of the trachea in two directions and contrast x-ray of the esophagus did not present abnormal findings.

After 3 days of therapy (Table 1) a pediatrician considered that the laryngitis was getting better and did not need further epinephrine inhalation. But, about 8 hours after epinephrine was excluded there was a deterioration. Fiberoptic bronchoscopy was performed (Table 1), as well as multidetector computed tomography (MDCT) (Figure 2). MDCT at the level of cervical vertebral body 2-3, on left airway wall, discovered thickening and hypodense, polypoid change which, asymmetrically, narrowed the lumen of the border between larynx and trachea to a minimum diameter of the less than 2 mm. After that, propranolol was introduced in the therapy and oxygen therapy was no longer needed after 4 days. After 10 days of propranolol treatment, fiber-bronchoscopy was repeated revealing a significant reduction in tumor tissue and the appearance of sufficient breathing space (Table 1). The child was discharged home with the same dose of propranolol (total 6 weeks), which resulted in cure.

DISCUSSION

In a 15-month-old boy with hemangioma of the larynx there was a good therapeutic response after administration of epinephrine and propranolol. There was no improvement of respiratory failure after the administration of corticosteroids (systemic nor inhaled), which is in many textbooks of pediatrics placed as the first therapeutic option for laryngeal hemangioma [2]. There was not the desired therapeutic response after the administration of a bronchodilator (beta-2-agonists, theophylline), or a broad-spectrum antibiotics (cephalosporins 3rd generation, macrolides). Epinephrine treatment in inhalation for 3 days resulted in a clinical improvement. Epinephrine therapy was discontinued because no therapeutic protocol in pediatrics recommends the use of a multi-day inhalation of this drug [2].

Epinephrine causes vasoconstriction of arterioles and the dilatation of airway smooth muscle that in a short period of a few hours can impose beneficial effects on blood vessels in the hemangioma, and the dilatation of the larynx. However, systemic and daily use of epinephrine for 7 days [4], causes ischemic effect on the soft tissues, which is a powerful stimulus for neovascularization [4, 5]. This effect is not desirable in the treatment of hemangioma of the larynx,

which leads us to think that epinephrine should be administered in a very short period of time, i.e. until a clinical improvement of respiratory insufficiency. At the same time, the speed of therapeutic response to epinephrine helped us in the differential diagnosis of inspiratory stridor and a hoarse cough. The duration of epinephrine administration is not defined in the recommendations of the AAP, so future research is needed [1].

The peripheral effects of propranolol are used to "shrink" a hemangioma and to prevent the differentiation of infantile hemangioma stem cells to endothelial cells and pericytes [1, 6]. The recommendation is that the initial dose of propranolol *per os* for the hemangioma of larynx would be as well as for skin hemangioma, 1-3.4 mg/kg/d with a gradual reduction in the dose during 3-12 months, i.e. until the child reaches the age at which a spontaneous resolution of infantile hemangioma (8-12 months of age) occurs [1, 2]. However, we have applied to the patient a dose of propranolol 2 mg/kg/d, continuously only 6 weeks and achieved a complete resolution of hemangioma of the larynx without side effects (drowsiness, hypoglycemia).

Despite official recommendations [1, 2] concerning the effective application of steroids in the treatment of infantile hemangioma of larynx, our experience was not positive (Table 1). Only after adding propranolol for 4 days the need for oxygen was eliminated and the child clinically recovered. During 6 weeks of treatment, systemic steroid was not administered simultaneously with propranolol, which is contrary to the recommendations, but it turned out to be the right and successful therapeutic approach [1, 2]. In life-threatening situations, with progressive deterioration of respiratory insufficiency of the child, parents and pediatricians do not have the patience to wait for prolonged effect of corticosteroids [1], which is achieved in the course of 4-12 weeks [1, 2], but insist on swift and targeted therapy of laryngeal hemangioma that is achieved by propranolol. Bearing in mind the so-called "bad" localization of hemangioma in the larynx, the classic surgical removal of hemangioma and/or the epinephrine application locally in hemangioma were not possible in this infant.

We wish to note attitudes from other pediatric institutions. The recommendation of a colleague from the Children's Hospital of Philadelphia [7] does not imply epinephrine but is based exclusively on the effects of propranolol, corticosteroids (intralesional), microdebrider excision, laser and surgical therapy - which implies certain risks. American authors published a therapeutic recommendation related to therapeutic options for infantile hemangioma on MedScape, with the exception of the above noted, and the interferon alfa-2b and a biologic immune response modifier, but not epinephrine [8]. French authors put propranolol in the first place in the treatment of infantile laryngotracheal hemangioma, with suspicion, in conclusion, about unsuccessful treatment of this type of hemangioma with propranolol [9].

After 2 years of treatment of hemangioma of the larynx, a boy, now 4 years of age, does not exhibit a stridor, but only wheezing as part of the clinical picture of asthma in a child under the age of 5 years. We shall continue to follow this child.

In conclusion, we suggest the first place of epinephrine in the therapeutic choice for the hemangioma of the larynx in children. The treatment of choice for hemangioma of the larynx was propranolol and that was for a shorter period of time than current pediatric recommendations suggest. The epinephrine and propranolol may be the treatment of choice when the surgical treatment is not indicated because of life's risky localization of hemangioma.

Paper accepted

REFERENCES

1. Darrow DH, Greene AK, Mancini AJ, Nopper AJ. Diagnosis and Management of Infantile Hemangioma. *Pediatrics*. 2015; 136(4):e1060–104. doi: 10.1542/peds.2015-2485.
2. Schroeder JW, Holinger LD. Congenital Anomalies of the Larynx, Trachea, and Bronchi. In: Kliegman MR, Stanton FB, St Geme WJ, Schor FN, Behrman ER. *Nelson textbook of pediatrics*, twentieth edition. Elsevier, 2016; 2036–2039. e3. DDC 618.92/0075–dc23 LC; ISBN 978-0-323-39956-2
3. Stanley LF. Reference intervals for laboratory tests and procedures. In: Kliegman MR, Stanton FB, St Geme WJ, Schor FN, Behrman ER. *Nelson textbook of pediatrics*, twentieth edition. Elsevier, 2016; 3464–73. DDC 618.92/0075–dc23 LC; ISBN 978-0-323-39956-2
4. Karacaoğlu, E, Çermik, H, Yurdun, T, Zienowicz, R. J. Effect of long-term application of epinephrine on rat skin vasculature: Experimental study. *Microsurgery* 2002; 22:288–94. DOI: 10.1002/micr.10055
5. Masiha H, Nikpour HA, Hasani ME, Emami A, Jafari M, Manafi A. The synergistic effect of bleomycin, triamcinolone and epinephrine in treatment of hemangioma and arteriovenous malformations. *World J Plast Surg*. 2012; 1(2):83–90. PMID: 25734049
6. Pan WK, Li P, Guo ZT, Huang Q, Gao Y. Propranolol induces regression of hemangioma cells via the down-regulation of the PI3K/Akt/eNOS/VEGF pathway. *Pediatr Blood Cancer*. 2015; 62(8):1414–20. DOI: 10.1002/pbc.25453
7. Jacobs NI, Javia RL, Sobol ES, Zur BK. Subglottic Hemangiomas. 2018 The Children's Hospital of Philadelphia. Center for pediatric airway disorders. Buerger center for advanced pediatric care. Available at <http://www.chop.edu/conditions-diseases/subglottic-hemangiomas>
8. Antaya JR, James DW, Wells JM, Perry V, Ortonne JP. Infantile Hemangioma Medication. *Medscape Medical News*. Available at <http://www.emedicine.medscape.com/article/1083849-medication#showall> Updated: Oct 02, 2017.
9. Denoyelle F, Leboulanger N, Enjolras O, Harris R, Roger G, Garabedian EN. Role of Propranolol in the therapeutic strategy of infantile laryngotracheal hemangioma. *Int J Pediatr Otorhinolaryngol*. 2009 Aug; 73(8):1168–72. doi: 10.1016/j.ijporl.2009.04.025.

Table 1. The clinical course and treatment of hemangioma of the larynx in a boy with body weight of 9.5 kg

Level of health care	Primary care				Pediatric Clinic							Institute for Mother and Child Healthcare					
Day of treatment	1	2	3	4	5	6	7	8	9	10	11	12	13	14	15	16	17 con
Some clinical features and additional diagnostic findings per days	<p>1.d: cough, breathing difficulty, fever 38,6oC</p> <p>2-3.d: cough, breathing difficulty</p> <p>4.d: more powerful cough, hoarse, fever 38,8oC</p>				<p>5.d: cough, dyspnoea, inspiratory stridor, pallor of skin and visible mucous membranes, fluttering nostrils, SaO₂ 89%-96% (according to the phase of the respiratory cycle and waking/sleeping child), RR 36 / min, HR 150/min.</p> <p>- Apart from hyperglycemia (8.1 mmol/l), other biochemical, haematological and microbiological analyses were within border references for child's age [3].</p> <p>-BF chest X-ray: in the projection of the larynx a hyperdense zone could be seen, asymmetrical, with successive extensions first to the left then to the right, followed with air bronchogram and the strip-blotchy shadows in the lung parenchyma on both sides.</p> <p>8.d: improvement, then 8h after epinephrine was excluded there was a deterioration - hard wheezing, alertness of the child, RR 56/min, SaO₂ less 91% (irrespective of the phase of the respiratory cycle).</p> <p>9.d: biphasic stridor, SaO₂ less 89%, RR</p>							<p>12.d: Respiratory failure and inspiratory stridor continued to worsen</p> <p>-Fiberoptic bronchoscopy: revealed a cystic tumor covered with normal mucous membrane color, capillary with a strong drawing, located under false vocal cords on both sides more to the right, where it occupied the entire space between the anterior and posterior commissure, and left behind the last commissure with a tumor on the right almost completely obstructing aditus of larynx, leaving a breathing crack in the back commissure - which corresponds to the findings of hemangioma of the larynx.</p> <p>-MDCT scanners neck and chest(native and with i.v. application of contrast medium): precisely determined the level of localization of lesions in C2-3 vertebral body, on the left wall, in the form of thickening and polypoid hypodense change which narrowed asymmetrically the lumen of the larynx to the smallest diameter of about 2mm.</p>					

	28/min, HR 90/min -X-ray of the trachea in two directions and contrast x-ray of the esophagus did not present abnormal findings.										17.d: discharged home							
Drugs:																		
Oxygen	continuously																	
FIB,sol. (ml), nebulized	0.2/12h									0.2/6h	0.2/6h	0.2/6h						
Salbutamol, sir.(ml), p.o		2.5/8h	2.5/8h	2.5/8h														
Epinephrin 1:10000 (+Panthenol +Saline) (mg/kg/dosis) nebulized					0.1/4h	0.1/4h	0.1/4h											
Aminophylline, i.v. (mg/kg/8h)											3							
Salbutamol, sol. (mg) nebulized											0.2/4h							
Ipratropium bromid, sol. for inhalation (µ/kg)											5/4h							
Magnesium sulfate, i.v. (mg/kg)											50/6h							
Budesonid (µ/12h), nebulized	250	250	250	250	500	500	250	500	500	500	500	500	500	500	500	500		
Dexamethason i.v. (mg/dosis/d divided in 2 doses)					8	8												
Methylprednisolone i.v. (mg/kg/d divided in 3 doses)									3	3	3	3	3	3	3	3	3	

antibiotics	Azithromycin, p.o								
	Ceftriaxone, i.v.			Ceftriaxone, i.v.					
		Clarithromycin, p.o							
Propranolol (mg/kg/d) divided in 2 doses, p.o.				2	2	2	2	2	con

FIB – fenoterol + ipratropium bromid; p.o. – orally; SaO₂ – percutaneous oxygen saturation; RR – respiratory rate; HR – heart rate; BF – back-front; MDCT – multiple detector computed tomography; C – cervical; ORL – otorhinolaryngologist; i.v. – intravenous; con – continued; □ – interrupted

Paper accepted

Table 2. The 15-month-old boy: the laboratory findings at admission in Pediatric Clinic [2]

Gas analysis by Astrup from venous blood: pH 7.34, pO₂ 5.7kPa, pCO₂ 5.9kPa, sodium ionized 138 mmol/l, potassium ionized 4.3 mmol/l, calcium ionized 1.14 mmol/l, bicarbonate 24 mmol/l, base excess -2 mmol/l
Sedimentation rate 10, C-reactive protein 9.9 mg/l Complete blood count: WBC 5.1x10⁹/l, neutrophils 0.53, lymphocyte 0.43, monocytes 0.05, PLT 267x10⁹/l, RBC 4.64x10¹²/l, Hb 117g/l, Hct 36%
Urinalysis - normal
Glycemia 8.1 mmol/l, magnesium 1 mmol/l, aspartate aminotransferase 42 U/l, alanine aminotransferase 17 U/l, urea nitrogen 4.6 mmol/l, creatinine enzymatic 46 µmol/l
Immunoglobulin (Ig) E 5.2 kIU/l, Vitamin D 25 ng/ml
Smear pharynx and nose, and aspirate - normal flora, IgM-mycoplasma pneumoniae - negative titer

WBC – white blood cells; RBC – red blood cells; PLT – platelets

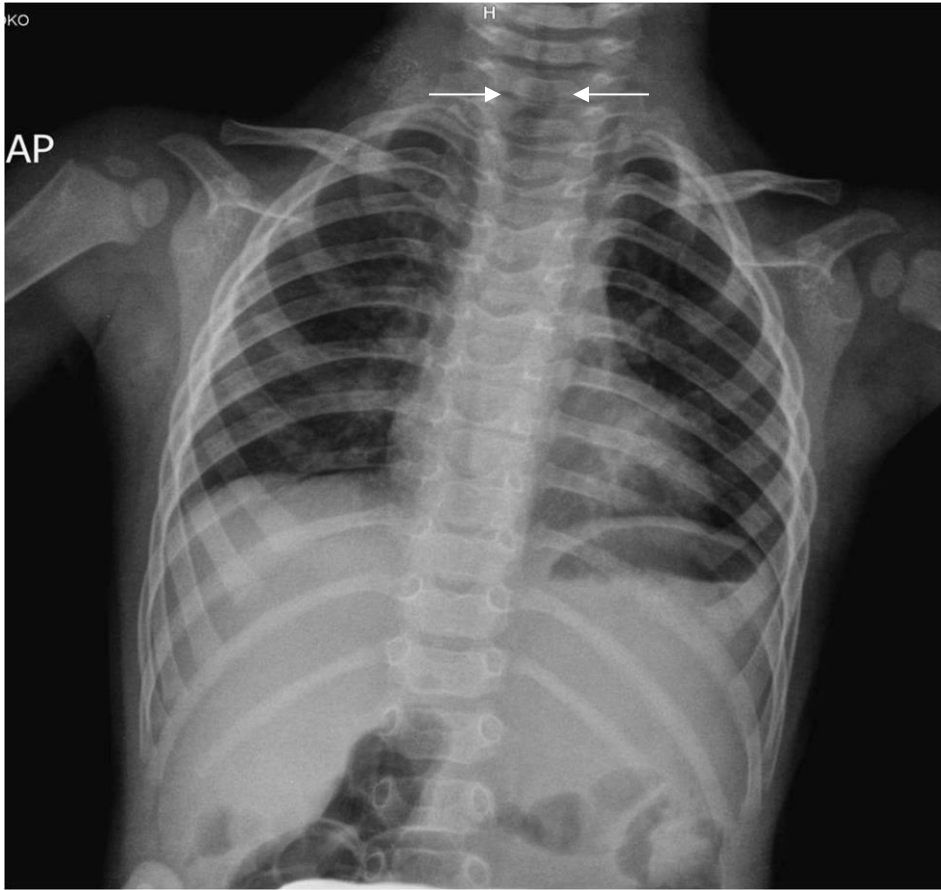


Figure 1. The 15-month-old boy (on admission): the chest x-ray in the posterior-anterior position

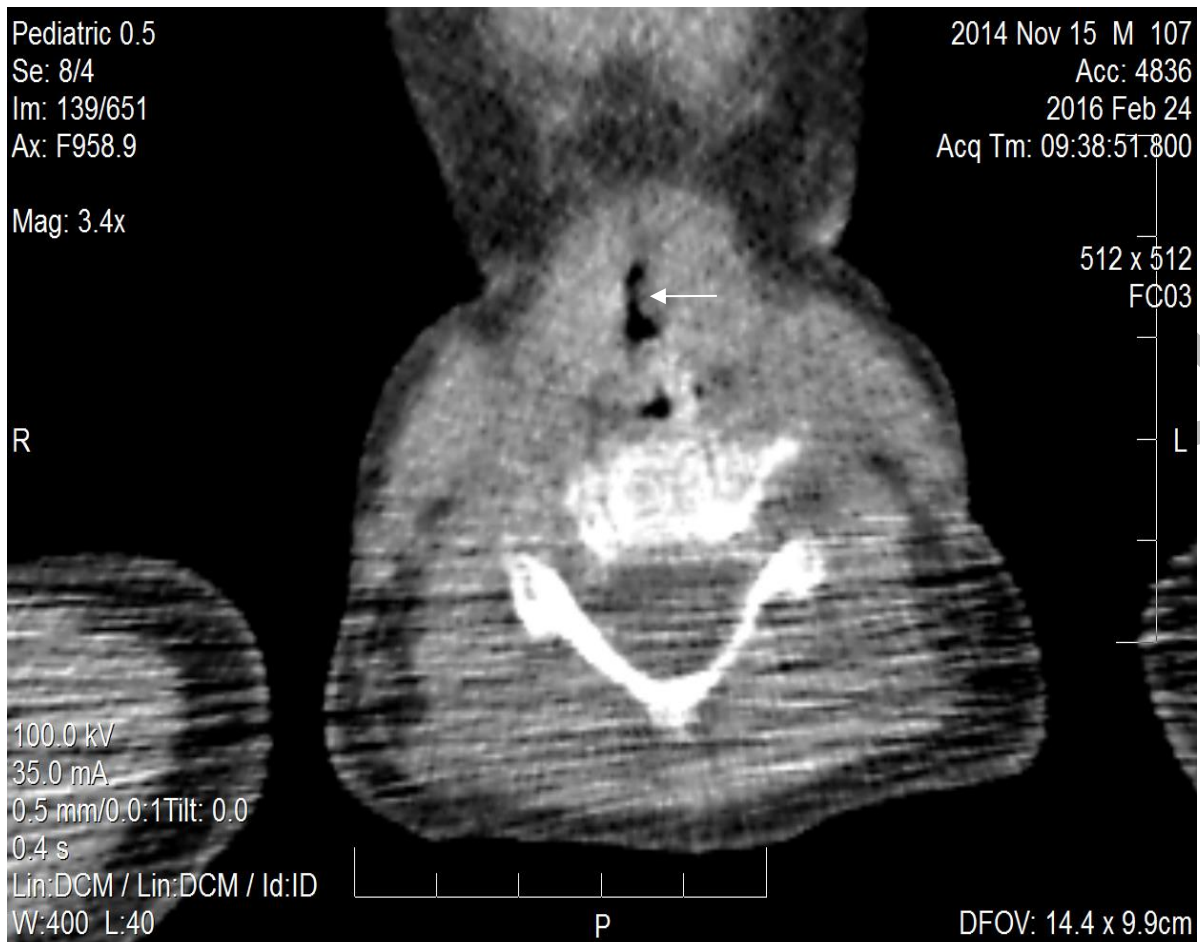


Figure 2. The 15-month-old boy (4th hospitalization day): MDCT at the level of C2-3 vertebral body, on the left airway wall (arrow), discovered thickening/hypodense/polypoid change which narrowed asymmetrically the lumen of the border larynx/trachea to the smallest diameter of 2 mm