



Paper Accepted*

ISSN Online 2406-0895

Case Report / Приказ болесника

Miroslav Ilić^{1,2†}, Srđan S. Putnik³

**Laparoscopic sleeve gastrectomy in a super obese patient
with restenosis of trachea**

Лапароскопска рукавна гастректомија код супер гојазног пацијента
са рестенозом трахеје

¹Institute for Pulmonary Diseases of Vojvodina, Clinic for Thoracic Surgery, Sremska Kamenica, Serbia;

²University of Novi Sad, Faculty of Medicine, Novi Sad, Serbia;

³Vršac General Hospital, Department of General Surgery, Vršac, Serbia

Received: April 11, 2018

Accepted: July 20, 2018

Online First: August 7, 2018

DOI: <https://doi.org/10.2298/SARH180411052I>

* **Accepted papers** are articles in press that have gone through due peer review process and have been accepted for publication by the Editorial Board of the *Serbian Archives of Medicine*. They have not yet been copy edited and/or formatted in the publication house style, and the text may be changed before the final publication.

Although accepted papers do not yet have all the accompanying bibliographic details available, they can already be cited using the year of online publication and the DOI, as follows: the author's last name and initial of the first name, article title, journal title, online first publication month and year, and the DOI; e.g.: Petrović P, Jovanović J. The title of the article. *Srp Arh Celok Lek*. Online First, February 2017.

When the final article is assigned to volumes/issues of the journal, the Article in Press version will be removed and the final version will appear in the associated published volumes/issues of the journal. The date the article was made available online first will be carried over.

† **Correspondence to:**

Srđan S. PUTNIK

Vršac General Hospital, Department of General Surgery, Abraševićeva bb, 26300 Vršac, Serbia

Email: putniksrđjan@outlook.com

Laparoscopic sleeve gastrectomy in a super obese patient with restenosis of trachea

Лапароскопска рукавна гастректомија код супер гојазног пацијента са рестенозом трахеје

SUMMARY

Introduction Super obese group of patients with body mass index (BMI) $\geq 50 \text{ kg/m}^2$ have higher technical intraoperative problems, higher morbidity and mortality. Indications for the metabolic procedure are widening and minimally invasive operation dictate both patients and surgeons to face with previously assumed "general contraindication" for surgical bariatric/metabolic procedure.

Case outline We present a super obese patient with restenosis of the trachea, chronic obstructive pulmonary disease, sleep apnea and cardiomyopathy with panniculus grade IV, in whom as a multidisciplinary team we did simultaneously permanent tracheostomy, laparoscopic sleeve gastrectomy and panniculectomy.

Conclusion Quality of life after the bariatric operation is a factor which must be leading in concern how to approach a difficult patient, with operation adaptable to fit all demands.

Keywords: super obese, laparoscopic sleeve gastrectomy, bariatric surgery

САЖЕТАК

Увод Супер гојазна група пацијената са индексом телесне масе (БМИ) $\geq 50 \text{ kg/m}^2$ има веће техничке и нтраоперативне проблеме, већи морбидитет и морталитет. Индикације за метаболичке процедуре се повећавају и минимално инвазивне операције захтевају како пацијента тако и од хирурга да се суоче са претходно подразумеваним "општим контраиндикацијама" за хируршку баријатријску / метаболичку процедуру.

Приказ болесника Представљамо супергојазног пацијента са рестенозом трахеје, хроничном опструктивном болешћу плућа, опструктивним апнеја синдромом и кардиомиопатијом и паникулусом четвртог степена, ког кога је мултидисциплинарни тим урадио истовремено трајну трахеостомију, лапароскопску рукавну гастректомију и паникулектомију.

Закључак Квалитет живота након баријатријске операције је фактор који мора бити водећи у томе како приступити тешком пацијенту, са операцијом прилагођеном да одговара свим захтевима.

Кључне речи: супер гојазни, лапароскопска рукавна гастректомија, баријатријска хирургија

INTRODUCTION

In recent decades obesity become a significant worldwide health and surgical problem [1]. Super obese group of patients with body mass index (BMI) $\geq 50 \text{ kg/m}^2$ have higher technical intraoperative problems, more postoperative complications and higher mortality [2,3]. Indications for metabolic operation are widening and successful management of comorbidities after minimally invasive operation dictate both patients and surgeons to face with previously assumed "general contraindication" for surgical bariatric/metabolic procedure. Is it elective surgery justified in a selected group of patients who have several vital organs dysfunction?

We present a high risk super obese patient with chronic respiratory failure, cardiomyopathy and restenosis of previously resected trachea who came to the surgeon for removing panniculus (grade IV), refusing for surgery in non-referral surgical centers [4]. We did successful laparoscopic sleeve gastrectomy after re-tracheostomy with a synchronous panniculectomy.

CASE REPORT

A male Caucasian 54 years old, body weight 160 kg, high 175 cm, body mass index (BMI) 52.3 kg/m² (Figure 1A). Neck circumference was 49.5 cm. He complains of large panniculus and inspiratory stridor. In a tertiary institution, he was refused for panniculectomy operation due to restenosis of the upper trachea, respiratory chronic failure and chronic cardiomyopathy with ten years medically history of hypertension with arrhythmia. Previously (eleven years before), he had surgical repair of stenotic trachea after prolonged intubation due to the attempt of suicide with local pesticide poison (parathion containing) during the psychical paranoid episode (Figure 2). After recovery, he started to gain weight. At the admittance to Clinic, a patient is an active smoker and consume 15 cigarettes last 25 years.

At the University Clinic for Thoracic Surgery, Department for Esophageal and Laparoscopic Surgery, Sremska Kamenica, Serbia, we did multi-slice computed tomography (MSCT) of the neck, thorax, and tracheo-bronchoscopy. Preoperative MSCT showed restenosis of trachea on 12 mm beyond glottis. Endoscopic findings suggest restenosis immediately beneath vocal cords which appeared immobilized and showed disarrangement of the whole larynx. Respiratory function showed global respiratory insufficiency due to alveolar hypoventilation and chronic obstructive pulmonary disease. Cardiac function was estimated with echocardiogram (ejection fraction 65%) and dilatation of left atrium and hypertension were noted. Sleep apnea study was not done due to restenosis of trachea but previously he treated by ventilator support during the night. For last ten years, a patient lives without suicide ideas in a stable social relationship with wife and doing as an agriculture worker. After an explanation of multidisciplinary surgical and otorhinolaryngology team, a patient accepted reasonable risk and operation.

Operation begins with intraoperative direct and rigid laryngoscopy and temporary intubation with tracheal tube No 6. Excision of scar tissue was done and after identification of tracheal restenosis *in loco* of the subglottic-tracheal junction (Figure 3). Re-tracheostomy was made and cannula No 9. placed and fixed for further airway support for the procedure. Patient positioned in French position and laparoscopic sleeve gastrectomy was done with four trocar technique. After completing the laparoscopic procedure, panniculectomy was done in standard fashion (Figure 4). Postoperative period was uneventful and he spent 14 days in a hospital.

After 12 months patient has body weight 93 kg, BMI 30.4 Kg/m², %EWL (Percentage of excess weight loss) 71.4 (Figure 1B) . Patient-adapted to permanent metal tracheal cannula and speech routinely by pressure on cannula opening. He is very satisfied with the quality of life.

DISCUSSION

Super obese patient with BMI ≥ 50 kg/m² and neck circumference over 42 cm are considered as a patient fifty times more likely experience difficult intubation [5]. In our patient restenosis of previously resected trachea was a factor for refusing of anesthesia and any elective surgery in non-experienced centers. This patient had only hope in experienced centre specialized for tracheal surgery and obesity surgery. His primary health demand was removing of panniculus, but the explanation of multidisciplinary team was acceptance of simultaneous surgical tracheal, metabolic and plastic intervention. In every step, as a team, we considered stopping of intervention if any complication occurs.

Difficult intubation during operation for morbid obesity is the relatively uncommon situation, and require emergency tracheostomy in very few cases [6]. But the completely difficult situation is in a case with stenosis of the trachea as it was in our patient. Not the only anesthesiologist is in the problem, but unsolved restenosis of the trachea is permanent damage to his health, as well as morbid obesity with co-morbidities. That's why an otorhinolaryngologist was included in solving that problem with a permanent tracheostomy.

A question of his psychological status is also important for the future success of whole postoperative period. A patient was cooperative and with social life in the family and able to work. He reasonable asked a question about not only panniculectomy but also for reduction of weight. A question was what operation to choose. We decided to do a simple but effective operation, with later possible eventful recovery and operation will not dependent on continuous therapy of supplementation. Simultaneously, we did a panniculectomy because it was his first and main demand. Several authors suggest that panniculectomy should be operated after patients stabilize body weight, but there are some exceptions as in cases with panniculus grade IV and V [4,7]. Maybe there is a special indication in patients with tracheostomy and difficult approach to airways. The cosmetic result in our patients supports this thesis.

The result after one year regarding sleeve gastrectomy and weight loss is good. The patient was at regular intervals on surgical controls and his attitude was superior regarding the quality of life.

In the era of modern and team approach morbidly obese patients could be treated successfully even with serious comorbidities nondependent on obesity. Quality of life after the bariatric operation is a factor which must be leading in concern how to approach a difficult patient, with operation adaptable to fit all demands.

REFERENCES

1. Engin A. The Definition and Prevalence of Obesity and Metabolic Syndrome. *AdvExp Med Biol.* 2017; 960:1-17. [DOI:10.1007/978-3-319-48382-5_1] [PMID:28585193]
2. Parikh MS, Shen R, Weiner M, Siegel N, Ren CJ. Laparoscopic bariatric surgery in super-obese patients (BMI>50) is safe and effective: a review of 332 patients. *Obes Surg.* 2005; 15(6):858–863.[DOI:10.1381/0960892054222632][PMID:15978159]
3. Darrat I, Yaremchuk K. Early mortality rate of morbidly obese patients after tracheotomy. *Laryngoscope.* 2008; 118(12):2125-8.[DOI:10.1097/MLG.0b013e3181847a78] [PMID:19029859]
4. Igwe D Jr, Stanczyk M, Lee H, Felahy B, Tambi J, FobiMA. Panniculectomy adjuvant to obesity surgery. *Obes Surg.* 2000;10(6):530-9. [PMID:11175961]
5. Riad W, Vaez MN, Raveendran R, Tam AD, Quereshy FA, Chung F, et al. Neck circumference as a predictor of difficult intubation and difficult mask ventilation in morbidly obese patients: A prospective observational study. *Eur J Anaesthesiol.* 2016; 33(4):244-9. [DOI:10.1097/EJA.0000000000000324][PMID:26351829]
6. Baltasar A, Bou R, Bengochea M, Serra C, Pérez N. Emergency Tracheotomy in Morbid Obesity. *Austin Surg Case Rep.* 2017; 2(2): 1018.
7. Gurunluoglu R. Insurance coverage criteria for panniculectomy and redundant skin surgery after bariatric surgery: why and when to discuss. *Obes Surg.* 2009; 19(4):517-20. [DOI:10.1007/s11695-008-9752-z] [PMID:18958535]
- 8.

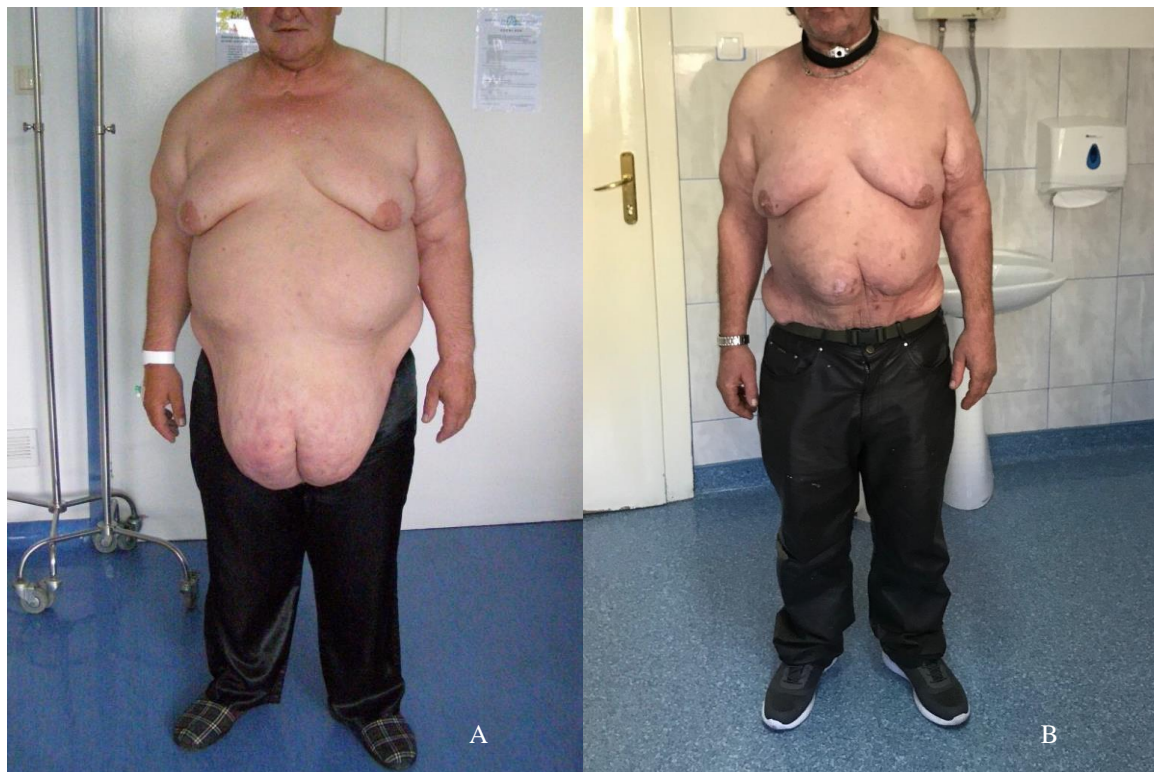

Figure 1. A super obese 54-year-old patient before the operation (A) and one year later (B)

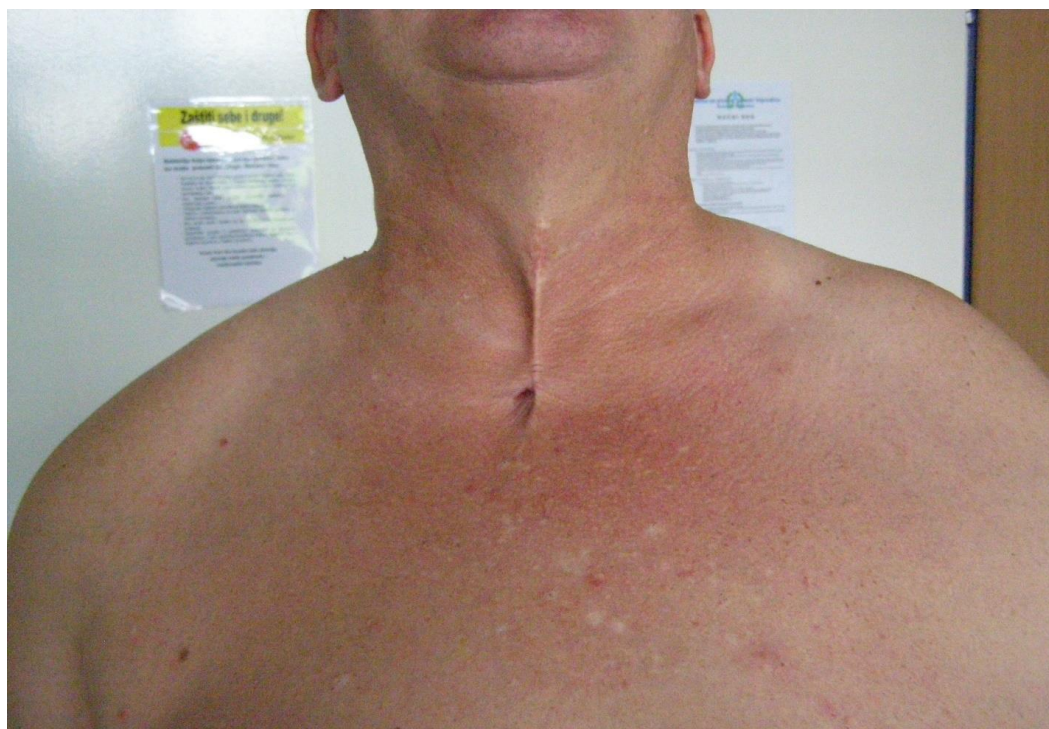

Figure 2. The scar from the previous tracheal operation

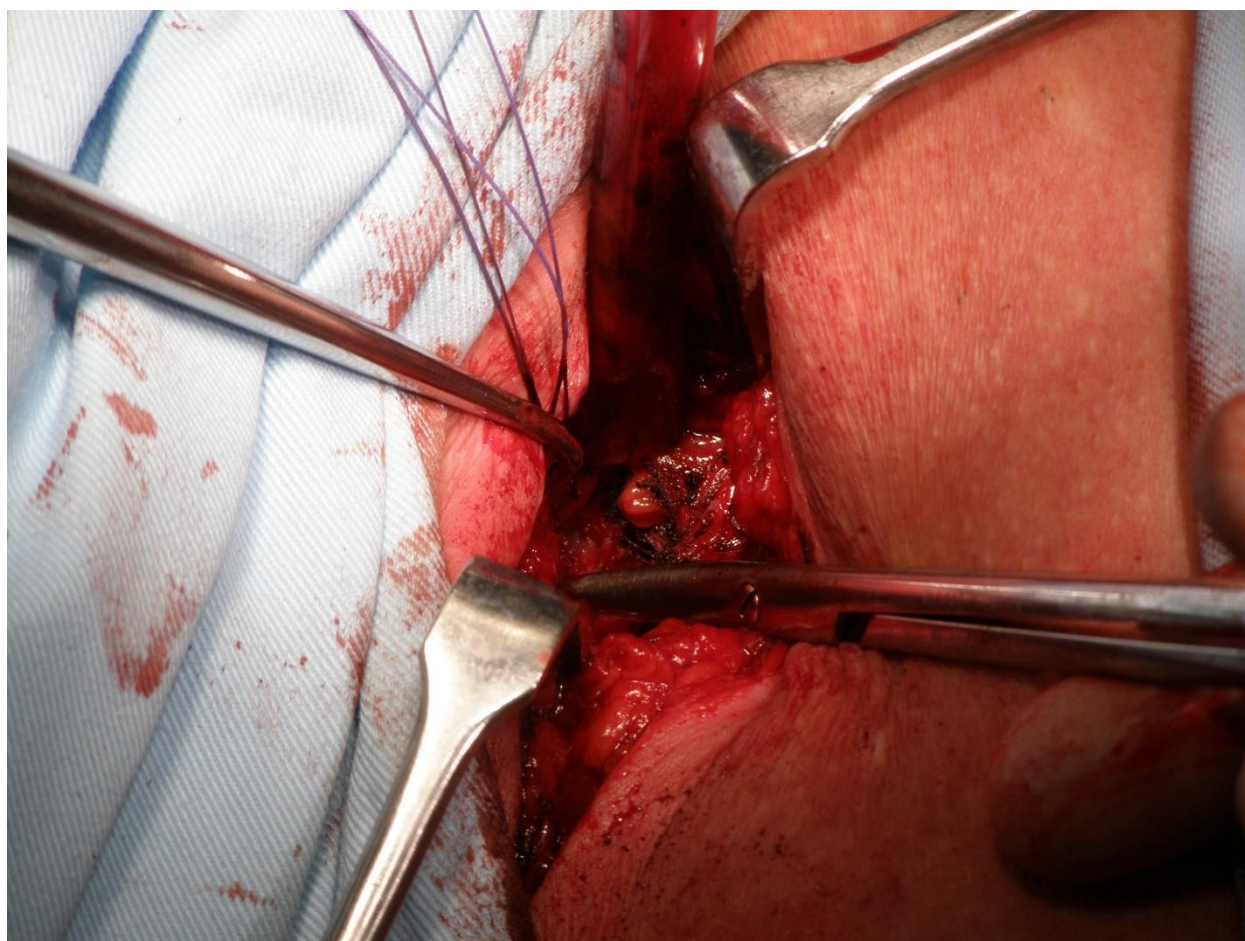


Figure 3. Re-tracheostomy

Paper

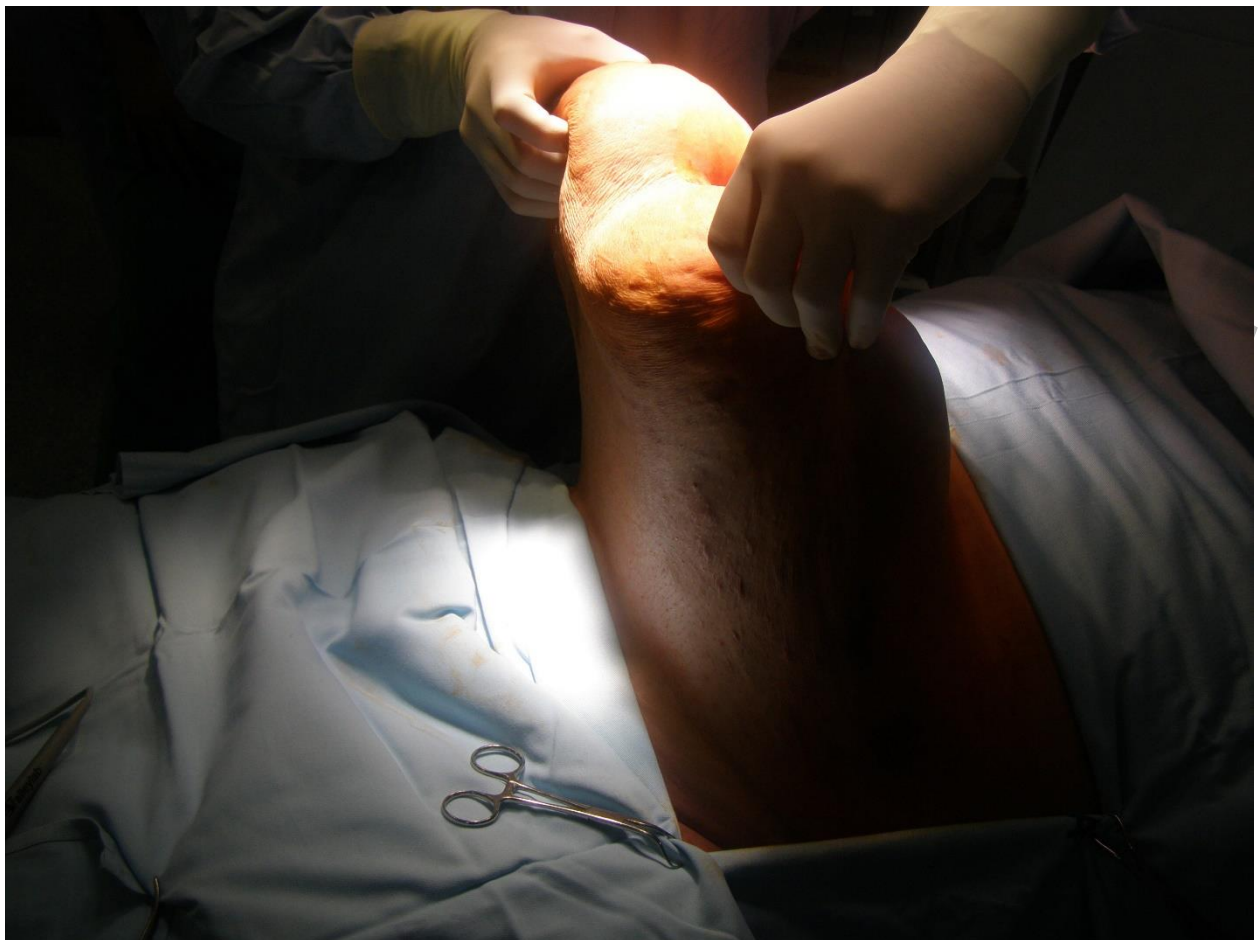

Figure 4. Preparation for panniculectomy

Paper