



СРПСКИ АРХИВ
ЗА ЦЕЛОКУПНО ЛЕКАРСТВО
SERBIAN ARCHIVES
OF MEDICINE

Address: 1 Kraljice Natalije Street, Belgrade 11000, Serbia

+381 11 4092 776, Fax: +381 11 3348 653

E-mail: office@srpskiarhiv.rs, Web address: www.srpskiarhiv.rs

Paper Accepted*

ISSN Online 2406-0895

Original Article / Оригинални рад

Domen Plut^{1,2,†}, Živa Zupančič¹

Prevalence and significance of transient enteroenteric intussusceptions in children with recurrent colic abdominal pain

Преваленца и значајност пролазних ентероентеричних инвагинација код деце са понављајућим абдоминалним коликама

¹Ljubljana University Medical Centre, Clinical Radiology Institute, Ljubljana, Slovenia;

²University of Ljubljana, Faculty of Medicine, Ljubljana, Slovenia

Received: November 19, 2019

Revised: June 24, 2020

Accepted: June 25, 2020

Online First: July 1, 2020

DOI: <https://doi.org/10.2298/SARH191119044P>

***Accepted papers** are articles in press that have gone through due peer review process and have been accepted for publication by the Editorial Board of the *Serbian Archives of Medicine*. They have not yet been copy-edited and/or formatted in the publication house style, and the text may be changed before the final publication.

Although accepted papers do not yet have all the accompanying bibliographic details available, they can already be cited using the year of online publication and the DOI, as follows: the author's last name and initial of the first name, article title, journal title, online first publication month and year, and the DOI; e.g.: Petrović P, Jovanović J. The title of the article. Srp Arh Celok Lek. Online First, February 2017.

When the final article is assigned to volumes/issues of the journal, the Article in Press version will be removed and the final version will appear in the associated published volumes/issues of the journal. The date the article was made available online first will be carried over.

†Correspondence to:

Domen PLUT

Zaloška cesta 2, 1000 Ljubljana, Slovenia

E-mail: plut.domen@gmail.com

Prevalence and significance of transient enteroenteric intussusceptions in children with recurrent colic abdominal pain

Преваленца и значајност пролазних ентероентеричних инвагинација код деце са понављајућим абдоминалним коликама

SUMMARY

Introduction/Objective Recurrent colic abdominal pain (RCAP) is a common complaint in children. Children with this complaint are often referred for abdominal ultrasound (US). Examining the children with RCAP in outpatient clinic by US, we occasionally noticed transient enteroenteric intussusceptions (TEIs) with spontaneous resolution. The aims of our prospective observational study were to determine the prevalence and evaluate the significance of TEIs in children with RCAP.

Methods From January 2016 to December 2017 we examined 358 children with RCAP by US. Age range was 1–17 years (mean age 7.7 years). TEIs were detected and the prevalence determined. The sensation of pain at the time of the US examination was noted.

Results We detected TEI in 41 children; the prevalence was 11.5%. Abdominal pain at the time of the presence of TEI was reported in 17.1% of these children. In the group of children without TEI detected, pain at the time of the examination was reported in only 6%. A statistically significant relationship was found between the presence of TEI and the pain at the time of the examination ($p = 0.046$). No child had other significant abdominal pathology.

Conclusion TEIs happen more commonly in children than previously thought. A rather high prevalence of TEIs in our study group of children with RCAP and the fact that a higher percent of children with detected TEI experienced pain at the time of the examination, are suggestive that TEIs may be one of the causes for the RCAP in children.

Keywords: intestinal invagination; intussusception; ultrasound; ultrasonography; abdominal pain

САЖЕТАК

Увод/Циљ Понављајуће абдоминалне колике (ПАК) често су појава код деце. Деца са ПАК често се упућују на ултразвук (УЗ) абдомена. Прегледајући ту популацију ултразвуком, понекад смо запазили ентероентеричне инвагинације, које су током прегледа обично спонтано регредирале. Циљеви наше проспективне опсервацијске студије су били утврђивање преваленце и процена значајности пролазних ентероентеричних инвагинација (ПЕИ) код деце с ПАК.

Метод Од јануара 2016. до децембра 2017. смо ултразвучно прегледали 358 деце старости 1–17 година (средња старост 7,7 година). ПЕИ смо дијагностицирали и утврдили њихову преваленцу. Регистровали смо осећај бола у време претраге.

Резултат ПЕИ смо открили код 41 детета (преваленца 11,5%). Болове у тренутку присуства ПЕИ имало је 17,1% те деце. Код деце без ПЕИ их је само 6% имало бол. Веза између бола за време прегледа и присуства ПЕИ испоставила се статистички сигнификантна ($p = 0,046$). Ниједно од 358 прегледане деце није имало другу значајну патологију.

Закључак ПЕИ се појављује чешће него што се до сада мислило. Прилично висока преваленца ПЕИ (11,5%) код наших пацијената и чињеница да је већи број деце са откривеним ПЕИ у часу прегледа имао болове, указује да би ПЕИ могле бити један од узрока за ПАК код деце.

Кључне речи: ентероентерична инвагинација; интусусцепција; ултразвук; бол у трбуху

INTRODUCTION

Recurrent colic abdominal pain (RCAP) is a common complaint in children. The differential diagnosis of RCAP is fairly extensive, however most children do not have a serious or even identifiable underlying illness causing the pain [1]. In general, abdominal pain is the most common type of pain in younger children and the second most common in older children and adolescents [2]. In a study, which included around 15.000 children, 20% of

the children reported at least two episodes of abdominal pain in a three months period [3]. Children with abdominal pain are often referred for abdominal ultrasound (US). Improvements in resolution and quality of the ultrasound (US) images now allow detection of small pathologic changes in the abdomen, including bowel intussusceptions. Most often diagnosed and reported intussusceptions were ileocolic; enteroenteric intussusceptions were reported much less frequently [4, 5].

Examining children with RCAP by US in outpatient clinic during the last years, we occasionally detected enteroenteric intussusceptions, which were transient and usually spontaneously resolved during the time of the examination. When an intussusception was present, some children experienced pain. We wondered how common the occurrence of TEIs is, and how significant they are in the context of the management of children with RCAP. Therefore, we decided to conduct a study with the objective to determine the prevalence and evaluate the significance of TEI in children with RCAP.

METHODS

All procedures performed were in accordance with the ethical standards of the institutional and national research committee and with the 1964 Helsinki declaration and its later amendments.

Patients

From January 2016 to December 2017, we examined 358 children referred to our outpatient clinic for abdominal US with the only complaint of RCAP. The pain, as reported by children and parents, was spastic, short lasting, occurring in repeated episodes, and located in the periumbilical region. There was no history of vomiting, rectal bleeding or other warning signs of underlying illness. On physical examination there were no pathologic findings. Basic laboratory studies were normal. Baseline characteristics of the study population are listed in Table 1.

Ultrasound

US examinations were performed on a DC-8 scanner (Mindray Medical International Limited, Shenzhen, China), using a 7-3 MHz convex-array transducer and a 12-4 MHz linear-array transducer. All examinations were performed by an experienced pediatric radiologist well-skilled in the use of US.

During the examination the entire abdomen was thoroughly scanned with both transducers and evaluated for the presence of any pathology. Special attention was paid to the potential signs of small bowel intussusception. The duration of examinations ranged from 15 to 20 minutes.

To determine that a small bowel intussusception was transient in its nature, we used the criteria for transient small bowel intussusception described by Kim et al. in 2004 [6]. These criteria are 1) a small outer diameter (less than 2.5 cm), 2) short (less than 3 cm) segmental intussusception, 3) peristaltic wall motion, and 4) absence of a specific lead point. A typical US appearance of a TEI is shown in Figure 1. Rarely, when we were not certain of the diagnosis of a TEI, because of an unusual location or because of a less typical appearance, a follow-up US was performed after 30-60 minutes. Beside US, no other diagnostic imaging studies were needed for this group of children.

At the start of each US examination the child was asked for the presence of pain at that time. For younger children, the parents were asked to evaluate whether the child was in pain.

Statistical analysis

Descriptive statistics were obtained to describe characteristics of the study group. Chi-squared test was used to evaluate the relationship between the presence of TEI and pain at the time of the US examination. Significance was set at $p < 0.05$. Statistical analysis was performed with SPSS v.22.0 (SPSS Inc., Chicago, USA).

RESULTS

We examined 358 children with RCAP referred to our outpatient clinic for abdominal US. The girls represented 54.7 % of the study group and the boys 45.3%. The mean age of children was 7.7 years. TEIs were detected in 41 of the 358 children, so the prevalence was 11.5 %. Most of the TEIs were detected in children aged between 3 and 6 years (58.5 %). The distribution of TEIs by age is presented in Figure 2. Intussusceptions were more frequently found in boys: boy to girl ratio was 2.73:1. The mean age of the children with TEI was 5.8 years (age range: from 1 to 17 years). Eight children had multiple TEIs (19.5 %); in one boy there were four concurrent TEIs. Nearly all TEIs were located in the mid-abdomen or in the left hemiabdomen; only four TEIs were located in the right lower quadrant of the abdomen (7.7 %). Results are summarized in Table 2.

Some of the children (17.1%) reported abdominal pain at the time of the presence of TEI and majority did not. In the group of children that did not have a TEI detected during the time of the US examination, the pain at the time of the examination was reported only in 6 %. A statistically significant interaction was found between the presence of TEI and the pain at the time of the examination ($\chi^2(1) = 3.98, p = 0.046$).

A lead point was not present in any of the TEIs. There was no evidence of other significant abdominal pathology in any of the children. None of the children returned for a follow-up US examination or for additional other diagnostic imaging study.

DISCUSSION

The aims of our prospective study were to determine the prevalence of TEIs in the group of children with RCAP referred to outpatient clinic for abdominal US and to evaluate the significance of TEIs. The group consisted of 358 children. The prevalence of TEIs was 11.5%.

The prevalence of TEIs in our study is considerably higher than the prevalence previously reported in the literature. In the literature we found only two studies reporting the prevalence of TEIs in children. In the study by Doi et al. [7], the authors examined 550 children with acute abdominal symptomatology. TEIs were found in 21 cases; the prevalence

was 3.8 %. The intussusceptions were more common in boys (boy to girl ratio was 1.63:1), similar to our study. Mean age of the children with TEI was 6.2 years, also similar to our study. In the study by Strouse et al. [5], the authors retrogradely reviewed approximately 6000 reports of abdominal CT scans in children. TEIs were reported in 25 cases; the prevalence was 0.4 %. TEIs were more common in boys (boy to girl ratio was 1.8:1), similar to our and Doi et al. study. Mean age of the children with TEI was 11.2 years, more than in our study. In both studies, all enteroenteric intussusceptions were transient in nature (as diagnosed by a follow up CT scan, US, barium swallow study or surgery) and there was no presence of lead points in any of the intussusceptions, the same as in our study. The reason for the higher prevalence of TEIs in our study could most likely be due to the differences of the study groups. Our study group consisted only of the children who all had the history of RCAP, while Doi et al. study group consisted of the children who all had acute abdominal symptomatology, and Strouse et al. group consisted of the children who all had abdominal CT scan indicated for diverse abdominal problems. Because of higher incidence of TEIs in our homogenous group of children with RCAP, we suspect that TEIs could be one of the reasons for the RCAP in children.

It is known, that there are chemical and mechanical nociceptors in the enteric wall [8]. Based on this fact, two pathophysiologic mechanisms could explain the occurrence of the colic abdominal pain caused by enteroenteric intussusceptions. Firstly, intussusceptions that last a longer period of time and/or have a strong peristaltic activity may cause so much bowel wall compression and vein strain that it potentially leads to some degree of hypoxia or even ischemia, which in turn leads to the pain through activation of the chemical nociceptors in the bowel wall. And vice versa, intussusceptions that do not cause ischemia do not cause the pain. This most likely happens in the intussusceptions with weaker peristaltic activity and/or in the intussusceptions that last a short period of time. Secondly, intussusceptions that cause more bowel wall extension could lead to the pain through the activation of stretch mechanic nociceptors in the bowel wall of the intussusceptions. These two mechanisms may also explain the fact that in our study some children complained of the pain when TEI was present, while some did not. The same finding was noted and reported by other authors [9].

The complaint of pain at the time of the US examination additionally strengthens our theory that TEIs could be one of the causes of RCAP in children. During our study 17.1 % of the children with RCAP that had a TEI diagnosed at the US examination reported pain at the

time, while in the group of children with RCAP and no TEI diagnosed during the examination, the pain during the examination was reported only in 6 % of the children. The relationship between the presence of TEI and pain at the time of the US examination was found to be statistically significant ($p < 0.05$).

In 2020, Goel et al. published a study which included 90 children with clinical suspicion of intussusception. All included children had acute abdominal pain. In 15 of those children a TEI was the only pathologic finding [10]. This fact affirms the finding from our study, that some TEIs cause acute abdominal pain. Additionally, in all those cases, the TEI involved a short bowel segment (less than 3 cm in length) and had a small outer diameter (less than 2.5 cm), which is also in line with findings from our study [10].

To diagnose a TEI we used the criteria set by Kim [6]. The criteria turned out to be reliable and easy to use. The criteria were also useful to distinguish between ileocolic intussusception and enteroenteric intussusception when the intussusception was located in the right hemiabdomen. Nevertheless, in these cases we did a follow up US in 30-60 minutes. In none of the children TEIs were present on these follow up US. That confirmed that these intussusceptions were correctly diagnosed as TEIs by the diagnostic criteria by Kim. Other authors also report that US can reliably differentiate between ileocolic and enteroenteric intussusception [10, 11]. On the other hand, not long ago Bartocci et al. reported that it can be difficult to distinguish between an ileocolic intussusception and enteroenteric intussusception by US, and pointed out that the correctness of diagnosing depends very much on the experience of the examiner [12].

Concerning the clinical significance of RCAP in childhood we turned to the pediatric Rome classifications for Childhood functional gastrointestinal disorders [13]. According to the most recent Rome IV classification, published in 2016, TEIs in relation to the RACP are not included in any specific category. By clinical symptomatology TEIs would fit into the category of the "Functional abdominal pain disorders - not otherwise specified". The diagnostic criteria for the "Functional abdominal pain - not otherwise specified" are: 1) at least 4 episodes of abdominal pain per month that does not occur solely during physiologic events (e.g. eating, menses), 2) insufficient criteria for irritable bowel, functional dyspepsia, or abdominal migraine, and 3) exclusion of other medical conditions that fully explain the abdominal pain [13]. TEIs could be one of the medical conditions that fully explain the occurrence of the abdominal pain of the category of the "Functional abdominal pain disorders

- not otherwise specified". The reason that TEIs are not included in the Rome classification may be due to the facts, that it is not possible to diagnose TEIs by clinical examination or laboratory studies, their spontaneously resolving nature, and low rate of detection of TEIs by radiologic imaging in the past. So, the TEIs were simply considered to be rare and of low importance.

Abdominal pain can be caused by a severe disease and require direct treatment. On the other hand, the pain can have a harmless cause, like in TEIs, and no direct treatment is needed. Nevertheless, repeated episodes of pain due to the TEIs, though not endangering, cause anxiety, impair the child's self-perception of health, interfere with every day activities of the child and the family, and can considerably worsen the quality of their life. According to the pediatric guidelines concerning the treatment, in the category of the "Functional abdominal pain disorders - not otherwise specified", into which the pain associated with TEIs could fit, indirect treatment only is said to be beneficial. Pharmacotherapy is not recommended [14]. When the symptoms persist for a longer period of time, consultation with a pediatric psychologist may be helpful. The goal of the treatment is not a total elimination of the symptoms, but rather the acquisition of strategies for coping with the pain and getting on with life. For school-age children, getting back to school is a prime objective [15]. Cognitive behavioral therapy reduces pain, general stress, and reduces passive and avoidant behavior [16].

US examination is important for the group of children with RCAP. Firstly, for medical reasons, because by US TEIs can be diagnosed as the cause for the RCAP, and other potential causes for the RCAP can be diagnosed or excluded. US is also important in the psycho-social context. Though TEIs do not endanger the children and do not require specific medical treatment, as already mentioned, RCAP interferes with everyday activities of the child and. When we detect a TEI by US, we explain to the parents what the TEI is, its pathophysiological mechanism, and its association with RCAP. We inform them that RCAP caused by TEIs does not endanger the child. We also advise the child and parents how to cope with the pain. We suggest that the child, when experiencing pain, stops with the activity and lays down if possible. The parents can gently massage the abdomen, and soothe the child by gentle communication and maybe by reading to the child. The approach to the child and parents must be done with empathy. Even in the group of children with RCAP in whom we do not detect a TEI during US examination, due to the same symptomatology, we simply

assume that TEIs do occur at other times and could be the cause for the RCAP. Therefore, we provide the parents the same possible explanation and advice as in the group of children in whom we detect TEIs. We believe that this holistic approach is helpful, as by our experience, the return rate of these children for the repeated US examination is low.

Our study was limited by the lack of pathological correlation in TEIs, since no surgery is needed for TEIs because of their spontaneously resolving nature. Another limitation of our study is a lack of a control group. It is difficult to get a referral for abdominal US examination for a comparable group of healthy children without any symptoms.

CONCLUSION

The occurrence of transient enteroenteric intussusceptions is a more common phenomenon in children than previously thought. In our group of children with recurrent colic abdominal pain examined by ultrasound the prevalence of transient enteroenteric intussusceptions was 11.5%. This rather high prevalence in our study and the fact that a higher percent of children with detected TEI experienced pain at the time of the presence of the intussusception are suggestive that transient enteroenteric intussusceptions can be the cause for the recurrent colic abdominal pain in children.

Recurrent colic abdominal pain can interfere with everyday activities of the child and family and worsen the quality of their life. Empathic explanation to the parents that transient enteroenteric intussusceptions may be the cause for the recurrent colic abdominal pain, and the explanation of the pathophysiology of transient enteroenteric intussusceptions in association with recurrent colic abdominal pain is relieving for the parents and child, and can help them return to more normal everyday life functioning.

ACKNOWLEDGEMENT

Early results of this study were presented at the Annual meeting of the European Society of Pediatric Radiology in Berlin in June 2018 with an abstract and a short presentation. The paper is not under consideration for publication elsewhere.

Conflict of interest: None declared.

REFERENCES

1. Thornton GCD, Goldacre MJ, Goldacre R, Howarth LJ. Diagnostic outcomes following childhood non-specific abdominal pain: a record-linkage study. *Arch Dis Child*. 2016 Apr;101(4):305–309. doi:10.1136/archdischild-2015-308198
2. Gulewitsch MD, Müller J, Enck, P, Weimer K, Schwille-Kiuntke J, Schlarb AA. Frequent Abdominal Pain in Childhood and Youth: A Systematic Review of Psychophysiological Characteristics. *Gastroenterol Res Pract*. 2014;2014:524383. doi:10.1155/2014/524383
3. Du Y, Knopf H, Zhuang W, Ellert U. Pain perceived in a national community sample of German children and adolescents. *Eur J Pain*. 2011 Jul;15(6):649–57. doi:10.1016/j.ejpain.2010.11.009
4. Güney LH, Fakioglu E, Acer T, Ötgün İ, Arslan EE, Sağnak Akıllı M, et al. Is every intussusception treatment an emergency intervention or surgery? *Ulus Travma Acil Cerrahi Derg*. 2016 Mar;22(2):139–144. doi:10.5505/tjtes.2015.06013
5. Strouse PJ, DiPietro MA, Saez F. Transient small-bowel intussusception in children on CT. *Pediatr Radiol*. 2003 May;33(5):316–20. doi:10.1007/s00247-003-0870-4
6. Kim HJ. US Features of Transient Small Bowel Intussusception in Pediatric Patients. *Korean J Radiol*. 2004 Jul-Sep;5(3):178–84. doi:10.3348/kjr.2004.5.3.178
7. Doi O, Aoyama K, Hutson JM. Twenty-one cases of small bowel intussusception: the pathophysiology of idiopathic intussusception and the concept of benign small bowel intussusception. *Pediatr Surg Int*. 2004 Feb;20(2):140–3. doi:10.1007/s00383-003-1055-9
8. Saghazadeh A, Mojtavavi H, Khaksar R, Mahmoudi M, Rezaei N. The Sixth Sense Organs: The Gut. In: Rezaei N, Saghazadeh A, editors. *Biophysics and Neurophysiology of the Sixth Sense*. Cham: Springer; 2019. p. 251–256.
9. Melvin JE, Zuckerbraun NS, Nworgu CR, Mollen KP, Furtado AD, Manole MD. Management and Outcome of Pediatric Patients with Transient Small Bowel-Intussusception. *Pediatr Emerg Care*. Epub 2018 May 5. doi:10.1097/PEC.0000000000001503
10. Goel I, Anand R, Choudhury SR, Agarwal S. Evolving Concepts in Ultrasonography of Pediatric Intussusceptions: Unequivocal Differentiation of Ileocolic, Obstructive and Transient Small-Bowel Intussusceptions. *Ultrasound Med Biol*. 2020;46:589–97. doi: 10.1016/j.ultrasmedbio.2019.12.011
11. Levinson H, Capua T, Scolnik D, Rimon A, Salomon L, Glatstein M. Comparison Between Small and Large Bowel Intussusception in Children: The Experience of a Large Tertiary Care Pediatric Hospital. *Pediatr Emerg Care*. Epub 2018 Jan 15. doi:10.1097/PEC.0000000000001393
12. Bartocci M, Fabrizi G, Valente I, Manzoni C, Specca S, Bonomo L. Intussusception in childhood: role of sonography on diagnosis and treatment. *J Ultrasound*. 2014 Jul 19;18(3):205–11. doi:10.1007/s40477-014-0110-9
13. Hyams JS, Di Lorenzo C, Saps M, Shulman RJ, Staiano A, van Tilburg M. Functional Disorders: Children and Adolescents. *Gastroenterol*. 2016 May;150(6):1456–68. doi:10.1053/j.gastro.2016.02.015
14. Bufler P, Gross M, Uhlig HH. Recurrent Abdominal Pain in Childhood. *Dtsch Arztebl Int*. 2011 Apr;108(17):295–304. doi:10.3238/arztebl.2011.0295
15. Di Lorenzo C, Colletti RB, Lehmann HP, Boyle JT, Gerson WT, Hyams JS, et al. Chronic abdominal pain in children: a technical report of the American Academy of Pediatrics and the North American Society for Pediatric Gastroenterology, Hepatology and Nutrition. *J Pediatr Gastroenterol Nutr*. 2005 Mar;40(3):249–61. doi:10.1097/01.mpg.0000154661.39488.ac
16. Urits I, Hubble A, Peterson E, Orhurhu V, Ernst CA, Kaye AD, et al. An Update on Cognitive Therapy for the Management of Chronic Pain: a Comprehensive Review. *Curr Pain Headache Rep*. 2019 Jul 10;23(8):57. doi:10.1007/s11916-019-0794-9

Table 1. Baseline characteristics of the study population

Number of patients	358		
Sex		162 boys	196 girls
Age range [years]	1–17	1–17	1–17
Mean age [years]	7.7	7.4	8.1

Paper accepted

Table 2. Results

Parameter	Total n (%)	Boys n (%)	Girls n (%)
No. of patients	358 (100)	162 (45.3)	196 (54.7)
No. of children with TEI (prevalence)	41 (11.5)	30 (18.5)	11 (5.6)
boy:girl ratio	2.73:1		
Age with TEI (range; mean) [years]	1–17; 5.8	1–17; 6.1	1–12; 4.7
Children with TEIs by age (years)			
< 3	5 (12.2)	4	1
3–6	24 (58.5)	15	9
7–12	11 (26.8)	10	1
> 13	1 (2.4)	1	0

TEI – transient enteroenteric intussusception

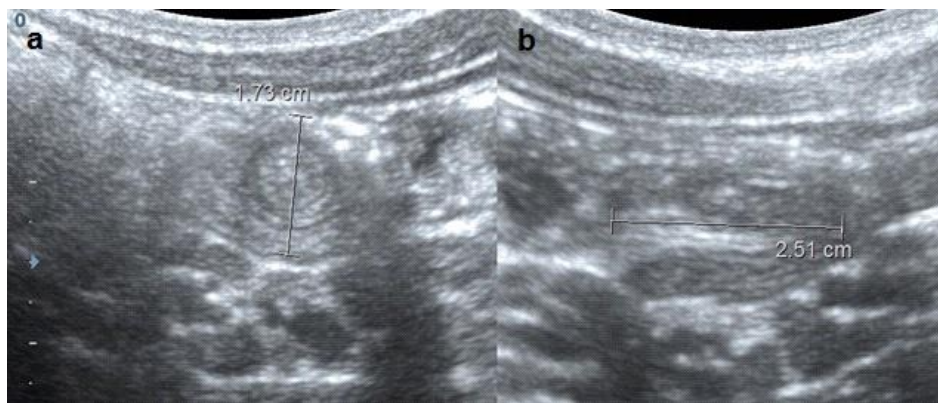


Figure 1. Ultrasound image of a transient enteroenteric intussusception (TEI) in the transversal (a) and the longitudinal (b) plane; the image shows a typical appearance of a TEI: small outer diameter – less than 2.5 cm (in the image of the transversal plane), short bowel segment – less than 3 cm (in the image of the longitudinal plane), and no lead point

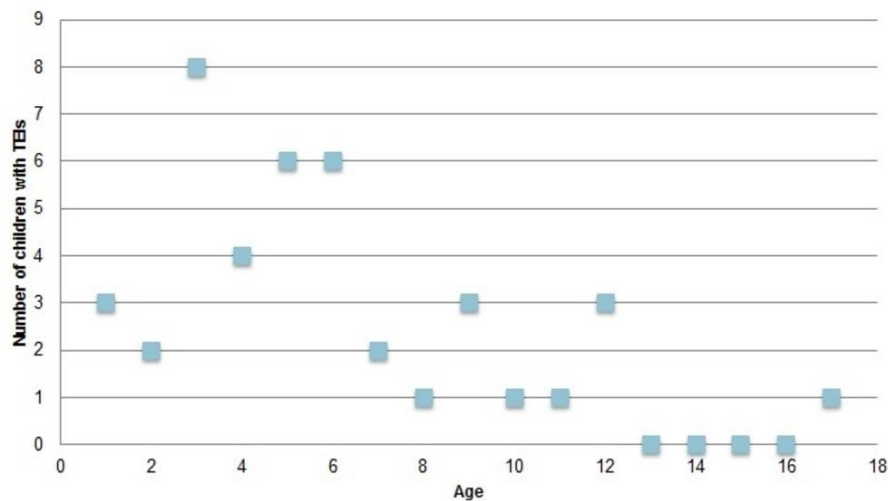


Figure 2. Distribution of transient enteroenteric intussusceptions (TEIs) by age; the chart of distribution of TEIs by age shows that TEIs are the most common in children aged 3–6 years; this group of children represented 58.5% of diagnosed cases; TEIs were rarely found in children aged < 3 years and aged 7–12, and very rarely in children > 13 years (only one child in our study)