



Paper Accepted*

ISSN Online 2406-0895

Original Article / Оригинални рад

Ebru Hazar Bodrumlu^{1,†}, Aysun Avşar²

Molar Incisor Hypomineralization in Children with Systemic Diseases

Хипоминарализација кутњака и секутића код деце са системским обољењима

¹ Department of Pediatric Dentistry, Faculty of Dentistry, Bülent Ecevit University, Zonguldak, Turkey;

² Department of Pediatric Dentistry, Faculty of Dentistry, Ondokuz Mayıs University, Samsun, Turkey

Received: January 18, 2018

Revised: April 10, 2018

Accepted: April 12, 2018

Online First: April 17, 2018

DOI: <https://doi.org/10.2298/SARH180118036B>

* **Accepted papers** are articles in press that have gone through due peer review process and have been accepted for publication by the Editorial Board of the *Serbian Archives of Medicine*. They have not yet been copy edited and/or formatted in the publication house style, and the text may be changed before the final publication.

Although accepted papers do not yet have all the accompanying bibliographic details available, they can already be cited using the year of online publication and the DOI, as follows: the author's last name and initial of the first name, article title, journal title, online first publication month and year, and the DOI; e.g.: Petrović P, Jovanović J. The title of the article. *Srp Arh Celok Lek*. Online First, February 2017.

When the final article is assigned to volumes/issues of the journal, the Article in Press version will be removed and the final version will appear in the associated published volumes/issues of the journal. The date the article was made available online first will be carried over.

† **Correspondence to:**

Ebru HAZAR BODRUMLU

Department of pediatric dentistry, Faculty of Dentistry, Zonguldak/Turkey

E-mail: hazarebru@yahoo.com

Molar Incisor Hypomineralization in Children with Systemic Diseases

Хипоминарализација кутњака и секутића код деце са системским обољењима

SUMMARY

Introduction/Objective Molar incisor hypomineralization (MIH) is an important clinical problem, but its exact etiology is unknown.

The aims of this study was to evaluate MIH in children with systemic diseases diagnosed before the age of 4 and assess whether systemic diseases are a risk factor for the development of MIH.

Methods A total of 394 children aged 8 and older, who had been diagnosed with a systemic disease under the age of 4 were included in the study group. A total of 18 different systemic diseases were assessed. An additional 394 children with no systemic disease were included in the control group. All the children were evaluated for the presence of MIH.

Results The frequency of MIH in the study group and control group was found to be 28.93% and 23.60%, respectively ($p < 0.05$). Of all the systemic diseases evaluated in this study, nephrotic syndrome ($OR=1$), congenital hypothyroid ($OR = 0.96$, 95% CI: 0.22–4.10), and Wilms' tumor ($OR=0.57$, 95% CI: 0.07–4.64) were determined to be risk factors for the development of MIH.

Conclusion Wilms' tumor, congenital hypothyroid, and nephrotic syndrome may be considered to be risk factors for MIH.

Keywords: child; Molar Incisor Hypomineralization; Systemic Disease

САЖЕТАК

Увод/Циљ Хипоминарализација кутњака и секутића (ХКС) је важан клинички проблем, али његова тачна етиологија није позната.

Циљ ове студије је био да утврди ХКС код деце са дијагностикованим системским болестима пре четврте године и процени да ли оне представљају фактор ризика за развој ХКС.

Метод У студијску групу учествовало је укупно 394 деце узраста од осам и више година са дијагностикованом системском болести пре четврте године. Процењено је укупно 18 различитих системских болести. У контролну групу укључено је 394 здрава детета без системске болести. Сва деца су испитана на присуство ХКС.

Резултати Утврђено је да учесталост ХКС у студијској групи и контролној групи износи 28,93% и 23,60%, односно ($p < 0,05$). Од свих системских болести процењених у овој студији, нефротски синдром ($OR=1$), конгенитална хипотиреоза ($OR=0,96$, 95% CI: 0,22–4,10) и Вилмсов тумор ($OR= 0,57$, 95% CI: 0,07–4,64) утврђени су фактори ризика за развој ХКС.

Закључак Вилмсов тумор, конгенитални хипотиреоза и нефротични синдром могу се сматрати факторима ризика за МИХ.

Кључне речи: дете, хипоминарализација кутњака и секутића, системска болест

INTRODUCTION

Systemic diseases occur in approximately 10% to 20% of children across the globe. More than 85% of these children can live until the age of 20 by means of emerging technologies and current therapeutic approaches [1]. Depending on the length of a patient's lifetime, systemic diseases can also increase the prevalence of adverse effects on oral tissue [1, 2]. Because signs of systemic diseases can initially be manifested in the oral cavity, oral diseases may develop depending on the outcome of the systemic disease or the type of drugs administered to treat it [1, 3]. Oral and dental health in the children with systemic diseases is very important due to both the effect of a systemic disease on a child's growth and development and the risk of developing an infection [1].

Molar incisor hypomineralization (MIH) is an acquired developmental enamel defect resulting in hypomineralized teeth. Its precise etiology is unknown and its general distribution has not yet been observed. MIH is also described as a hypomineralization of systemic origin affecting one or more of the four-first permanent molars that are often associated with the incisors [4]. Its incidence varies from 2.8% to 44% [5, 6, 7]. Systemic diseases and environmental factors that affect the natal and early period of childhood development are among the factors thought to lead to MIH. To date, studies

have reported that various factors, such as birth complications, preterm labor and low birth weight, celiac disease, respiratory tract infections, high fever, nephropathies, and the use of antibiotics, can lead to developmental enamel defects. Nevertheless, studies that focus on a child's retrospective medical and dental history are insufficient for understanding the exact reasons that these factors result in MIH [8, 9]. Moreover, multiple medical conditions arising in the early years of a child's life make it difficult to determine the etiology of MIH during the time in which it first occurs until its eruption phase [9].

Since the etiological factors that cause MIH cannot be fully understood at the present, this study aims to assess whether systemic diseases are a risk factor for the development of MIH by evaluating children with systemic diseases who have been certifiably diagnosed, not diagnosed using memory-based information. The null hypothesis tested was that systemic diseases have no effect on the development of MIH.

METHODS

This research study was conducted at Ondokuz Mayıs University (OMU), Faculty of Dentistry, Department of Pediatric Dentistry and Faculty of Medicine. It was approved by the OMU Medical Research Ethics Committee (number 2010/168). Informed consent forms were obtained from the parents before clinical examination of their children.

This study was performed as a retrospective cohort study. As the study group, children aged 8 and older, who had been diagnosed with a systemic disease when they were under the age of 4 at the Department of Pediatrics of Faculty of Medicine OMU, were evaluated. Patients assessed to be included in the study group were referred to the OMU Faculty of Medicine, Department of Pediatrics on the day they arrived for an appointment, and they were referred to the OMU Faculty of Dentistry after consultation by a relevant physician and after being evaluated in the Pedodontics Department.

As a result of conducting interviews with the Department of Pediatrics, the following were diseases evaluated within the scope of this study: Asthma and asthma + allergic rhinitis (Department of Pediatric Allergy-Immunology); Diabetes and congenital hypothyroidism (Department of Pediatric Endocrinology); Celiac disease (Department of Pediatric Gastroenterology); Acute lymphoblastic leukemia, hemophilia A, Wilms' tumor, medulloblastoma, neuroblastoma, and Hodgkin's lymphoma (Department of Pediatric Hematology-Oncology); Nephrotic syndrome, chronic renal failure, and familial Mediterranean fever (Department of Pediatric Nephrology); Epilepsy, epilepsy + mental retardation and cerebral palsy (Department of Pediatric Neurology); Ventricular septal defects (Department of Pediatric Cardiology).

The following inclusion criteria were used to select participants for the study group and the control group: Children aged 8 and older who had been diagnosed with one of the diseases listed above before the age of 4, and whose first permanent molars and incisors had erupted, were selected

for the study group; Children aged 8 and older who did not have any systemic disease, but whose first permanent molars and incisors had erupted, were chosen for the control group.

The following criteria were used to exclude children from participating in the study: Children who had a systemic disease, but who had been diagnosed with systemic diseases after the age of 4; Children who left their first permanent molars and incisors out of the assessment due to the congenital lack of permanent teeth.

A total of 907 children with systemic diseases were included in the preliminary assessment within the scope of this study. Of those, 394 were included in the study group. An additional 394 children who had visited the OMU Faculty of Dentistry, Department of Pediatric Dentistry, and who did not suffer from any type of systemic disease, were included in the control group. The participants in the control group (healthy) and the study group (with a systemic disease) were age- and sex-matched.

The presence of MIH was detected with the aid of a mirror and a probe by using a reflector halogen lamp in the dental unit based on the criteria determined by Weerheijm². These criteria include the presence or absence of limited opacity, enamel destruction after tooth eruption, and atypical restorations and tooth extractions due to MIH [4]. To determine an MIH diagnosis, at least one first permanent molar had to have been affected. If only the incisors were affected, the diagnosis was not considered to be MIH due to the possibility that the defects in these teeth could occur as a result of local factors, such as trauma and tooth decay. This assessment also evaluated whether limited opacity existed in other teeth of patients who did not have relevant teeth in their mouth due to tooth extraction. If there was limited opacity in other teeth, the patient was considered to be affected by MIH [6]. Disorders assessed in differential diagnosis include amelogenesis imperfecta, dentinogenesis imperfecta, hypoplasia, diffuse opacities, white spot lesions, discoloration and dental fluorosis caused by tetracycline. In line with these criteria, teeth numbered 11, 12, 21, 22, 31, 32, 41, 42, 16, 26, 36, and 46 (according to FDI World Dental Federation notation of the teeth) were evaluated and recorded. To assess the reproducibility of these clinical observations, 10% of the children who participated in the study group were re-evaluated two weeks after the first examination and a high degree of agreement was found (Kappa: 0.98).

Statistical Analysis Software (SAS 2009) was used to analyze the data (SAS Campus Drive, Cary, NC, USA). Basically, the frequency distributions and descriptive statistics of all data were calculated. Chi-square analysis was employed for discrete data. Odds ratios (OR) values were used to compare the differences between the control and the study group in terms of statistical significance. Non-parametric logistic regression analysis and probability tests were used. Logistic regression analysis was used to investigate the effects of systemic diseases on MIH and to compare intra-group and inter-group similarities and differences. OR values were also examined for sub-groups and used as a reference for pairwise comparisons.

RESULTS

The power of the study was found to be 0.80 at alpha 0.05. Because 394 children (188 girls and 206 boys) diagnosed with a systemic disease were evaluated in the study group, 394 age- and sex-matched healthy children were assessed in the control group. MIH was observed in 114 of the children in the study group, but it was only detected in 93 of the children in the control group.

The mean age of cases evaluated in the study and control groups was found to be 10.59 ± 0.09 and 10.57 ± 0.09 , respectively. The mean age of children with MIH in the study group was 10.67 ± 0.16 ; it was 10.55 ± 0.11 for children in the study group without MIH. The mean age of children with MIH in the control group was 10.83 ± 0.18 ; it was 10.50 ± 0.10 for children in the control group without MIH. There was no statistically significant difference between the mean age of cases with and without MIH in both groups (respectively, $p=0.56$ and $p=0.12$). Similarly, no statistically significant difference was found between the mean age of the children with MIH in the study group and the children with MIH in the control group ($p=0.533$). No statistically significant difference was observed between the mean age of the children without MIH in both groups ($p=0.718$).

Analysis of MIH Prevalence in the Study and Control Groups

The prevalence of MIH was 28.93% in the study group and 23.60% in the control group. There was a statistically significant difference between the groups (Chi-square value $\chi^2_{v=1}=2.8895$ $p=0.0037$) (Figure 1).

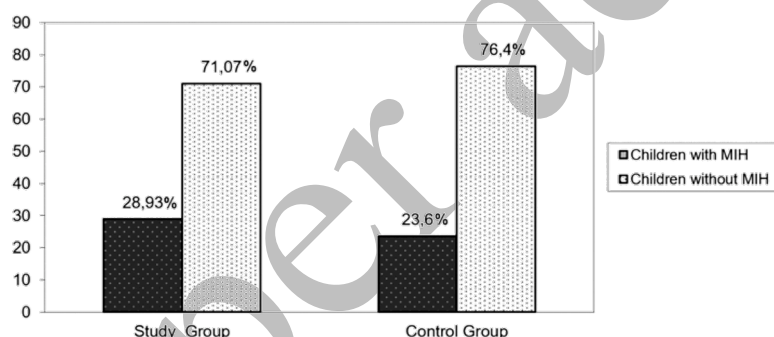


Figure 1. Analysis of MIH prevalence in the study group and the control group.

Assessment of Systemic Diseases as Risk Factors

In the study, 18 different systemic diseases were assessed to determine if they were risk factors for MIH. Wilms' tumor, congenital hypothyroidism, and nephrotic syndrome were found to be a risk factor for MIH. Analysis to determine the effects of systemic diseases on the development of MIH revealed that children with nephrotic syndrome had the highest risk factor for MIH, and this disease was taken as a reference for the other studied diseases. Hemophilia A was found to be the type of systemic disease with the lowest risk factor for MIH. Patients with nephrotic syndrome were found to have a higher risk of developing MIH (OR=15.42) than patients with hemophilia A ($p=0.006$). Patients with nephrotic syndrome were found to have a 5.14-times greater risk of MIH than patients with celiac disease ($p=0.020$). While patients with nephrotic syndrome were found to be at a higher risk for developing MIH than patients with others systemic diseases, for these children the risk was insignificant in comparison to children with Wilms' tumor (OR=0.57) and

congenital hypothyroidism (OR=0.96). Patients with familial Mediterranean fever, acute lymphoblastic leukemia, asthma, an association of asthma and allergic rhinitis, diabetes, epilepsy, a combination of epilepsy and mental retardation, Hodgkin's lymphoma, chronic renal failure, medulloblastoma, neuroblastoma, cerebral palsy, and ventricular septal defects were found to not be at risk for MIH (Table 1) in comparison to those with nephrotic syndrome.

Table 1. Assessment of systemic diseases as risk factors in the development of MIH.

Diagnosis	No MIH n (%)	MIH n (%)	ODDS RATIO (%95 CI)	P
Familial Mediterranean Fever	7 (1.78)	16 (4.06)	1.95 (0.48–7.99)	0.3524
Acute lymphoblastic leukemia	5 (1.27)	21 (5.33)	3.60 (0.83–15.54)	0.082
Asthma	10 (2.54)	22 (5.58)	1.88 (0.50–7.07)	0.349
Asthma + Allergic rhinitis	17 (4.31)	22 (5.58)	1.10 (0.31–3.91)	0.686
Celiac disease	5 (1.27)	30 (7.61)	5.14 (1.21–21.79)	0.0209*
Diabetes	8 (2.03)	21 (5.33)	2.25 (0.57–8.77)	0.243
Epilepsy	11 (2.79)	25 (6.35)	1.94 (0.53–7.15)	0.316
Epilepsy + Mental retardation	6 (1.52)	10 (1.54)	1.42 (0.32–4.32)	0.643
Hemophilia A	1 (0.25)	18 (4.57)	15.42 (1.56–52.34)	0.006*
Hodgkin's lymphoma	5 (1.27)	10 (2.54)	1.71 (0.37–7.91)	0.496
Congenital hypothyroidism	8 (2.03)	9 (2.28)	0.96 (0.22–4.10)	0.961
Chronic renal failure	6 (1.52)	17 (4.31)	2.42 (0.57–10.18)	0.226
Medulloblastoma	1 (0.25)	6 (1.52)	5.14 (0.47–55.64)	0.164
Neuroblastoma	1 (0.25)	4 (1.02)	3.42 (0.29–36.63)	0.3218
Cerebral palsy	5 (1.27)	8 (2.03)	1.37 (0.28–6.53)	0.697
Ventricular septal defects	9 (2.28)	32 (8.12)	3.04 (0.81–11.38)	0.092
Wilms' tumor	3 (0.76)	2 (0.51)	0.57 (0.07–4.64)	0.352
Nephrotic syndrome	6 (1.52)	7 (1.78)	1	

DISCUSSION

MIH is a developmental enamel defect that occurs in the first permanent molars and incisors. Although many studies have examined the subject, the etiology of MIH still remains unexplained [10]. The data in previous studies that evaluated the etiology of MIH were obtained through surveys based on individual memory or personal interviews. In these previous studies, parents provided researchers with information based on their recollection of the problems their children experienced in the first three years of their life [8]. Moreover, when data are collected in this way, they cannot fully

reflect the period between 0 to 4 years due to retrospective information [10]. Because no study exists to evaluate children who establish a final diagnosis before the age of 4, there is no data clearly demonstrating the effects of systemic diseases on MIH [6]. Thus, using a definitive MIH diagnosis our study evaluated children with systemic diseases referred to us by their doctors who continued their treatment. For data collection, medical records were considered, not information recollected by a patient's family. Consequently, the present study compared the prevalence of MIH between the study

group and the control group, suggesting that MIH developed more often in children with systemic diseases. Thus, the null hypothesis that systemic diseases have no effect on the development of MIH was rejected.

When the systemic diseases were considered alone, in our study children with Wilms' tumor were found to have the highest risk for developing MIH. In their dental and radiographic study on the long-term impact that chemotherapy had on the dental tissue of 27 Wilms' tumor patients, Marec-Berard et al. [11] reported that the development of microdontia, hypodontia, enamel hypoplasia, and short root occurred in 7%, 18%, 22%, and 44% of patients with 3.6 being the average age of diagnosis, respectively. This indicates that these abnormalities could be due to complications from the chemotherapy treatment. In order to evaluate oral health after solid tumor and lymphoma treatment, Hutton et al. [12] examined a total of 120 cancer patients, 24.2%, 8.3%, 11.7%, 8.3%, 17.5%, and 30% of whom had Wilms' tumor, rhabdomyosarcoma, Hodgkin's lymphoma, non-Hodgkin's lymphoma, neuroblastoma, and other solid tumors, respectively. They reported that enamel opacities were present in 62.5% of the patients, and 15% of these opacities consisted of limited opacities. Avşar et al. [13] compared 96 patients who had undergone cancer treatment, including 18 diagnosed with Wilms' tumor, with healthy individuals in the same age group; they reported that 69.8% of the study group and 19.8% of the control group suffered from enamel defects. In contrast to these studies, Çubukçu et al. [2] analyzed dental development disorders in a total of 37 patients diagnosed with a solid tumor and lymphoma, including 8 cases diagnosed with Wilms' tumor before the age of 10. They stated that 16.2%, 86.4%, and 13.5% of these patients suffered from tooth agenesis, root development disorder, and microdontia, respectively. However, they did not observe any mineralization disorder. Studies investigating the effect of cancer treatment on tooth development have highlighted that chemotherapy could affect the functions of ameloblasts during the formation of enamel, thereby leading to the development of enamel defects [11, 12]. The effect that the treatment administered to patients with Wilms' tumor had on MIH was not evaluated in our study due to the limited number of patients diagnosed with this systemic disease.

In our study, we analyzed patients with Wilms' tumor, medulloblastoma, Hodgkin's lymphoma, neuroblastoma, and acute lymphoblastic leukemia who had received chemotherapy and radiotherapy to determine their risk of developing MIH, but only Wilms' tumor was considered to be important as a potential risk factor for MIH. This suggests that the characteristics of the disease rather than the efficacy of the treatment had an impact on whether patients with Wilms' tumor would develop MIH. Ottoman *et al.* [14] examined 49 Wilms' tumor patients and reported that they observed osteopenia in 27% of them. They stressed that this result was not associated with the treatment; rather, it might have occurred as a result of a renal tubular defect. It is well known that mineral disorders resulting from systemic conditions may also affect mineralization in dental tissues [15, 16]. In the present study, we suggest that Wilms' tumor, for which osteopenia is characterized by a reduction in

bone mineral density, may also impact the development of MIH by causing mineral disorders in the enamel as a result of the occurrence of the disease during the formation of dental tissues.

Congenital hypothyroidism patients are ranked second as a risk group for the development of MIH. Noren and Alm [3] examined the enamel of deciduous teeth of patients with congenital hypothyroidism under polarized light microscopy and using microradiograph. They emphasized that deterioration due to increased pore volume occurs in both prenatal and postnatal enamel, and they reported that thyroid hormones may affect the maturation of enamel. Hinrichs [17] observed enamel hypoplasia on the labial surfaces of the deciduous canine and molar teeth of a child with congenital hypothyroidism. Thyroid hormones are essential for skeletal growth and bone maturation. Childhood hypothyroidism results in growth retardation and delayed skeletal development. Delayed eruption can be observed in the primary and first permanent teeth of patients with congenital hypothyroidism [18]. In addition to the impact of congenital hypothyroidism on bone development, Schwarz *et al.* [19] showed that levels of thyroid stimulating hormone (TSH) and T3 are significantly associated with levels of phosphate and calcium, respectively, in thyroid disorder patients. In light of all of the evidence reported in these studies, we suggest that congenital hypothyroidism may also cause the formation of MIH during odontogenesis because of its effects on bone development and calcium balance in the body.

In the present study, patients with nephrotic syndrome were found to be at risk for the development of MIH. Hypocalcemia, decreased intestinal absorption of calcium, and calcium response inappropriate for parathormone, osteomalacia, and/or hyperparathyroidism were observed in patients with nephrotic syndrome. Furthermore, the use of corticosteroids is important for treating nephrotic syndrome [20]. It is also known that corticosteroids negatively influence bone and mineral metabolism [21]. This suggest that being at risk of MIH due to nephrotic syndrome may arise from the characteristics of the disease; it might be due to the effects of high dose corticosteroids used to treat the condition to support bone development.

In the present study, nephrotic syndrome, Wilms' tumor, and congenital hypothyroidism were found to play a role in the formation of MIH because they have an impact on bone mineral structure and calcium metabolism. Even though ameloblasts may comprise the entire enamel matrix of hypomineralized teeth, the deposition of calcium phosphate in the matrix can be impaired. Therefore, calcium-phosphate deficiency is reported to result in the hypomineralization of teeth [22]. In their study on hypomineralized first permanent molars, Jalevik *et al.* [15] demonstrated that the calcium level was very low in hypomineralized lesions; this indicates that impaired calcium metabolism may cause MIH in the ameloblasts. In their systematic review of the structural, mechanical, and chemical evaluation of molar-incisor hypomineralization-affected enamel, Elhennawy *et al.* [23] stated that MIH-affected enamel is significantly different from unaffected enamel, and that there is a decrease in the amount of calcium and phosphate in the MIH-lesion in comparison to unaffected enamel.

The statistical analysis results show that hemophilia A and celiac disease pose the least risk to developing MIH. Consistent with the present study, Sonbol *et al.* [24] found no difference between the hemophilia group and the control group in terms of developmental enamel defects. However, studies investigating the effects of celiac disease on enamel reported that enamel defects were most often observed in the permanent teeth in these patients, and that enamel defects were detected in patients suffering from celiac disease before the age of 7. Moreover, the formation mechanism of these defects has not yet been fully demonstrated, but immune insult is thought to be the main reason for the defects [25, 26]. Studies examining the effects of celiac disease on enamel defects used the enamel defect index developed by Aine [27] to evaluate the defects. This index classifies enamel defects, using a scale ranging from 0 to 4, according to discoloration, porosity, and deformation, and it does not differentiate between widespread or limited opacity. Therefore, the enamel defects observed in these studies cannot be evaluated in terms of MIH, and any comparison cannot be made between the results reported in those studies and the findings in present study.

In the present study, children with a systemic disease diagnosed before the age of 4 were evaluated to assess the effect of systemic diseases on the etiology of MIH. Avery and Chiego [28] and Nanci [29] reported that mineralization of the incisors and permanent first molars continued until the age of 4. Beentjes *et al.* [30] pointed out that it is important to take a patient's medical history up to the age of 4 in order to evaluate the etiology of hypomineralization. Additionally, it has been reported that the optimal age for MIH diagnosis is 8. This age is the most appropriate time for all teeth to be assessed because all four permanent first molars and eight permanent incisor teeth have emerged [4, 6, 8]. Therefore, children aged 8 and older were included in the present study.

The strength of this study is the assessment of children diagnosed with a systemic disease before the age of 4. The early diagnosis of the disease and the systemic effects that may occur in the course of the disease progression are not likely to affect the results of the study. However, when the study limitations were evaluated, the effects of complex treatment protocols with different agents, such as oncological therapies, were assessed to determine their impact on the development of MIH. Treatment protocols for systemic diseases need to be distinguished from MIH etiology using extensive animal and laboratory studies.

CONCLUSION

In the present study, children with systemic diseases were assessed on the basis of their medical records. The frequency of MIH was found to be higher in children with systemic diseases than in healthy children. For this reason, both dentists and medical doctors should have knowledge of the risk of developing MIH in children with systemic diseases. Preventive practices should be used to avoid widespread tooth destruction and tooth loss. Children in the risk group should be followed carefully.

ACKNOWLEDGMENT

This research was supported by an OMU-BAP Project (PYO. DIS.1904.11.006) at the Ondokuz Mayıs University and is a part of a doctoral thesis. We are very grateful to Asist. Prof. Serhat Arslan for his support in helping the statistical analyses of this research.

REFERENCES

1. Dahllöf G, Martens L. Children with chronic health conditions: implications for oral health. In: Koch G, Poulsen S, editors. *Pediatric dentistry: a clinical approach*. 2nd ed. Copenhagen: Blacwell publish; 2009. p. 315-29.
2. Cubukcu CE, Sevinir B, Ercan I. Disturbed dental development of permanent teeth in children with solid tumors and lymphomas. *Pediatr Blood Cancer*. 2012; 58(1): 80-4.
3. Noren JG, Alm J. Congenital hypothyroidism and changes in the enamel of deciduous teeth. *Acta Paediatr*. 1983; 72(4): 485-9.
4. Weerheijm KL. Molar incisor hypomineralisation (MIH). *Eur J Paediatr Dent*. 2003; 4(3): 114-20.
5. Martinović B, Ivanović M, Cvetković A, Todić J, Milojković Z, Pavlović J, et al. Prevalence, characteristics and severity of hypomineralization of the first permanent molars and incisors in children from the northern part of Kosovo and Metohija. *Srp Arh Celok Lek*. 2017; 145(7-8): 364-69.
6. Zawaideh FI, Al-Jundi SH, Al-Jaljoli MH. Molar incisor hypomineralisation: prevalence in Jordanian children and clinical characteristics. *Eur Arch Paediatr Dent*. 2011; 12(1): 31-6.
7. Kevrekidou A, Kosma I, Arapostathis K, Kotsanos N. Molar Incisor Hypomineralization of Eight- and 14-year-old Children: Prevalence, Severity, and Defect Characteristics. *Pediatr Dent*. 2015; 37(5): 455-61.
8. Jalevik B, Noren JG, Klingberg G, Barregard L. Etiologic factors influencing the prevalence of demarcated opacities in permanent first molars in a group of Swedish children. *Eur J Oral Sci*. 2001; 109(4): 230-4.
9. Serna C, Vicente A, Finke C, Ortiz AJ. Drugs related to the etiology of molar incisor hypomineralization: A systematic review. *J Am Dent Assoc*. 2016; 147(2): 120-30.
10. Alaluusua S. Aetiology of Molar-Incisor Hypomineralisation: A systematic review. *Eur Arch Paediatr Dent*. 2010; 11(2): 53-8.
11. Marec-Berard P, Azzi D, Chaux-Bodard AG, Lagrange H, Gourmet R, Bergeron C. Long-term effects of chemotherapy on dental status in children treated for nephroblastoma. *Pediatr Hematol Oncol*. 2005; 22(7): 581-8.
12. Hutton A, Bradwell M, English M, Chapple I. The oral health needs of children after treatment for a solid tumour or lymphoma. *Int J Paediatr Dent*. 2010; 20(1): 15-23.
13. Avsar A, Elli M, Darka O, Pinarli G. Long-term effects of chemotherapy on caries formation, dental development, and salivary factors in childhood cancer survivors. *Oral Surg Oral Med Oral Pathol Oral Radiol Endod*. 2007; 104(6): 781-9.
14. Othman F, Guo CY, Webber C, Atkinson SA, Barr RD. Osteopenia in survivors of Wilms tumor. *Int J Oncol*. 2002; 20(4): 827-33.
15. Jalevik B, Odelius H, Dietz W, Noren J. Secondary ion mass spectrometry and X-ray microanalysis of hypomineralized enamel in human permanent first molars. *Arch Oral Biol*. 2001; 46(3): 239-47.
16. Fagrell TG, Dietz W, Jalevik B, Noren JG. Chemical, mechanical and morphological properties of hypomineralized enamel of permanent first molars. *Acta Odontol Scan*. 2010; 68(4): 215-22.
17. Hinrichs EH, Jr. Dental changes in juvenile hypothyroidism. *J Dent Child*. 1966; 33(3): 167-73.
18. Little JW. Thyroid disorders. Part II: hypothyroidism and thyroiditis. *Oral Surg Oral Med Oral Pathol Oral Radiol Endod*. 2006; 102(2): 148-53.
19. Schwarz C, Leichtle AB, Arampatzis S, Fiedler GM, Zimmermann H, Exadaktylos AK, Lindner G. Thyroid function and serum electrolytes: does an association really exist? *Swiss Med Wkly*. 2012; 17: 142.
20. Filler G. Treatment of nephrotic syndrome in children and controlled trials. *Nephrol Dial Transplant*. 2003; 18(6): 75-8.
21. Malluche HH, Monier-Faugere MC, Herberth J. Bone disease after renal transplantation. *Nat Rev Nephrol*. 2010; 6(1): 32-40.
22. Seow WK. Clinical diagnosis of enamel defects: pitfalls and practical guidelines. In *Dent J*. 1997; 47(3): 173-82.
23. Elhennawy K, Manton DJ, Crombie F, Zaslansky P, Radlanski RJ, Jost-Brinkmann PG, Schwendicke F. Structural, mechanical and chemical evaluation of molar-incisor hypomineralization-affected enamel: A systematic review. *Arch Oral Biol*. 2017; 83: 272-81.

24. Sonbol H, Pelargidou M, Lucas VS, Gelbier MJ, Mason C, Roberts GJ. Dental health indices and caries-related microflora in children with severe haemophilia. *Haemophilia*. 2001; 7(5): 468–74.
25. Pastore L, Carroccio A, Compilato D, Panzarella V, Serpico R, Lo Muzio L. Oral manifestations of celiac disease. *J Clin Gastroenterol*. 2008; 42(3): 224–32.
26. Farmakis E, Puntis JW, Toumba KJ. Enamel defects in children with coeliac disease. *Eur J Paediatr Dent*. 2005; 6(3): 129–32.
27. Aine L. Dental enamel defects and dental maturity in children and adolescents with coeliac disease. *Proc Finn Dent Soc* 1986; 82(3): 1–71.
28. Avery JK, Chiego DJ. Eruption and shedding of teeth. In: Avery JK, Chiego DJ, editors. *Essential of oral histology and embriology a clinical approach*. 3rd ed. Canada: Mosby; 2006. p. 81–96.
29. Nanci A. Physiologic Tooth Movement: Eruption and Shedding. Nanci A, editor. *Ten Cate's oral histology: development, structure, and function*. 8th Ed. St Louis: MO Mosby; 2013. p. 233–52.
30. Beentjes VE, Weerheijm KL, Groen H. Factors involved in the aetiology of molar-incisor hypomineralisation (MIH). *Eur J Paediatr Dent*. 2002; 3(1): 9–13.

Paper accepted