

CASE REPORT / ПРИКАЗ БОЛЕСНИКА

Blunt liver trauma with concomitant injuries to the abdominal viscus – a dilemma for trauma surgeons

Yi Dong, Yuyang Guo, Yuxing Jiang, Wenfei Liu, Yong Fang

The People's Liberation Army No. 305 Hospital, Department of General Surgery, Beijing, China

**SUMMARY**

Introduction Blunt liver trauma is predominantly managed non-surgically, yet the optimal treatment and timing for addressing its late complications remain uncertain. This study aims to evaluate treatment approaches and outcomes for blunt liver trauma with concomitant abdominal visceral injuries.

Case Outline We present two cases of adult males who sustained severe liver and other organ injuries due to road traffic accidents. Both patients underwent comprehensive treatment, including urgent laparotomy. The first case resulted in severe complications and eventual mortality, while the second case had a favorable outcome with conservative management of the liver hematoma.

Conclusion Retaining blood clots around the liver wound during surgical intervention may enhance hemostasis and reduce infection risks. Further controlled studies with larger samples are necessary to validate these findings.

Keywords: blunt liver trauma; concomitant injury; operative intervention; non-operative management; urgent laparotomy

INTRODUCTION

Blunt liver trauma is primarily caused by shear stress resulting from rapid deceleration, commonly seen in road traffic accidents and falls. Liver rupture accounts for 15–20% of all abdominal injuries, with right liver rupture being more prevalent than the left [1]. A study involving 3196 patients with liver trauma identified higher mortality risks in individuals over 64 years, pedestrians involved in motor vehicle accidents, and those with renal failure, liver cirrhosis, or concurrent head, chest, or other abdominal injuries [2]. Although non-surgical management is increasingly adopted, the optimal intraoperative strategy for patients requiring laparotomy, particularly those with concomitant abdominal visceral injuries, remains controversial. A critical debate centers on whether to retain or remove blood clots surrounding liver wounds during surgery. This study specifically examines the hypothesis that preserving perilesional blood clots in blunt liver trauma with concurrent visceral injuries may enhance hemostasis and reduce postoperative infectious risks, thereby aligning with damage control principles.

To contextualize this hypothesis, a retrospective analysis of 450 patients with liver trauma revealed that 72% with closed liver injuries received non-surgical treatment [3]. However, surgical interventions remain indispensable for hemodynamically unstable cases or those with concomitant injuries [4]. The existing literature lacks a consensus on clot retention as a deliberate hemostatic measure during laparotomy, particularly in complex trauma scenarios. Herein, we present two contrasting cases of

blunt liver trauma with abdominal visceral injuries, focusing on the role of intraoperative clot management in outcomes.

CASE REPORTS**Case 1**

A 43-year-old man was injured in a road traffic accident on August 12, 2018, and was admitted to a local hospital's Emergency Department due to severe abdominal pain and fractures of the right ribs. He underwent urgent laparotomy four hours post-accident for diffuse peritonitis. Intraoperatively, a 5 × 3 cm laceration in the small intestine mesentery with venous bleeding and a ruptured sub-capsular liver hematoma with multiple parenchymal disruptions (largest approximately 5 cm) in the right lobe were identified. Massive intra-peritoneal hemorrhage (approximately 1800 mL) was evacuated. After repairing the mesenteric laceration, capillary bleeding persisted at the liver wound despite packing, necessitating hepatorrhaphy. The surgery lasted five hours, with blood loss exceeding 2150 mL, which was managed with six units of erythrocyte suspension and 400 mL of plasma.

Postoperatively, the patient remained unconscious and was intubated due to dyspnea. Two days later, urine output decreased to 200 mL/day, with elevated creatinine and transaminase levels. Seven days post-surgery, he developed hyperpyrexia despite continuous renal replacement therapy and meropenem prophylaxis, leading to his transfer to our institute on August 22, 2018. Upon admission,

Received • Примљено:

December 10, 2024

Revised • Ревизија:

April 7, 2025

Accepted • Прихваћено:

April 19, 2025

Online first: April 29, 2025**Correspondence to:**

Yong FANG
The People's Liberation Army No. 305 Hospital
Department of General Surgery
Wenjin Street 13
Xicheng District
100017 Beijing
China
yongfang288@163.com

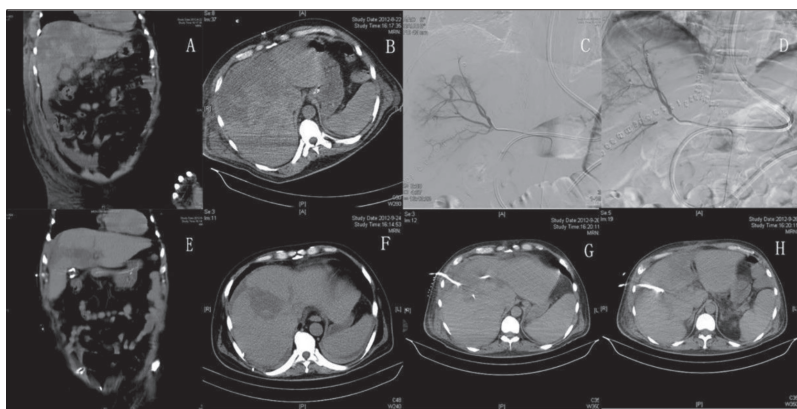


Figure 1. Case 1. A, B – a computed tomography (CT) scan of the abdomen taken 10 days after hepatorrhaphy; C, D – a hepatic arteriography showing active bleeding from the hepatic artery; the angioembolisation contributed to a lack of contrast extravasation from the artery; E, F – a CT scan of the abdomen taken 43 days after hepatorrhaphy, demonstrating that several abscess cavities and necrosis areas had formed in the liver; G, H – the abscess cavities were managed by percutaneous catheter drainage

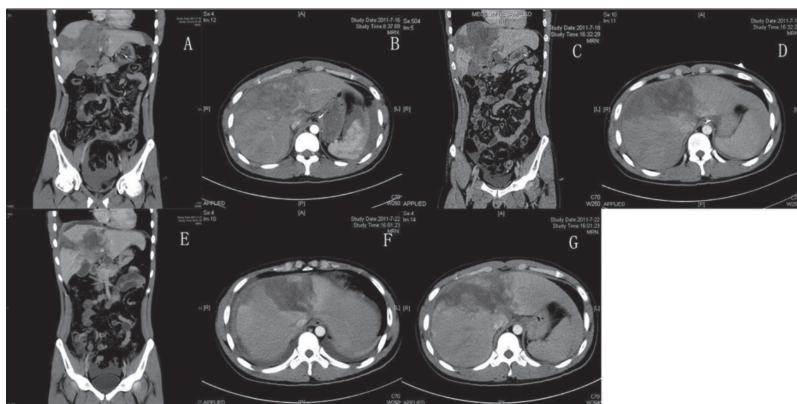


Figure 2. Case 2. A, B – a computed tomography (CT) scan of the abdomen taken four hours after injury demonstrated liver rupture and pulmonary contusions; C, D – a repeat CT scan of the abdomen taken two days after injury; E, F, G – a repeat CT scan of the abdomen taken six days after injury demonstrated that the hematoma in the liver had been gradually reabsorbed with no progression of the lesion

abdominal computed tomography (CT) scans (Figure 1A and 1B) indicated severe sepsis (white blood count: $37.8 \times 10^9/L$; procalcitonin: 78.83 ng/mL; creatinine: 712 $\mu\text{mol/L}$; urea nitrogen: 58.4 mmol/L; total bilirubin: 174.7 $\mu\text{mol/L}$).

Hepatic arteriography on the sixth day post-admission revealed active hepatic artery bleeding, which was embolized using a spring coil (5 mm \times 5 cm), effectively stopping contrast extravasation (Figure 1C and 1D). Subsequently, the patient experienced upper gastrointestinal bleeding, evidenced by 700 mL of tarry stool and 300 mL of dark red liquid via a nasogastric tube. Urgent arteriography identified bleeding from a right gastric artery branch, but embolization was unfeasible. Gastroscopy confirmed an actively bleeding duodenal ulcer, which was managed endoscopically.

The patient's recovery was marred by relapse, gastrointestinal bleeding, and severe sepsis. Despite no active bleeding on angiography, daily blood product transfusions were required. A repeat CT 43 days post-hepatorrhaphy showed multiple liver abscesses and necrotic areas (Figure 1E and 1F), which were managed by percutaneous catheter drainage (Figure 1G and 1H). On September 29, 2018, the patient developed a 40°C fever, excreted 3000 mL of dark,

bloody stool and experienced a sharp blood pressure drop, leading to ventricular flutter and subsequent death despite resuscitation efforts.

Case 2

A 42-year-old man was involved in an automobile crash on July 16, 2020, and was admitted to our Emergency Department four hours later with multiple abdominal and waist injuries. He presented with abdominal pain, lower limb weakness, retrograde amnesia and diffuse peritonitis. Abdominal CT scans revealed liver rupture, pulmonary contusions and a transverse lumbar vertebra fracture (Figure 2A and 2B). Despite decompression and an enema, the pain persisted. Peritoneal aspiration retrieved over 10 mL of gross blood, prompting exploratory laparotomy.

Intraoperatively, there was a massive intra-peritoneal hemorrhage (> 1600 mL), a 7 cm parenchymal disruption on the liver's lower edge and a 2 \times 2 cm liver capsule laceration. Erythema and blood clots surrounded the liver wounds without pulsatile bleeding. Additionally, a 1 cm duodenal laceration with intestinal content leakage and a 3 \times 4 cm ileocecal mesentery laceration with venous bleeding were identified. After evacuating the hemorrhage, the duodenal and mesenteric lacerations were repaired. Blood clots around the liver wounds were retained to control bleeding. The surgery lasted two hours, with a blood loss of 2150 mL.

Postoperatively, the patient received microbial prophylaxis and hemostasis treatment.

Repeat CT scans on July 18 and July 22, 2020, showed gradual absorption of the liver hematoma without lesion progression (Figure 2C–G). The patient recovered well (red blood count: $3.73 \times 10^{12}/L$; hemoglobin: 113 g/L) and was discharged on July 22, 2020. Follow-up via telephone indicated normal liver function without fever or jaundice. A recommended repeat abdominal CT was declined due to economic reasons.

Ethics: This study was conducted in accordance with the Declaration of Helsinki. It was approved by the Ethics Committee of The People's Liberation Army No. 305 Hospital (ethical approval number: KYLL-SPJ-2024-04). Written informed consent was obtained from all participants.

DISCUSSION

This study presents two cases of severe blunt liver injury with concomitant abdominal visceral injuries resulting from road traffic accidents, both accompanied by diffuse peritonitis. Both patients underwent exploratory

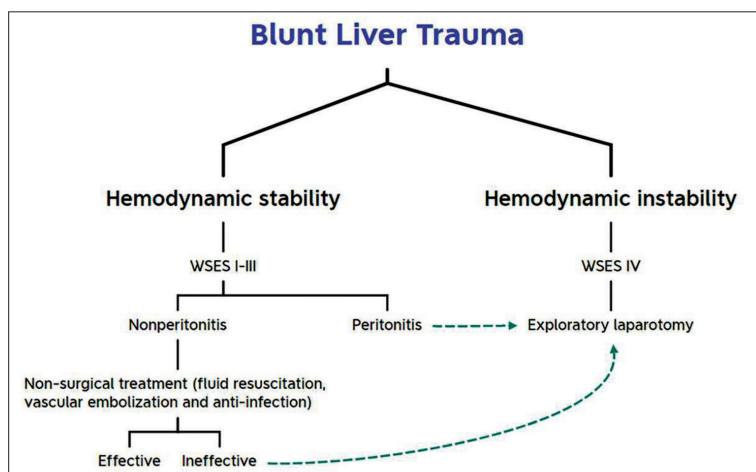


Figure 3. The clinical practice chart of blunt liver trauma; WSES – the 2020 World Society of Emergency Surgery guidelines

laparotomy, revealing mesenteric lacerations. In the first case, the removal of blood clots around the liver led to persistent bleeding, severe sepsis, gastrointestinal hemorrhage, and eventual death. In contrast, in the second case, blood clots around the liver were retained, resulting in hematoma absorption, and patient recovery. This suggests that preserving blood clots around liver wounds may enhance hemostasis and reduce infection risks.

The liver's rich blood supply and complex structure make it susceptible to severe injuries, often leading to hemorrhagic shock and biliary peritonitis with high mortality and complication rates. Cavernous hemangioma is the most common benign hepatic tumor, and trauma can trigger bleeding from these lesions [5]. Patients with trauma and massive bleeding are at risk of metabolic acidosis, hypothermia, and coagulopathy, necessitating fluid resuscitation, blood transfusion, and correction of coagulopathies [6]. Damage control surgery involving sutures and tamponades, along with resuscitation, improves survival rates despite the high mortality [7].

Retained perilesional blood clots in blunt liver trauma may confer protection through four mechanisms:

- 1) Hemostatic scaffolding: clots provide a scaffold for platelet aggregation and fibrin deposition, enhancing mechanical compression;
- 2) Mechanical barrier: clots prevent bacterial translocation from the gut;
- 3) Inflammatory modulation: clots sequester pro-inflammatory cytokines (IL-6/TNF- α) and release anti-inflammatory mediators (TGF- β);
- 4) Tissue repair: fibrin matrices store growth factors (VEGF/PDGF), promoting angiogenesis [8, 9].

These mechanisms align with the 2020 World Society of Emergency Surgery (WSES) guidelines, supporting clot retention as a damage control strategy [10].

Most liver injuries from motor vehicle accidents can be managed non-surgically, with early vascular embolization being crucial in selected cases [11]. However, blunt liver trauma with additional abdominal visceral injuries requires careful consideration. According to the 2018 American Association for the Surgery of Trauma liver injury scale,

emergency laparotomy is indicated for similar intraperitoneal hemorrhages and liver injury classifications (grade IV) [12]. Patients with hemodynamically stable blunt hepatic trauma without other surgical indications may initially receive non-surgical treatment, reserving exploratory laparotomy for those with hemodynamic instability, peritonitis or failure of conservative management [13] (Figure 3).

Surgical techniques for liver trauma include perihepatic packing, liver repair, hepatectomy, and selective hepatic artery ligation [14]. However, these interventions can increase complication rates, such as surgical urinary wounds, respiratory tract sepsis, and intra-abdominal abscesses [15]. Selective non-surgical strategies and endovascular interventions are becoming more prevalent,

with non-surgical treatments showing lower or comparable complication rates [16]. Nonetheless, surgical interventions remain necessary for controlling major bleeding sites. The 2020 WSES guidelines explicitly recommend clot retention as part of damage control surgery (Grade 1B), emphasizing its role in hemostasis and infection prevention [10].

Non-surgical treatment complications include persistent bleeding, biliary hemorrhage, bile leakage, and severe sepsis [17]. Successful non-surgical management has an 85–99% success rate, with hepatic convergence and bile leakage being the most common complications [18]. Biliary leakage is a significant cause of sepsis in patients with blunt liver injury and can be managed with closed suction tubes, percutaneous drainage, cholangiography, or endoscopic stenting [19]. Major liver injuries and progressive coagulopathy are frequent indications for damage control surgery, necessitating precise surgical judgment and meticulous open abdomen management to limit morbidity [20].

In this case series, we observed that retaining blood clots around liver wounds during surgical intervention in two hemodynamically distinct scenarios appeared to enhance hemostasis and reduce infection risks. The contrasting outcomes between Case 1 (clot removal) and Case 2 (clot retention) suggest a potential biological rationale for clot preservation, particularly in damage control surgery for complex trauma. However, this hypothesis requires validation through prospective multi-center studies with standardized protocols and larger cohorts. Until such evidence emerges, trauma surgeons should weigh clot retention strategies against individual patient risks, guided by real-time hemodynamic status and institutional expertise.

ACKNOWLEDGMENT

Funding: This research received funding from the Independent Research Fund of The People's Liberation Army No. 305 Hospital (NO. 24ZZJLW-006).

Conflict of Interest: None declared.

REFERENCES

1. Le ACM, Bohlín T, Grønvald L, Rognerud ØH, Jørgensen JJ, Landquist M. Sprukket lever [Ruptured liver]. Tidsskr Nor Lægeforen. 2023;143(8). Norwegian. [DOI: 10.4045/tidsskr.22.0805] [PMID: 37254990]
2. Chien LC, Lo SS, Yeh SY. Incidence of liver trauma and relative risk factors for mortality: a population-based study. J Chin Med Assoc. 2013;76(10):576–82. [DOI: 10.1016/j.jcma.2013.06.004] [PMID: 23890836]
3. Fischer NJ. Mortality following severe liver trauma is declining at Auckland City Hospital: a 14-year experience, 2006–2020. N Z Med J. 2021;134(1540):16–24. [PMID: 34482385]
4. Thomas MN, Whaba R, Datta RR, Bunck AC, Stippel DL, Bruns CJ. Management und Versorgung von Leberverletzungen nach stumpfem Bauchtrauma [Management and treatment of liver injuries after blunt abdominal trauma]. Chirurgie (Heidelberg). 2023;94(8):669–74. German. [DOI: 10.1007/s00104-023-01858-1] [PMID: 37142798]
5. Bioulac-Sage P, Laumonier H, Laurent C, Blanc JF, Balabaud C. Benign and malignant vascular tumors of the liver in adults. Semin Liver Dis. 2008;28(3):302–14. [DOI: 10.1055/s-0028-1085098] [PMID: 18814083]
6. Cirocchi R, Montedori A, Farinella E, Bonacini I, Tagliabue L, Abraha I. Damage control surgery for abdominal trauma. Cochrane Database Syst Rev. 2013;2013(3):CD007438. [DOI: 10.1002/14651858.CD007438.pub3] [PMID: 23543551]
7. Iaselli F, Mazzei MA, Firetto C, D'Elia D, Squitieri NC, Biondetti PR, et al. Bowel and mesenteric injuries from blunt abdominal trauma: a review. Radiol Med. 2015;120(1):21–32. [DOI: 10.1007/s11547-014-0487-8] [PMID: 25572542]
8. El-Menyar A, Mekkodathil A, Al-Ansari A, Asim M, Elmenyar E, Rizoli S, et al. Platelet-Lymphocyte and Neutrophil-Lymphocyte Ratio for Prediction of Hospital Outcomes in Patients with Abdominal Trauma. Biomed Res Int. 2022;2022:5374419. [DOI: 10.1155/2022/5374419] [PMID: 35178450]
9. Doudakmanis C, Bouliaris K, Kolla C, Efthimiou M, Koukoulis GD. Bacterial translocation in patients undergoing major gastrointestinal surgery and its role in postoperative sepsis. World J Gastrointest Pathophysiol. 2021;12(6):106–14. [DOI: 10.4291/wjgp.v12.i6.106] [PMID: 34877025]
10. Cocolini F, Coimbra R, Ordonez C, Kluger Y, Vega F, Moore EE, et al. Liver trauma: WSES 2020 guidelines. World J Emerg Surg. 2020;15(1):24. [DOI: 10.1186/s13017-020-00302-7] [PMID: 32228707]
11. Wongweerakit O, Akaraborworn O, Sangthong B, Thongkhao K. Acute portal vein thrombosis in an isolated, blunt, minor liver injury near the porta hepatis. Chin J Traumatol. 2025;28(1):76–8. [DOI: 10.1016/j.cjtee.2023.09.003] [PMID: 37838579]
12. Vyčítal O, Horský O, Rosendorf J, Liška V, Skalický T, Třeška V. Treatment of liver injuries at the Trauma Centre of the University Hospital in Pilsen. Rozhl Chir. 2019 Winter;98(12):488–91. English. [DOI: 10.33699/PIS.2019.98.12.488-491] [PMID: 31958962]
13. Martellotto S, Melot C, Raux M, Chereau N, Menegaux F. Depacked patients who underwent a shortened perihepatic packing for severe blunt liver trauma have a high survival rate: 20 years of experience in a level I trauma center. Surgeon. 2022;20(3):e20–e25. [DOI: 10.1016/j.surge.2021.04.012] [PMID: 34154925]
14. Leenellett E, Rieves A. Occult Abdominal Trauma. Emerg Med Clin North Am. 2021;39(4):795–806. [DOI: 10.1016/j.emc.2021.07.009] [PMID: 34600638]
15. Cartu D, Margaritescu D, Sandulescu S, Bratiloveanu T, Ramboiu S, Bica M, et al. Nonoperative Treatment of Abdominal Trauma Involving Liver and Spleen. Chirurgia (Bucur). 2021;116(6):689–99. [DOI: 10.21614/chirurgia.116.6.689] [PMID: 34967714]
16. Schembari E, Sofia M, Latteri S, Pesce A, Palumbo V, Mannino M, et al. Blunt liver trauma: effectiveness and evolution of non-operative management (NOM) in 145 consecutive cases. Updates Surg. 2020;72(4):1065–71. [DOI: 10.1007/s13304-020-00861-z] [PMID: 32851597]
17. Nguyen PD, Nahmias J, Aryan N, Samuels JM, Cripps M, Carmichael H, et al. Observation-first versus angioembolization-first approach in stable patients with blunt liver trauma: A WTA multicenter study. J Trauma Acute Care Surg. 2024;97(5):764–9. [DOI: 10.1097/TA.0000000000004372] [PMID: 39443838]
18. Virdis F, Podda M, Di Saverio S, Kumar J, Bini R, Pilasi C, et al. Clinical outcomes of non-operative management and clinical observation in non-angioembolised hepatic trauma: A systematic review of the literature. Chin J Traumatol. 2022;25(5):257–63. [DOI: 10.1016/j.cjtee.2022.04.004] [PMID: 35487854]
19. Mehta N, Babu S, Venugopal K. An experience with blunt abdominal trauma: evaluation, management and outcome. Clin Pract. 2014;4(2):599. [DOI: 10.4081/cp.2014.599] [PMID: 25332759]
20. Straciere LD, Scarpellini S. Hepatic injury. Acta Cir Bras. 2006;21 Suppl 1:85–8. [DOI: 10.1590/s0102-86502006000700019] [PMID: 17013521]

Тупа повреда јетре са пратећим повредама абдоминалних органа – дилема за трауматолошке хирурге

Ли Донг, Јујанг Гуо, Јусјинг Ђанг, Венфеј Љу, Јонг Фанг

305. болница Народноослободилачке армије, Одељење за општу хирургију, Пекинг, Кина

САЖЕТАК

Увод Тупа повреда јетре претежно се лечи нехируршки, али оптималан приступ лечењу и време решавања њених касних компликација нису јасно дефинисани. Циљ ове студије је да процени приступе лечењу и исходе тупе повреде јетре код болесника са истовременим повредама других абдоминалних органа.

Прикази болесника Приказујемо два случаја одраслих мушкараца који су у саобраћајним незгодама задобили тешке повреде јетре и других органа. Оба пацијента су подвргнута

опсежном лечењу, укључујући хитну лапаротомију. Први болесник је преминуо услед тешких компликација, док је код другог конзервативно лечење хематома јетре довело до повољног исхода.

Закључак Остављање крвних угрушака око ране на јетри током хируршке интервенције може побољшати хомеостазу и смањити ризик од инфекције. Потребна су даља истраживања са већим узорцима за потврду ових налаза.

Кључне речи: тупа повреда јетре; пратеће повреде; оперативно лечење; неоперативно лечење; хитна лапаротомија