

REVIEW OF LITERATURE / ПРЕГЛЕД ЛИТЕРАТУРЕ

Optical coherent tomography with angiography in glaucoma

Ivan Marjanović^{1,2}, Vesna Marić^{2,1}, Marija Božić^{1,2}¹University of Belgrade, Faculty of Medicine, Belgrade, Serbia;²University Clinical Center of Serbia, University Eye Hospital, Belgrade, Serbia**SUMMARY**

Optical coherence tomography with angiography (OCT-A) is a non-invasive imaging technique that enables three-dimensional visualization of perfusion through the vascular network of the retina and choroid. The possibilities of OCT-A for glaucomatologists will expand in the near future. The possibility of detecting and monitoring glaucoma with this technology will also be expanded. All of these systems will undoubtedly offer software updates, making it easier for examiners to use the device itself, and thus monitor the disease. OCT-A represents the future in the diagnosis of retinal diseases and glaucoma.

Keywords: glaucoma; optical coherence tomography; angiography

INTRODUCTION

Optical coherence tomography with angiography (OCT-A) is a non-invasive imaging technique that enables three-dimensional visualization of perfusion through the vascular network of the retina and choroid.

Unlike standard OCT, OCT-A analyzes not only the intensity of reflected light, but also the temporal changes in reflection caused by the movement of particles, such as erythrocytes circulating through blood vessels [1]. These changes are detected in OCT signals as repeated freezing of OCT images of each part of the retina, thus forming a contrasting image between the blood vessel through which the blood flows and the static environment that makes up the surrounding tissue (Figure 1).

To obtain such data, several algorithms have been developed by different manufacturers, making the images different in interpretation in order to distinguish them. Each OCT-A apparatus has its own algorithm, which is based on special experiential protocols, which are made to offer optimal information for appropriate

clinical indications. Such variations in the interpretation of different devices can lead to different interpretations of clinical diagnoses [2, 3].

Monitoring changes in glaucoma today is easier and simpler than in the past. A number of new imaging techniques make this easier. OCT-A is just one such imaging technique. It is easy to monitor blood flow in the retina, while providing insight into the condition of ganglion cells that can be damaged by the disease itself. The popularity of using OCT-A to monitor changes in the optic nerve, and thus to monitor glaucoma changes, is growing. OCT-A is useful in assessing optic nerve perfusion in glaucoma eyes, since the density of peripapillary and macular blood vessels is impaired in patients with preperimetric glaucoma. This gives enthusiasm about the role of OCT-A in the detection of early changes in glaucoma. Quantitative data on retinal circulation have proven useful in analyzing the metabolic activity of the inner layers of the retina, and thus monitoring the disease itself. OCT-A also serves as a useful machine in monitoring blood flow (retrobulbar circulation) and detecting disease mechanisms in

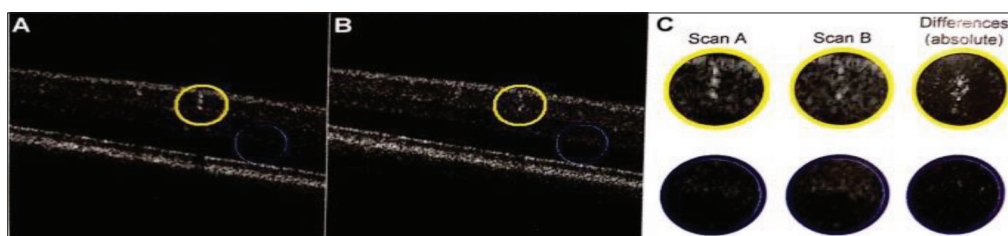


Figure 1. Display of the change in the intensity of the standard optical coherence tomography (OCT) signal and the optical coherence tomography with angiography (OCT-A) signal, as a function of the flow time (private collection); example of how the OCT signal intensity changes over time, after bulk motion correction; **A, B:** structural OCT images were acquired with a time difference of 8 ms; the location of a larger blood vessel (yellow circle) and of static tissue (blue circle) is indicated in both images; **C:** upon magnification of these areas and calculation of the differences, larger OCT signal changes can be seen within the blood vessel when compared with the static tissue; note that this figure is not showing the SPECTRALIS OCTA algorithm results, but just the absolute differences between two single OCT scans (A and B) for illustration

Received • Примљено:

February 11, 2023

Revised • Ревизија:

October 10, 2023

Accepted • Прихваћено:

October 11, 2023

Online first: November 8, 2023**Correspondence to:**

Marija BOŽIĆ
 Pasterova 2
 11000 Belgrade
 Serbia
ammiilovic@gmail.com

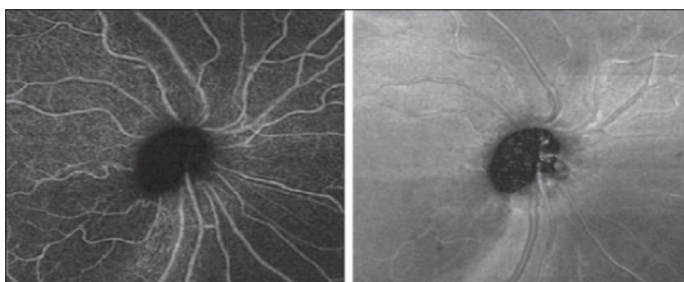

Figure 2. Optical coherence tomography with angiography (OCT-A) (left) and *en face* image (right) of a patient with glaucoma, in whom there is a lower temporal loss of the nerve fiber layer, with an anatomical correlation with a decrease in vascular density on OCT-A (private collection)

glaucoma without elevated intraocular pressure (normal-tension glaucoma) (Figure 2).

BLOOD FLOW AND GLAUCOMA

The very idea of detecting and monitoring glaucoma changes by measuring blood flow is not new. For decades, measuring retrobulbar circulation with various methods has been challenging in diagnosing and monitoring glaucoma. Fluorescein angiography, in glaucoma eyes, showed decreased fluorescence and delayed filling of blood vessels. Because it is invasive and only partially quantitative, fluorescein angiography is not practical for routine glaucoma monitoring. Other techniques, such as ultrasound Doppler, Doppler OCT, laser Doppler flowmetry, and laser speckle flowgraphy, have also shown the reduction in retinal and optic nerve flow in glaucoma. However, these techniques have high variability of measurement and are more suitable for detecting changes/differences between larger groups of patients than individually. OCT-A differs from the aforementioned techniques in two important aspects. Firstly, OCT-A is a non-invasive imaging technique. Secondly, OCT-A can measure the density of blood vessels with a high possibility of recurrence and renewal, i.e. reproductions of the measurement itself. It lasts only a few seconds and can be repeated at each patient checkup. Measurements are accurate and can be used to diagnose and monitor the disease.

HOW DOES OCT WORK?

OCT-A simply detects blood vessels to the level of capillaries. OCT-A software compares sequential frames of OCT images in cross section at the same position, looking for signal fluctuations that indicate blood flow. We have developed an algorithm called split-spectrum amplitude-decorrelation angiography – SSADA for short – which is so efficient that only two frames are needed to accurately identify capillaries [4]. This efficient algorithm, along with improvements in the Fourier velocity of the OCT domain, made OCT-A clinically feasible. As OCT-A senses movement, it is susceptible to artifacts created by eye movement, such as micro-saccades, eye pulsations, and eye twitches. Therefore, the production of high-quality OCT-A images requires special algorithms that monitor, process

and reproduce this. These technical requirements have encouraged the rapid advancement of commercial OCT technology on the hardware and software fronts.

HOW TO DIAGNOSE OCT-A GLAUCOMA

In a 2014 OCT-A study measuring blood flow in glaucoma patients, Jia et al. found that glaucoma patients had reduced capillary density and blood flow index, at the level of disc superficial tissue and at the level of lamina cribrosa [5].

Elevated IOP may affect perfusion through the head of the optic nerve and deficiency of blood flow through the lamina cribrosa. The head of the optic nerve is not an ideal target for OCT-A imaging, given the shadow created by large blood vessels and the variability of the geometry of the rim of the disc and blood vessels. The focus of the imaging, for ideal imaging for the diagnosis of glaucoma, has been shifted to the peripapillary retina and macula [6, 7]. In both regions, the density of blood vessels showed precision and accuracy! In addition, the density of blood vessels showed a good correlation with the parameters of the visual field, even better than the correlation with the structural parameters of the OCT, such as the thickness of the layer of nerve fibers. It is important to note that a scan of sufficient size is necessary for the OCT-A image to have a useful diagnostic value. For the peripapillary region, for example, 4.5×4.5 mm scans have the best diagnostic usability. For the macular region, the most accurate is the 6×6 mm scan (Figure 3). There are studies that used smaller OCT-A scans, of 3 or 4 mm, but the accuracy was poorer, which is to be expected, since glaucoma first affects the peripheral parts of the macula.

BLOOD FLOW OR BLOOD VESSEL DENSITY?

In functional glaucoma tests, blood flow volume was first examined by Doppler OCT [8], and later by flow index by OCT-A [5]. The reproducibility of these measurements was poor. The reason may lie in the fact that the speed and volume of blood flow are affected by variations in the physiological state of the patient. These measurements have been shown to be influenced by the oxygen concentration in the inhaled gas mixture and visual stimulation. There are many other factors that affect blood flow. The reproducibility of measuring blood vessel density with OCT-A is excellent. Density is measured by direct (*en face*) reading of OCT-A images of appropriate anatomical structure. Maximum blood flow within the blood vessel itself converts a three-dimensional OCT-A finding into a two-dimensional direct (*en face*) angiogram. Blood vessel density is defined by the percentage occupied by vascular pixels (pixels with a higher flow signal relative to the non-vascular background) in the corresponding area in the *en face* angiogram. Large blood vessels can be ruled out if we want to measure the density of capillaries. For the diagnosis and monitoring of glaucoma, the density of blood vessels and capillaries is ideal.

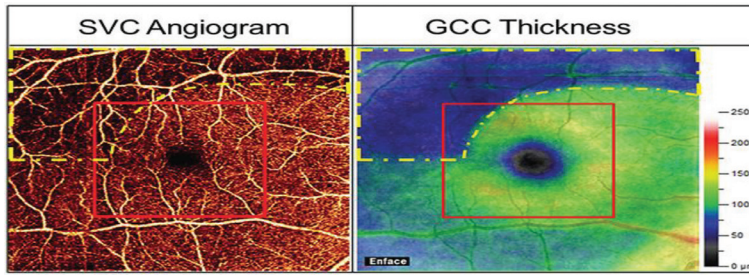


Figure 3. Superficial vascular complex (SVC) 6 × 6 Optical coherence tomography with angiography (left) and 6 × 6 mm layer of ganglion cell layer (GCL) thickness (right), in a typical glaucoma eye; glaucoma damage (yellow dashed line) is mostly outside the central 3 × 3 mm (marked with a red square); obviously, a larger area needs to be scanned for early detection of glaucoma damage (private collection)

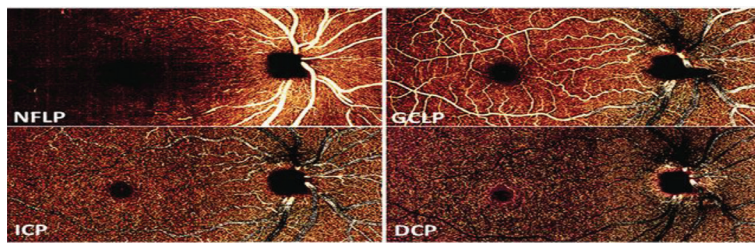


Figure 4. En face optical coherence tomography with angiography images of four retinal vascular plexuses, in the right eye, in a healthy person; nerve fiber layer plexus (NFLP) and ganglion cell layer plexus (GCLP) form the superficial vascular complex, which contains both large blood vessels and capillaries; intermediate capillary plexus (ICP) and deep capillary plexus (DCP) form a deep vascular complex, which is primarily formed by capillaries (private collection)

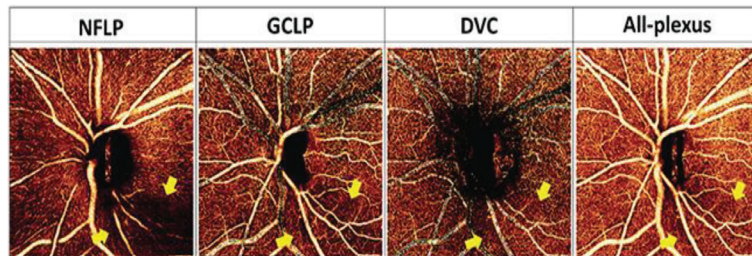


Figure 5. Image of a glaucoma patient, AngioVue optical coherence tomography with angiography apparatus (Optovue, USA), using a 4.5 × 4.5 mm AngioDisc scan; drop capillary loss, marked by arrows, can be more easily detected in the nerve fiber layer plexus (NFLP) than in the ganglion cell layer plexus (GCLP) and all plexuses (ALL-plexus), while the deep vascular complex is unaffected (private collection)

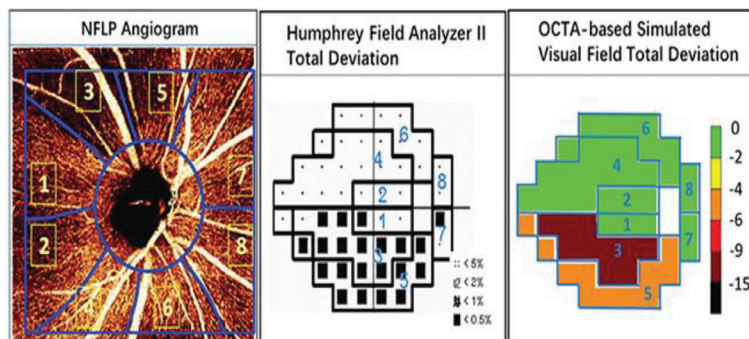


Figure 6. In eyes with moderately advanced glaucoma, en face optical coherence tomography with angiography (OCT-A) nerve fiber layer plexus (NFLP) and visual field map are divided into eight corresponding sectors, according to the Garway-Heat scheme; NFLP angiogram shows loss of capillaries (dropout) in the upper temporal part; on the OCT-A simulated field of view deviation map, sectors 3 and 5 show medium to advanced defects, which correlate with defects in the standard field of view (private collection)

WHICH VASCULAR PLEXUSES ARE AFFECTED

Earlier studies had limitations in the detection of blood vessels, since the shadow of the superficial ones blocked the deeper blood vessels. This has been overcome by developing an algorithm that distinguishes the *in situ* from the projected flow. OCT-A angiography, using this algorithm, can distinguish up to four vascular plexuses on the retina [9] (Figure 4). In the peripapillary region, glaucoma primarily affects the plexus of the retinal nerve fiber layer (NFLP), which feeds the retinal nerve fiber layer (NFL) (Figure 5). In the macula, glaucoma also affects the NFLP and the plexus of the ganglion cell layer (GCLP), which feeds the ganglion cell layer (GCL). Together, NFLP and GCLP form a superficial vascular complex. Focusing on peripapillary NFLP and macular superficial vascular complex (SVC) increases the visualization of glaucomatous lesions and improves diagnostic accuracy. It is shown that the density of macular SVC blood vessels has better diagnostic accuracy than the density of all plexuses in the retina [10].

WHY USE OCT-A?

According to the IRIS registry of the American Academy of Ophthalmology (AAO), OCT has already surpassed KVP in annual use for the diagnosis and monitoring of glaucoma. OCT monitoring of peripapillary NFL and macular ganglion cell complex are part of the standard examination in glaucoma. Measurement of OCT-A peripapillary NFLP vascular density is highly related to NFL thickness, and macular SVC density is highly related to GCC thickness. OCT plays a role in both early and late stages of glaucoma. Two clinical studies have shown that OCT-A can detect early preperimetric glaucoma better than structural OCT [11, 12]. Because OCT-A detects both dysfunctional (sick) and lost (dead) ganglion cells, while structural OCT detects only lost ganglion cells. In the early stages of glaucoma, diseased, dysfunctional ganglion cells have a reduced metabolism, which leads to a reduced density of capillaries. This reduced density is detected by OCTA. Prior to apoptosis, these ganglion cells lead to thinning of the NFL and GCC,

which can be detected by structural OCT. By adding OCT-A to the diagnosis, we can detect glaucoma earlier and start treatment on time. Other studies have shown

that OCT-A parameters correlate better with visual field parameters compared to structural OCT parameters such as NFL thickness [6, 12]. This is partly due to the reduction of the “floor effect” by OCT-A measurements. The floor effect describes the fact that, although NFL thickness correlates with mean field deviation in early glaucoma, it shows low values in moderate glaucoma and then no longer decreases in advanced glaucoma. This limits the usefulness of NFL thickness for monitoring the progression of glaucoma in the moderate and advanced stages [13]. Although the density of blood vessels also eventually reaches the bottom, it appears to do so only in advanced glaucoma. OCT-A has the potential to improve glaucoma control in the moderate to advanced stages.

OCT FIELD OF VIEW SIMULATION

A method of sector simulation of the visual field using peripapillary NFLP OCT-A results has been developed (Figure 6). The results show a good correlation in the early and moderate stages of the disease. Simulated sectors of the field of view can also be summarized in the mean deviation parameter: NFLP_MD. NFLP_MD correlates with VF_MD, but has better diagnostic accuracy and reproducibility. Thus, a simulated field of view may be better than an actual field of view for monitoring glaucoma progression – in addition to being painless and more convenient.

Visual field testing is not only uncomfortable, but can result in unnecessary surgery or delayed treatment and vision loss. Statistical analyses showed that glaucomatous eye with MD deterioration at -1 dB / year needs testing every six months for four years to make the trend statistically significant (90% strength, $p < 0.05$), with a mean the deviation was already 4 dB worse [14, 15, 16]. This represents a 60% loss of retinal sensitivity, so the doctor has solid evidence and intensifies treatment. A more reproductive and objective method of monitoring the progression of glaucoma could detect significant progression earlier, thus enabling timely intervention to preserve vision.

REFERENCES

- Spaide RF, Fujimoto JG, Waheed NK, Satta SR, Staurengi G. Optical coherence tomography angiography. *Prog Retin Eye Res.* 2018;64:1–55. [DOI: 10.1016/j.preteyeres.2017.11.003] [PMID: 29229445]
- Marić V, Marković V, Božić M, Marjanović I. Comparing characteristics of the optic nerve head among subjects with suspected glaucoma in different ages of onset. *Srp Arh Celok Lek.* 2018;146(3–4):136–42. [DOI: 10.2298/SARH170222144M]
- Maric VD, Grgurevic AD, Cirkovic AM, Marjanovic IS, Bozic MM. The clinical features in patients with newly diagnosed pseudoexfoliative glaucoma in Serbia. *Eur J Ophthalmol.* 2020;30(3):513–24. [DOI: 10.1177/1120672119831532] [PMID: 30808180]
- Abri Aghdam K, Aghajani A, Razi-Khosroshahi M, Soltan Sanjari M, Chaibakhsh S, Falavarjani KG. Optical Coherence Tomography Angiography and Structural Analyses of the Pale Optic Discs: Is It Possible to Differentiate the Cause? *Curr Eye Res.* 2021;46(12):1876–85. [DOI: 10.1080/02713683.2021.1929331] [PMID: 33980086]
- Rao HL, Pradhan ZS, Suh MH, Moghimi S, Mansouri K, Weinreb RN. Optical Coherence Tomography Angiography in Glaucoma. *J Glaucoma.* 2020;29(4):312–21. [DOI: 10.1097/JG.0000000000001463] [PMID: 32053551]
- Yarmohammadi A, Zangwill LM, Diniz-Filho A, Saunders LJ, Suh MH, Wu Z, et al. Peripapillary and Macular Vessel Density in Patients with Glaucoma and Single-Hemifield Visual Field Defect. *Ophthalmology.* 2017;124(5):709–19. [DOI: 10.1016/j.ophtha.2017.01.004] [PMID: 28196732]
- Shin JD, Wolf AT, Harris A, Verticchio Vercellin A, Siesky B, Rowe LW, et al. Vascular biomarkers from optical coherence tomography angiography and glaucoma: where do we stand in 2021? *Acta Ophthalmol.* 2022;100(2):e377–e385. [DOI: 10.1111/aos.14982] [PMID: 34363322]
- Wang Y, Bower BA, Izatt JA, Tan O, Huang D. In vivo total retinal blood flow measurement by Fourier domain Doppler optical coherence tomography. *J Biomed Opt.* 2007;12(4):041215. [DOI: 10.1117/1.2772871] [PMID: 17867804]

AVAILABILITY OF OCT-A

AngioVue, which runs on the Avanti OCT system (Optovue, Inc, Fremont, CA, USA) has a good set of criteria for quantifying peripapillary NFLP and macular SVC [17]. On AngioVue peripapillary scans, NFLP is called radial peripapillary capillary (RPC). For the diagnosis and monitoring of glaucoma, high-resolution OCT-A scans of 4.5×4.5 mm for disc area and RPC density are recommended. Six-by-six-mm HD retinal surface density scanning should be used to scan AngioVue macula. The current AngioVue retinal surface plate corresponds to SVC. Zeiss's CIRRUS HD SEP platform has AngioPlek OCT-A software. AngioPlek 6-mm is used to scan the macula in the assessment of glaucoma. This system can analyze the surface density of the retina, which is called the perfusion density. This system does not currently have special software to analyze peripapillary NFLP around the disc. It is probably possible to export the images and process them for that purpose [18, 19]. Heidelberg has the OCT angiography module for Spectralis, which was introduced at the AAO meeting in 2018. Topcon has developed a fast-source SEP angiography software called OCTARA (under FDA approval) that runs on its Triton OCT platform.

CONCLUSION

The possibilities of OCT-A for glaucomatologists will expand in the near future. The possibility of detecting and monitoring glaucoma with this technology will also be expanded. All of these systems will undoubtedly offer software updates, making it easier for examiners to use the device itself, and thus monitor the disease. OCT-A represents the future in the diagnosis of retinal diseases and glaucoma.

Ethics: The manuscript has been written in accordance with the ethical standards of the respective institution and the journal.

Conflict of interest: None declared.

9. Campbell JP, Zhang M, Hwang TS, Bailey ST, Wilson DJ, Jia Y, et al. Detailed Vascular Anatomy of the Human Retina by Projection-Resolved Optical Coherence Tomography Angiography. *Sci Rep.* 2017;7:42201. [DOI: 10.1038/srep42201] [PMID: 28186181]
10. Düzova E, Demirok G, Üney G, Kaderli A, Yakın M, Özbek-Uzman S, et al. Optical Coherence Tomography Angiography Findings in Primary Open-Angle and Pseudoexfoliation Glaucoma. *Turk J Ophthalmol.* 2022;52(4):252–61. [DOI: 10.4274/tjo.galenos.2021.72654] [PMID: 36017118]
11. Koutropoulou N, Panos GD. The Diagnostic Value of Optical Coherence Tomography Angiography in Glaucoma. *Curr Med Imaging.* 2021;17(10):1179–82. [DOI: 10.2174/1573405617666210412141244] [PMID: 33845726]
12. Mannil SS, Agarwal A, Conner IP, Kumar RS. A comprehensive update on the use of optical coherence tomography angiography in glaucoma. *Int Ophthalmol.* 2023;43(5):1785–802. [DOI: 10.1007/s10792-022-02574-1] [PMID: 36472722]
13. Yarmohammadi A, Zangwill LM, Manalastas PIC, Fuller NJ, Diniz-Filho A, Saunders LJ, et al. Peripapillary and Macular Vessel Density in Patients with Primary Open-Angle Glaucoma and Unilateral Visual Field Loss. *Ophthalmology.* 2018;125(4):578–87. [DOI: 10.1016/j.ophtha.2017.10.029] [PMID: 29174012]
14. Kuryshva NI, Nikitina AD. Opticheskaya kogerentnaya tomografiya i opticheskaya kogerentnaya tomografiya-angiografiya v opredelenii progressirovaniya glaukomy. Chast' 1. Metody issledovaniya, variabel'nost' pokazatelei i rol' vozrastnykh izmenenii [Optical coherence tomography and optical coherence tomography angiography for detecting glaucoma progression. Part 1. Study methods, measurement variability and the role of age-related changes]. *Vestn Oftalmol.* 2023;139(1):122–8. [Article in Russian] [DOI: 10.17116/oftalma2023139011122] [PMID: 36924524]
15. Wang YM, Shen R, Lin TPH, Chan PP, Wong MOM, Chan NCY, et al. Optical coherence tomography angiography metrics predict normal tension glaucoma progression. *Acta Ophthalmol.* 2022;100(7):e1455–e1462. [DOI: 10.1111/aos.15117] [PMID: 35261173]
16. Wu Z, Saunders LJ, Daga FB, Diniz-Filho A, Medeiros FA. Frequency of Testing to Detect Visual Field Progression Derived Using a Longitudinal Cohort of Glaucoma Patients. *Ophthalmology.* 2017;124(6):786–92. [DOI: 10.1016/j.ophtha.2017.01.027] [PMID: 28268099]
17. Marjanović I, Marjanović M, Gvozdenović R, Marjanović M, Marković V, Božić M, et al. Pre-trabeculectomy intravitreal injections of bevacizumab for treating neovascular glaucoma in diabetic patients. *Vojnosanit Pregl.* 2020;77(6):637–40. [DOI: 10.2298/VSP170531137M]
18. Marjanović I, Gvozdenović R, Božić M, Marić V, Stojković M, Marjanović M, et al. Trabeculectomy with mitomycin C for glaucoma secondary to emulsified silicone oil after pars plana vitrectomy: three-years follow up. *Vojnosanit Pregl.* 2022;79(12):1233–8. [DOI: 10.2298/VSP200428001M]
19. Jeremic M, Risimic D, Vasilijevic J, Kovacevic I, Bozic M, Marjanovic I, et al. Uvod u OCTA vaskularnih bolesti retine. In: Kovačević I, Stefanović I. *Bolesti retine – dijagnostika i terapija.* Belgrade: Medicinski fakultet Univerziteta u Beogradu, CIBID; 2020. p. 29–37.

Оптичка кохерентна томографија са ангиографијом код глаукома

Иван Марјановић^{1,2}, Весна Марић^{2,1}, Марија Божић^{1,2}

¹Универзитет у Београду, Медицински факултет, Београд, Србија;

²Универзитетски клинички центар Србије, Клиника за очне болести, Београд, Србија

САЖЕТАК

Оптичка кохерентна томографија са ангиографијом је неинвазивна имидинг техника која омогућава тродимензионалну визуализацију перфузије кроз васкуларну мрежу ретине и хороидеје.

У блиској будућности ће се проширити могућности оптичке кохерентне томографије са ангиографијом за глаукоматологе. Прошириће се и могућност откривања и праћења глаукома овом технологијом.

Сви ови системи ће несумњиво понудити ажурирања софтвера, олакшавајући испитивачима саму употребу апарата, а самим тим и праћење болести. Оптичка кохерентна томографија са ангиографијом представља будућност у дијагностици болести ретине и глаукома.

Кључне речи: глауком; оптичка кохерентна томографија; ангиографија