

PRELIMINARY COMMUNICATION / ПРЕТХОДНО САОПШТЕЊЕ

# The advantage of endoscopic treatment of Haglund's syndrome with the three-portal technique

Miodrag Glišić<sup>1,2</sup>, Vladan Stevanović<sup>1,2</sup>, Aleksandar Jevtić<sup>1,2</sup>, Milan Mirković<sup>1</sup>, Ljubomir Daković<sup>1</sup>, Angelica Arce Stanković<sup>1</sup>, Sanja Mirković<sup>3</sup>, Lazar Mičeta<sup>1,2</sup>

<sup>1</sup>Banjica Institute for Orthopedics, Belgrade, Serbia;

<sup>2</sup>University of Belgrade, Faculty of Medicine, Belgrade, Serbia;

<sup>3</sup>University of Belgrade, Faculty of Sport and Physical Education, Belgrade, Serbia



## SUMMARY

**Introduction/Objective** Heel deformity accompanied by pain at the attachment of the Achilles tendon is generally known as Haglund's syndrome. The prominence of the posterosuperior part of the heel bone generates pressure on the retrocalcaneal bursa and Achilles tendon, causing swelling and pain. The condition itself can be treated using surgical or non-surgical methods. The aim was to present our first experiences in the endoscopic treatment of Haglund's syndrome, employing the three-portal technique.

**Methods** This study includes ten patients whose surgeries were performed during the period between January 2019, and May 2020. All interventions were endoscopic with the three-portal technique used. The diagnosis was made based on the anamnesis, clinical examination, X-rays, and magnetic resonance imaging diagnostics. For the evaluation of results, the AOFAS (American Orthopedic Foot and Ankle Society) score was used.

**Results** The endoscopic findings in all patients revealed a hypertrophic retrocalcaneal bursa and prominence at the posterosuperior part of the calcaneus, generating pressure on the Achilles tendon. By employing the three-portal technique, considerably better visualization is obtained, enabling easy removal of the degenerated tissue. The radiographic control image was satisfactory. The result of the AOFAS score showed a significant improvement after the surgery.

**Conclusion** The endoscopic approach and the use of the three-portal technique in resolving Haglund's syndrome is a secure procedure that produces good results. It enables faster recovery and fewer complications compared to open surgery.

**Keywords:** endoscopic calcaneoplasty; calcaneus; Haglund's syndrome; retrocalcaneal bursitis

## INTRODUCTION

Haglund's syndrome is the condition accompanied by a pain at the backside of the heel, and by a deformity of the heel bone at the place of Achilles tendon. The condition was first described by Haglund in 1928 [1]. The "pump-bump" deformity of the calcaneus, occurring as a prominence of the posterosuperior part in front of the Achilles tendon attachment, generates the pressure on the surrounding retrocalcaneal bursa and Achilles tendon. Over time, this results in the retrocalcaneal bursa growth and the tendon damage. The pain most often occurs at the beginning of movement after a period of rest, and is related to the use of tight footwear too. The pain is caused by the pressure around the Achilles tendon attachment, as well as the dorsiflexion of the foot. There are numerous theories to explain the etiology of this condition: use of tight footwear, overload while running, hereditary factors, and disturbed biomechanics of the subtalar joint [2]. Various types of non-surgical and surgical treatment are applied for this condition. Non-operative treatment includes: wearing wide shoes, heel lifts, stretching exercises, physical procedures, and the local application of corticosteroid injections [3]. If conservative

treatment does not provide good results after six months, a surgical approach is considered [4]. The goal of the surgical treatment is to remove the heel bone lump that causes the pressure, as well as the altered retrocalcaneal bursa. The two common methods of surgical treatment today – open surgery and endoscopy. Corrective osteotomy of the heel bone is described in the literature, aiming at changing the angle of the Achilles tendon attachment, thereby releasing the pressure on the tendon [5]. Open surgery is widespread and there are numerous papers with good postoperative results [6, 7]. However, the endoscopic treatment has its advantages as it provides faster recovery with lower rate of surgical wounds complications, and it is increasingly the method of choice [8, 9].

This paper aims to present our first experiences in the endoscopic treatment of Haglund's syndrome utilizing the three-portal technique.

## METHODS

In the period between January 2019 and May 2020, 10 endoscopic surgeries of remodeling the heel bone with the retrocalcaneal bursa resection were performed. The study involved

**Received • Примљено:**  
March 30, 2023

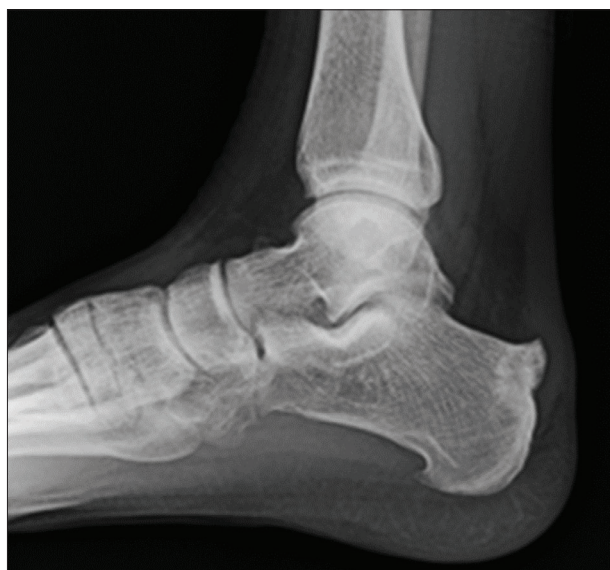**Revised • Ревизија:**  
October 8, 2023

**Accepted • Прихваћено:**  
October 9, 2023

**Online first:** October 31, 2023

## Correspondence to:

Lazar MIČETA  
Institute for Orthopedics Banjica  
Mihaila Avramovića 28  
11040 Belgrade  
Serbia  
[lmiceta@yahoo.com](mailto:lmiceta@yahoo.com)



**Figure 1.** X-ray of Haglund's bone deformity

six men and four women of an average age of 37 years (25–66 years). All patients had suffered from the condition for more than 12 months (12–26 months) and had been treated by non-surgical methods before.

The diagnosis was confirmed by anamnestic data, clinical examination, X-ray, and magnetic resonance imaging. The anamnesis stated the presence of pain at the back of the heel, related to tight footwear and prolonged walking, especially uphill. There was a lump in the region of Achilles tendon attachment, accompanied by pain on pressure in front of the tendon's insertion point. The foot dorsiflexion was very painful.

In all patients, significant prominence at the posterosuperior part of the heel bone was presented on a lateral X-ray, although the parallel pitch lines sign was not always

positive (Figure 1) [10]. Magnetic resonance imaging was taken in several patients and showed the heel bone deformity and a hypertrophic retrocalcaneal bursa with signs of initial degenerative changes of the Achilles tendon.

The study did not include patients with the Achilles tendon calcification, its partial; or full rupture, pes cavus and valgus foot deformity, or rheumatic diseases, as well as patients who had previous surgery in this region.

The AOFAS score was used to evaluate the functional results. The patients were tested before and six months after surgery [11]. The difference was statistically analyzed by Wilcoxon signed-rank test using. Statistical analysis was performed using IBM SPSS Statistics for Windows, Version 28.0 (IBM Corp., Armonk, NY, USA).

### Surgical technique

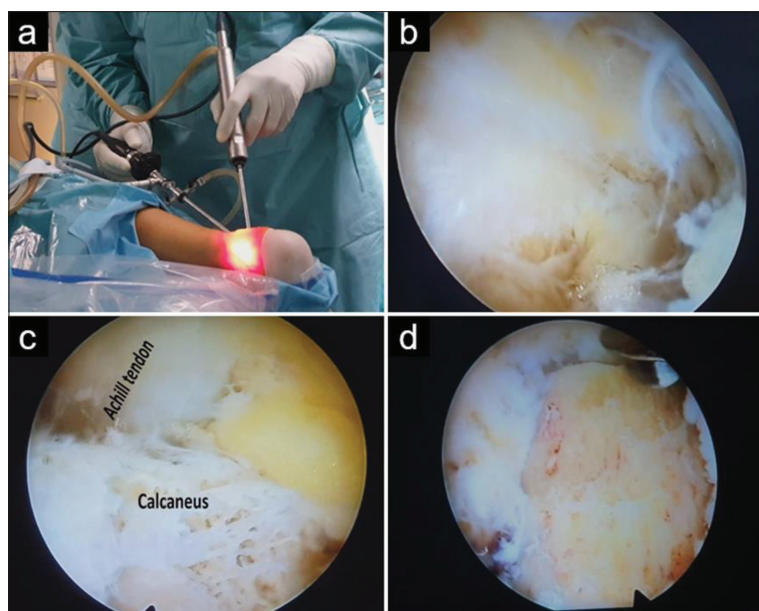
All the surgeries were performed under general anesthesia, with the patient in a prone position. Initially, an X-ray was performed to check the position and degree of resection, later this was done only at the end of the operation. The instruments used included the 4 mm arthroscope with a 30° angle and a set of knee arthroscopy instruments. The three-portal technique was used: the posterolateral distal portal (DPLP), the posteromedial distal portal (DPMP), and the posterolateral proximal portal (PPLP) (Figure 2a) [12]. The PPLP was used for visualization, and the two others were working portals. After opening the portals, the first tissue in sight is a hypertrophic retrocalcaneal bursa, which is being removed by a shaver after (Figure 2b). Further on, there is a clear insight of the heel bone with a prominence at the posterosuperior part, as well as the Achilles tendon with its attachment (Figure 2c). Using the bone abrader, a prominent part of the calcaneus, which makes the pressure on the Achilles tendon, is resected (Figure 2d). The degree of the bone resection is controlled by a direct visualization of the Achilles tendon contact area to the calcaneus, with the foot in dorsiflexion. Experience in endoscopic surgery is necessary.

A lateral X-ray is performed at the end of the surgical procedure, to verify the final resection (Figure 3).

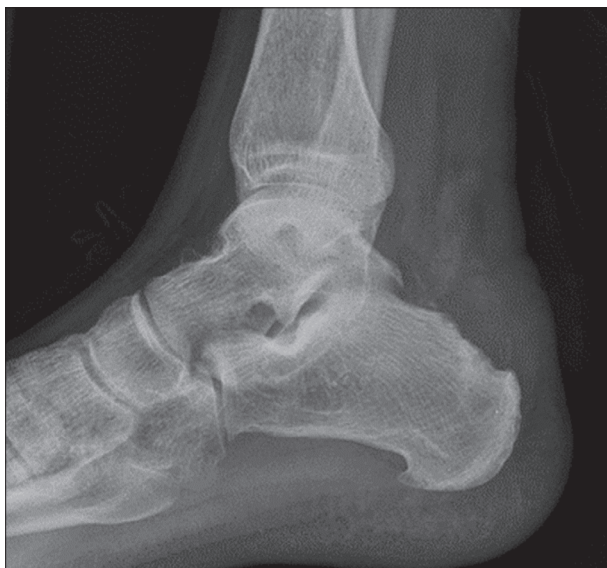### Post-operative rehabilitation

Initial rehabilitation of these patients includes ankle movements, by the use of continuous passive motion machine, and partial weight-bearing starting on the first day after the surgery. Full weight-bearing was allowed in the third week after surgery. Physical rehabilitation is performed to restore the range of ankle motion and to strengthen the calf muscles. Wide shoes and absence of physical activities are suggested for three months.

The study was performed according Declaration of Helsinki ethical principles. This study was approved by committee on ethics of the Banjica Institute for Orthopedics (Resolution no. i-113/12).



**Figure 2.** a – Posterolateral proximal portal and posterolateral distal portal used during the endoscopy; b – retrocalcaneal bursa; c – Achilles tendon and Haglund's deformity; d – heel bone at the place of resected deformity



**Figure 3.** Initial postoperative X-ray of the heel bone

## RESULTS

The surgeries were all performed by the same surgeon, having first own experience in this type of the treatment. The average operation time was 60 minutes (40–90 minutes). All wounds healed normally, and, due to a minimal surgical trauma, the rehabilitation was accelerated. Postoperative x-rays showed a satisfactory degree of resection in most cases. In all patients, a significant improvement and reduction of symptoms were noted in the early phase of rehabilitation. There were no complications. Three patients, started with full weight-bearing and sports activities too early, had occasional pain and swelling up to the third month after surgery.

The AOFAS score showed an improvement. The average values were  $59.3 \pm 11.48$  preoperatively, and  $90.1 \pm 7.55$  confirming a significant change ( $p < 0.005$ ).

## DISCUSSION

Haglund's syndrome is initially treated conservatively. This includes application of nonsteroidal anti-inflammatory drugs, use of wide shoes, heel lifts, change of activity, calf muscle stretching exercises, and other physical therapy procedures. There is also a description of the local use of corticosteroid injections, where special attention should be paid to the risk of damage to the Achilles tendon [13]. According to the literature, the outcome of conservative treatment is unpredictable. Myerson and McGarvey [14] reported a good result in 85% of non-surgically treated patients. On the other hand, Sammarco and Taylor [15] reported a considerably lower success in non-surgical treatment, with as high as 65% of unsuccessful outcomes. If non-surgical treatment lasts longer than six months with persisting problems, than surgical treatment is considered.

During the last two decades, there have been significant changes to the surgical treatment of Haglund's syndrome.

Open surgery with the removal of a retrocalcaneal bursa and remodeling of the heel bone showed good results in 50–100% of cases [5, 15]. Open surgery with wedge osteotomy of the calcaneus is sometimes still used [16]. However, these types of surgery were accompanied by some complications, including wound dehiscence, infection, Achilles tendon rupture, painful surgical scar, and limited ankle motion [5, 17, 18]. Ehredt et al. [19] described a combination of endoscopic calcaneoplasty and gastrocnemius resection, but they reported no data about its safety and efficacy in the treatment of Haglund's syndrome.

Endoscopic surgery has advantages over an open approach: smaller surgical wound, less tissue trauma, better visualization of the pathological process itself, faster recovery, minimal complications from wound healing, and minimal surgical scar [8, 20]. Today there is a growing trend of endoscopy over an open joint surgery, due to the lower rate of wound healing problems, as well as much faster rehabilitation [21, 22]. This problem is common among professional athletes, for whom the period of absence from the field is very important. After an open surgery of Haglund's syndrome, the period of return to the field lasts up to nine months, while it lasts from three to six months after an endoscopic intervention [4, 7, 22].

Our study confirmed good results. There were no complications regarding surgical wounds. The three-portal technique was used, offering better visualization than the two-portals technique. This approach provides a good, direct view of the Achilles tendon and its attachment allowing the removal of the hypertrophic retrocalcaneal bursa and the bone prominence. Bone resection was minimal but sufficient and it was controlled intraoperatively by the checks whether impingement occurs. The operation time was shorter at each subsequent operation. There were no major pain and swelling in the early postoperative period, and all patients completed the rehabilitation according to the protocol. Three patients were professional athletes, thus they were interested for as quick return to the field. As they did not have major problems, they started slightly earlier with a higher load than other patients, which led to swelling and pain. The symptoms decreased with analgesic therapy and rest. Our opinion is that patients with the need for greater physical activities should wait for that at least three months. The patients were generally satisfied with the final outcome, which was confirmed by the AOFAS score results.

## CONCLUSION

The endoscopic approach with the three-portal technique in Haglund's deformity removal is expected to give a good result. Its advantages include a quick return to regular activities, followed by minimal complications. The procedure requires endoscopic instruments, adequate surgical technique, and an educated surgeon.

**Conflict of interest:** None declared.

## REFERENCES

1. Haglund P. Contribution to the clinic of Achilles tendon. *Zeitschr Orthop Chir.* 1928;49:49–58.
2. Choo YJ, Park CH, Chang MC. Rearfoot disorders and conservative treatment: a narrative review. *Ann Palliat Med.* 2020;9(5):3546–52. [DOI: 10.21037/apm-20-446] [PMID: 32787369]
3. Sella EJ, Caminear DS, McLarney EA. Haglund's syndrome. *J Foot Ankle Surg.* 1998;37(2):110–4. [DOI: 10.1016/s1067-2516(98)80089-6] [PMID: 9571457]
4. Opdam KTM, Zwiers R, Vroemen J, Sierevelt IN, Wiegerinck JI, van Dijk CN. High patient satisfaction and good long-term functional outcome after endoscopic calcaneoplasty in patients with retrocalcaneal bursitis. *Knee Surg Sports Traumatol Arthrosc.* 2021;29(5):1494–501. [DOI: 10.1007/s00167-020-06167-2] [PMID: 32712686]
5. Ge Z, Ma L, Tang H, Yang M, Yang A, Yuan C, et al. Comparison of dorsal closing wedge calcaneal osteotomy versus posterolateral prominence resection for the treatment of Haglund syndrome. *J Orthop Surg Res.* 2020;15(1):168. [DOI: 10.1186/s13018-020-01687-6] [PMID: 32381106]
6. Yuen WLP, Tan PT, Kon KKC. Surgical treatment of haglund's deformity: a systematic review and meta-analysis. *Cureus.* 2022;14(7):e27500. [DOI: 10.7759/cureus.27500] [PMID: 3606032]
7. Lee KT, Hyuk J, Kim SJ. Return to play after open calcaneoplasty for insertional achilles tendinopathy with haglund deformity in competitive professional athletes. *Orthop J Sports Med.* 2021;9(6):23259671211009820. [DOI: 10.1177/23259671211009820] [PMID: 34179205]
8. Alessio-Mazzola M, Russo A, Capello AG, Lovisolio S, Repetto I, Formica M, et al. Endoscopic calcaneoplasty for the treatment of Haglund's deformity provides better clinical functional outcomes, lower complication rate, and shorter recovery time compared to open procedures: a systematic review. *Knee Surg Sports Traumatol Arthrosc.* 2021;29(8):2462–84. [DOI: 10.1007/s00167-020-06362-1] [PMID: 33216187]
9. Dijk CN van, Scholten PE, Kort NP. Endoscopic calcaneoplasty. *Am J Sports Med.* 2001;29(2):185–9. [DOI: 10.1177/03635465010290021101] [PMID: 11292043]
10. Yang YP, Li BH, Wei YX, Pan XY, Tao LY, An N, et al. Functional follow-up after endoscopic calcaneoplasty for Haglund's deformity using the biodex isokinetic muscle testing system: A case series. *Exp Ther Med.* 2020;20(3):2805–11. [DOI: 10.3892/etm.2020.9006] [PMID: 32765775]
11. Yuen WLP, Tan PT, Kon KKC. Surgical Treatment of Haglund's Deformity: A Systematic Review and Meta-Analysis. *Cureus.* 2022;14(7):e27500. [DOI: 10.7759/cureus.27500] [PMID: 3606032]
12. Wu Z, Hua Y, Li Y, Chen S. Endoscopic treatment of Haglund's syndrome with a three-portal technique. *Int Orthop.* 2012;36(8):1623–7. [DOI: 10.1007/s00264-012-1518-5] [PMID: 22415722]
13. Vallone G, Vittorio T. Complete Achilles tendon rupture after local infiltration of corticosteroids in the treatment of deep retrocalcaneal bursitis. *J Ultrasound.* 2014;17(2):165–7. [DOI: 10.1007/s40477-014-0066-9] [PMID: 24883139]
14. Myerson MS, McGarvey W. Disorders of the Achilles tendon insertion and Achilles tendinitis. *Instr Course Lect.* 1999;48:211–8. [PMID: 10098046]
15. Sammarco GJ, Taylor AL. Operative management of Haglund's deformity in the nonathlete: a retrospective study. *Foot Ankle Int.* 1998;19(11):724–9. [DOI: 10.1177/107110079801901102] [PMID: 9840198]
16. Zhou S, Li W, Xiang H, Zhang K. Haglund's syndrome: a case description. *Quant Imaging Med Surg.* 2023;13(2):1227–31. [DOI: 10.21037/qims-22-736] [PMID: 36819278]
17. Nesse E, Finsen V. Poor results after resection for Haglund's heel. Analysis of 35 heels treated by arthroscopic removal of bony spurs. *J Bone Joint Surg Br.* 1993;75:437–40. [DOI: 10.3109/17453679408993732]
18. Pauker M, Katz K, Yosipovitch Z. Calcaneal osteotomy for Haglund disease. *J Foot Surg.* 1992;31(6):588–9. [PMID: 1469219]
19. Ehredt DJ, Razzante MC, Darji D, Miggantz HM. Endoscopic Calcaneoplasty With Gastrocnemius Recession for Haglund's Syndrome: Is It Safe and Effective? Results from a Retrospective Case Series. *The Foot.* 2023;57:101960. [DOI: 10.1016/j.foot.2023.101960] [PMID: 37898054]
20. Fathi Mahmoud H, Feisal W, Samir Fahmy F. Satisfactory functional outcome and significant correlation with the length of Haglund's deformity after endoscopic calcaneoplasty: a minimum 4-year follow-up study. *Adv Orthop.* 2022;7889684. [DOI: 10.1155/2022/7889684] [PMID: 35465128]
21. Leitze Z, Sella EJ, Aversa JM. Endoscopic decompression of the retrocalcaneal space. *J Bone Joint Surg Am.* 2003;85(8):1488–96. [DOI: 10.2106/00004623-200308000-00009] [PMID: 12925628]
22. Nakajima K. Fluoroscopic and endoscopic calcaneal exostosis resection and achilles tendon debridement for insertional Achilles tendinopathy results in good outcomes, early return to sports activities, and few wound complications. *Arthrosc Sports Med Rehabil.* 2022;4(4):e1385–e1395. [DOI: 10.1016/j.asmr.2022.04.027] [PMID: 36033171]

## Предности ендоскопске хирургије у лечењу Хаглундовог синдрома употребом технике са три портала

Миодраг Глишић<sup>1,2</sup>, Владан Стевановић<sup>1,2</sup>, Александар Јевтић<sup>1,2</sup>, Милан Мирковић<sup>1</sup>, Љубомир Даковић<sup>1</sup>, Анхелика Арсе Станковић<sup>1</sup>, Сања Мирковић<sup>3</sup>, Лазар Мичета<sup>1,2</sup>

<sup>1</sup>Институт за ортопедију „Бањица“, Београд, Србија;

<sup>2</sup>Универзитет у Београду, Медицински факултет, Београд, Србија;

<sup>3</sup>Универзитет у Београду, Факултет спорта и физичког васпитања, Београд, Србија

### САЖЕТАК

**Увод/Циљ** Деформитет пете праћен болом на месту припоја Ахилове тетиве познат је као Хаглундов синдром. Проминенција суперолатералног дела петне кости која врши притисак на ретрокалканеалну бурсу и Ахилу тетиву доводи до отока и бола. Само стање се може лечити како неоперативно, тако и оперативно.

Приказали смо прва искуства у ендоскопском решавању Хаглундовог синдрома коришћењем технике са три портала.

**Методе** У периоду од јануара 2019. до маја 2020. године учињено је 10 ендоскопских интервенција ремоделације петне кости са ресекцијом ретрокалканеалне бурзе. Дијагноза је постављена на основу анамнезе, клиничког прегледа, рендгенских снимака и магнетне резонанце. За процену резултата коришћен је резултат теста Америчког ортопедског друштва за стопала и скочни зглоб (енг. *American Orthopedic Foot and Ankle Society*) пре операције и шест месеци од оперативног лечења.

**Резултати** Ендоскопски налаз је код свих пацијената показао хипертрофичну ретрокалканеалну бурсу и проминенцију на задњем горњем делу петне кости који прави притисак на Ахилу тетиву. Коришћењем технике са три портала добија се много боља визуализација и лако се уклања измењено ткиво. Радиографска контролна слика је била задовољавајућа. Резултат скорa Америчког ортопедског друштва за стопала и скочни зглоб показује значајно побољшање после ове хируршке интервенције.

**Закључак** Ендоскопски приступ решавању Хаглундовог синдрома са три портала је сигурна процедура која даје добре резултате. Омогућује бржи опоравак уз мање компликације у односу на отворену хирургију.

**Кључне речи:** ендоскопска калканеопластика; калканеус; Хаглундов синдром; ретрокалканеални бурзитис