

CASE REPORT / ПРИКАЗ БОЛЕСНИКА

Transvenous lead placement and its pre-sternal tunneling to the contralateral side as a solution for a pacemaker system upgrade in the case of subclavian vein thrombosis

Nikola N. Radovanović¹, Siniša U. Pavlović^{1,2}, Bratislav Kirčanski¹, Srđan Raspopović¹, Velibor Jovanović¹, Ana Novaković¹, Goran Milašinović^{1,2}

¹Clinical Center of Serbia, Pacemaker Center, Belgrade, Serbia;

²University of Belgrade, School of Medicine, Belgrade, Serbia



SUMMARY

Introduction Chronic right ventricular pacing can deteriorate cardiac function. Consequently, pacemaker system upgrades are more frequently indicated. These interventions can be hindered by venous thrombosis. In literature, it is rarely described that this problem is resolved by implanting a new lead for left ventricle (LV) stimulation on the opposite side of the previously implanted pacemaker and then subcutaneously transferring it to the old pocket.

Case outline A 75-year-old male patient was hospitalized due to a planned pacemaker upgrade in December 2015. A dual-chamber pacemaker had been implanted due to sinus node dysfunction in 2011. During the previous 18 months he had been complaining about symptoms of heart failure. An upgrade to the cardiac resynchronization therapy (CRT) with a new CRT-P device was indicated due to the LV dilatation with the ejection fraction decrease, clinical deterioration, and the presence of high percentage of ventricular pacing. In October 2015, the mentioned intervention was unsuccessful due to total left subclavian vein thrombosis on the side of the previously implanted pacemaker. Anticoagulation therapy was ordained and the reevaluation was postponed. During this hospitalization, venography confirmed total left subclavian vein thrombosis despite the anticoagulation therapy. It was decided to implant a new LV lead on the right side and then subcutaneously shift it by pre-sternal tunneling to the previous left prepectoral pocket. The intervention was uneventful. The first controls have shown stable pacemaker parameters.

Conclusion This case report confirms that contralateral lead placement and subcutaneous pre-sternal tunnelling of the lead is feasible and safe in patients with an implanted pacemaker, an indication for system upgrade and ipsilateral vein obstruction.

Keywords: pacemaker system upgrade; vein obstruction; subcutaneous pre-sternal tunnelling

INTRODUCTION

Prolongation of the average human life span and extension of indications for pacemaker implantation have led to an increase in the number of implanted devices in the world and in our country [1]. Large randomized trials demonstrated the adverse effects of chronic right ventricular pacing associated with an increased risk of atrial fibrillation and heart failure [2, 3]. Therefore, it is not surprising that the number of system upgrades to implantable cardioverter defibrillators (ICDs) or cardiac resynchronization therapy (CRT) devices increases. The main reasons are a decrease in ejection fraction of the left ventricle (LV) and an increase in the New York Heart Association class in patients with implanted antibradycardia pacemakers, due to the consequences of chronic right ventricle pacing [3]. In the case of system upgrade, logical approach is to try a new lead implantation on the same side where the pacemaker system has already existed. In a certain percentage of patients, the presence of pacemaker leads can lead to venous thrombosis. It is estimated that

in 5–26% of patients with chronically implanted devices there is a significantly obstructed or occluded respective vein [4, 5]. In these patients, it is possible to (1) implant an entire new pacemaker system on the opposite side; (2) implant an LV epicardial lead via lateral minithoracotomy; and (3) implant only a new lead on the opposite side, which will be transferred subcutaneously, by pre-sternal tunneling, to the pocket on the other side. While the first two solutions are often used in clinical practice, the third one is rarely described in the literature.

CASE REPORT

A 75-year-old male patient was admitted to the Pacemaker Center of the Clinical Center of Serbia in December 2015 for pacemaker upgrade to the CRT device. The dual-chamber pacemaker had been implanted due to sinus node dysfunction at our center in June 2011. The patient was feeling better after the pacemaker implantation; he tolerated physical effort well and didn't subsequently experience dizziness. Preoperatively,

Примљено • Received:
July 12, 2016

Прихваћено • Accepted:
October 4, 2016

Online first: March 7, 2017

Correspondence to:

Nikola RADOVANOVIĆ
Pacemaker Center
Clinical Center of Serbia
Dr Koste Todorovića 8
11000 Belgrade, Serbia
nikolar86@gmail.com

the LV ejection fraction was 50% (according to Simpson) with the LV end-diastolic volume of 110 cm³. From July 2014, the patient had been complaining about low effort tolerance, peripheral edema and nocturnal shortness of breath. Echocardiography performed in August 2014 revealed dilatative cardiomyopathy with a significantly decreased LV ejection fraction (32% according to Simpson) and an increased LV end-diastolic volume (190 cm³). Since then, he has been treated with optimal medical therapy for heart failure. Paroxysmal atrial fibrillation has been registered since October 2014. Stress echocardiography testing was negative. On February 2015, echocardiography was performed once again and it confirmed a low LV ejection fraction (34% according to Simpson) with the LV end-diastolic volume of 210 cm³. During regular ambulatory pacemaker controls, normal function of the device was ascertained, with the percentage of ventricular pacing over 90%. The percentage of ventricular pacing could not be decreased because of the long PR interval. System upgrade of the CRT device was indicated but the patient postponed the intervention due to personal reasons.

In December 2015, the attempt to upgrade the pacemaker system to a CRT-P device was not successful due to venous thrombosis of the subclavian vein on the left side. It was decided to administer oral anticoagulation therapy and to try to implant a lead for coronary sinus on the left side again in two months. During the next hospitalization, before the re-intervention, digital subtraction angiography was done. The venous occlusion was verified (Figure 1), so an alternative solution was needed. We decided to try to implant the LV lead on the right side, than to shift it to

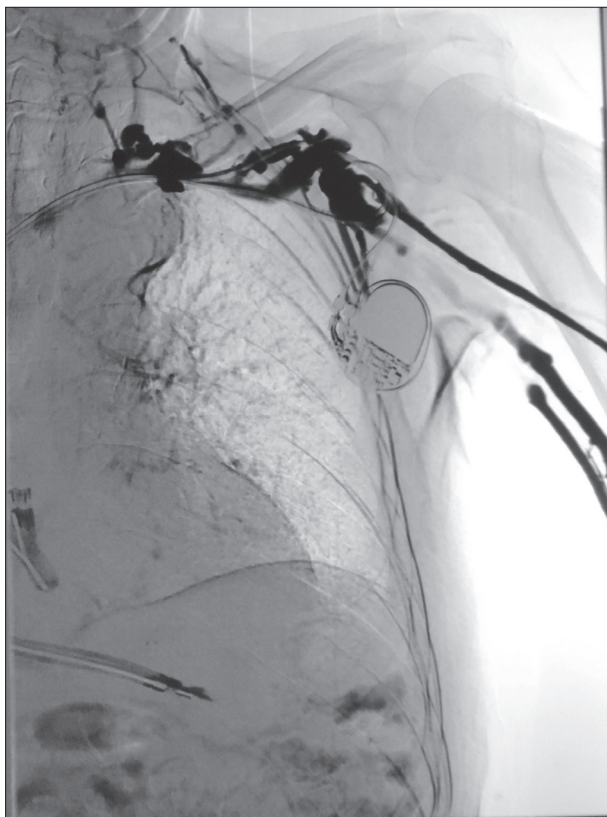


Figure 1. Digital subtraction angiography

the left and to connect it with the new CRT-P device in the previous left prepectoral pocket. Thus, we implanted the LV lead in the posterolateral coronary sinus tributary, using the technique of the right subclavian vein puncture. We proceeded to transfer the distal end of the lead subcutaneously, by pre-sternal tunneling, and to connect it with the new CRT device on the left side (Figure 2). To make the subcutaneous tunnel, a special chest tube was advanced from the contralateral side under the guidance of a trochar. Then, the trochar was removed and the lead was put into the chest tube. Finally, the tube was drawn out and the lead was left at the side of the pocket. The intervention was performed under general endotracheal anesthesia. Intraoperatively measured parameters of the pacemaker function were stable. The patient's recovery was uneventful, and he was discharged in good condition on the first postoperative day. After one-month and three-month follow-ups, the CRT control showed stable parameters, with no differences in relation to those obtained during the intervention.

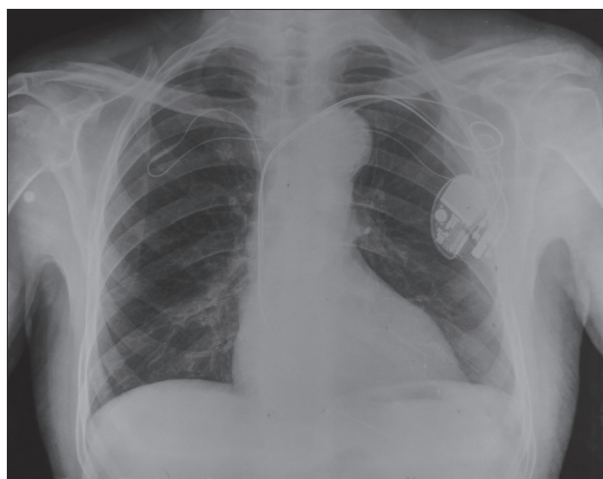


Figure 2. The new cardiac resynchronization therapy device

DISCUSSION

Many studies have confirmed the efficacy of CRT therapy in patients with symptomatic heart failure, left ventricular dysfunction and wide QRS complex [6, 7]. Therefore, it is important that every patient in whom the CRT is indicated achieves resynchronization. In order to reach this goal, it is valuable to have available alternative approaches. Contralateral lead placement and subcutaneous pre-sternal tunnelling of the lead to the device is an approach that was first described by Belott [8] in 1983. Since then, this technique has been sporadically described in the literature. The only retrospective study that evaluated the acute success, complication rates, long-term lead function, and subject tolerability of the contralateral pacemaker lead placement and subcutaneous, pre-sternal lead tunnelling in patients with chronically implanted rhythm devices, showed that this approach has high acute success and acceptable long-term outcome [5]. In this study, one of the twenty leads had to be replaced due to a structural defect and one patient reported discomfort related to the tunneled lead [5].

This approach has significant advantages over other methods described. Only one new lead needs to be implanted in this technique, in contrast to the approach that involves the implantation of a new system on the opposite side, which implies implanting three new leads through the venous system, thus significantly increasing the risk of further venous thrombosis and making the starting position of a possible new re-intervention significantly more difficult. On the other hand, this intervention takes less time than the LV lead implantation via lateral minithoracotomy, and is followed by a complete and quick recovery. Also, for an experienced operator, this intervention is not too demanding, but requires the use of specific tools.

It should be noted that subcutaneously implanted leads are more susceptible to damage, fracture. Also, unlike im-

planting a new pacemaker system on the opposite side, this intervention is more invasive, performed under general endotracheal anesthesia.

The presented case is specific due to the fact that the implantation of the LV lead into the coronary venous system was performed on the right side, which is a more complicated approach [9]. More common situation is that this technique is used when the device is on the right side and the upgrade procedure is done by adding the LV lead from the left side.

In summary, this case report confirms that contralateral lead placement and subcutaneous pre-sternal tunnelling of the lead is a feasible and safe approach in patients with a chronically implanted pacemaker, an indication for a system upgrade, and an ipsilateral vein obstruction.

REFERENCES

1. Brignole M, Auricchio A, Baron-Esquivas G, Bordachar P, Boriani G, Breithardt OA, et al. 2013 ESC Guidelines on cardiac pacing and cardiac resynchronization therapy: the Task Force on cardiac pacing and resynchronization therapy of the European Society of Cardiology (ESC). Developed in collaboration with the European Heart Rhythm Association (EHRA). *Eur Heart J*. 2013; 34(29):2281–329.
2. Tang AS, Wells GA, Talajic M, Arnold MO, Sheldon R, Connolly S, et al. Cardiac-resynchronization therapy for mild-to-moderate heart failure. *N Engl J Med*. 2010; 363(25):2385–95.
3. Linde C, Leclercq C, Rex S, Garrigue S, Lavergne T, Cazeau S, et al. Long-term benefits of biventricular pacing in congestive heart failure: results from the MULTISITE STimulation in cardiomyopathy (MUSTIC) study. *J Am Coll Cardiol*. 2002; 40(1):111–8.
4. Haghighi M, Nikoo MH, Fazelifar AF, Alizadeh A, Emkanjoo Z, Sadr-Ameli MA. Predictors of venous obstruction following pacemaker or implantable cardioverter-defibrillator implantation: a contrast venographic study on 100 patients admitted for generator change, lead revision, or device upgrade. *Europace*. 2007; 9(5):328–32.
5. Lühje L, Zabel M, Seegers J, Zenker D, Vollmann D. Acute and long-term feasibility of contralateral transvenous lead placement with subcutaneous, pre-sternal tunnelling in patients with chronically implanted rhythm devices. *Europace*. 2011; 13(7):1004–8.
6. Moss AJ, Hall WJ, Cannom DS, Klein H, Brown MW, Daubert JP, et al. Cardiac-resynchronization therapy for the prevention of heart-failure events. *N Engl J Med*. 2009; 361(14):1329–38.
7. Bristow MR, Saxon LA, Boehmer J, Krueger S, Kass DA, De Marco T, et al. Cardiac-resynchronization therapy with or without an implantable defibrillator in advanced chronic heart failure. *N Engl J Med*. 2004; 350(21):2140–50.
8. Belott PH. Use of the contralateral subclavian vein for placement of atrial electrodes in chronically VVI paced patients. *Pacing Clin Electrophysiol*. 1983; 6(4):781–3.
9. Hsu JC, Badhwar N, Lee BK, Vedantham V, Tseng ZH, Marcus GM. Predictors of fluoroscopy time and procedural failure during biventricular device implantation. *Am J Cardiol*. 2012; 110(2):240–5.

Уградња електроде венским путем и њено пребацивање на супротну страну престерналним тунелирањем као решење за болеснике са тромбозом поткључне вене и потребом за надоградњом пејсмејкер система

Никола Н. Радовановић¹, Сениша У. Павловић^{1,2}, Братислав Кирђански¹, Срђан Распоповић¹, Велибор Јовановић¹, Ана Новаковић¹, Горан Милашиновић^{1,2}

¹Клинички центар Србије, Пејсмејкер центар, Београд, Србија;

²Универзитет у Београду, Медицински факултет, Београд, Србија

САЖЕТАК

Увод Дуготрајни пејсинг десне коморе може бити повезан са појавом срчане слабости. Једна од наредних терапијских могућности је надоградња пејсмејкер система уградњом додатне електроде за стимулацију леве коморе (ЛК). Ова интервенција може бити отежана због тромбозе приступне вене. У литератури је описан врло мали број болесника код којих је овај проблем решен уградњом електроде за стимулацију ЛК са супротне стране од претходно уграђеног пејсмејкера и супкутаном пребацивањем до првобитне ложе пејсмејкера.

Приказ болесника Мушкарац стар 75 година хоспитализован је децембра 2015. године због надоградње пејсмејкера. Године 2011, због дисфункције синусног чвора, имплантиран је антибрадикардни пејсмејкер са леве стране. Јуна 2014. имао је прву манифестацију срчане слабости. Због дилатације и пада ејекционе фракције ЛК а присутног високог процента коморског пејсинга индикувана је надоградња на ресинхронизациони пејсмејкер систем. Октобра 2015. године

покушана интервенција није успела због истостране потпуне тромбозе поткључне вене и започета је антикоагулантна терапија. Приликом последње хоспитализације урађена венографија је потврдила перзистирање тромбозе леве поткључне вене те је одлучено да се имплантира нова електрода за стимулацију леве коморе са контралатералне, десне стране, а да се она поткожно, престерналним тунелирањем, пребаци до претходне ложе пејсмејкера. Интервенција је протекла без компликација, а прве контроле показале су стабилне параметре пејсмејкер функције.

Закључак Овај приказ потврђује да је контралатерална уградња нове електроде и њено пребацивање до старе пејсмејкер ложе поткожно, престерналним тунелирањем изводљив и сигуран приступ код болесника са индикацијом за надоградњом пејсмејкер система и истостраном венском опструкцијом.

Кључне речи: надоградња пејсмејкер система; венска опструкција; поткожно престернално тунелирање