



**СРПСКИ АРХИВ**  
ЗА ЦЕЛОКУПНО ЛЕКАРСТВО  
**SERBIAN ARCHIVES**  
OF MEDICINE

Address: 1 Kraljice Natalije Street, Belgrade 11000, Serbia

+381 11 4092 776, Fax: +381 11 3348 653

E-mail: [office@srpskiarhiv.rs](mailto:office@srpskiarhiv.rs), Web address: [www.srpskiarhiv.rs](http://www.srpskiarhiv.rs)

Paper Accepted\*

ISSN Online 2406-0895

**Case Report / Приказ болесника**

Marija Božić\*, Tanja Kalezić, Vesna Marić, Bojana Dačić Krnjaja

**Mystery corneal opacity ring**

Мистериозни прстенови на рожњачи

University of Belgrade, Faculty of Medicine, University Clinical Center of Serbia, University Eye Hospital, Belgrade, Serbia

**Received: July 6, 2025**

**Accepted: November 12, 2025**

**Online First: November 28, 2025**

**DOI: <https://doi.org/10.2298/SARH250706091B>**

\* **Accepted papers** are articles in press that have gone through due peer review process and have been accepted for publication by the Editorial Board of the *Serbian Archives of Medicine*. They have not yet been copy-edited and/or formatted in the publication house style, and the text may be changed before the final publication.

Although accepted papers do not yet have all the accompanying bibliographic details available, they can already be cited using the year of online publication and the DOI, as follows: the author's last name and initial of the first name, article title, journal title, online first publication month and year, and the DOI; e.g.: Petrović P, Jovanović J. The title of the article. *Srp Arh Celok Lek*. Online First, February 2017.

When the final article is assigned to volumes/issues of the journal, the Article in Press version will be removed and the final version will appear in the associated published volumes/issues of the journal. The date the article was made available online first will be carried over.

**\*Correspondence to:**

Marija BOŽIĆ

Pasterova 2, 11000 Belgrade, Serbia

[ammilovic@gmail.com](mailto:ammilovic@gmail.com)

## Mystery corneal opacity ring

### Мистериозни прстенови на рожњачи

#### SUMMARY

**Introduction** We present a case of an incidental finding of unusual ring-like bilateral corneal opacities in otherwise clear corneas in a person with no other ophthalmological disease except cataract. Clinical findings, laser scanning in vivo confocal microscopy and corneal topography findings do not correspond to any described corneal degeneration, so the aim of this presentation is to consult with fellow ophthalmologists regarding the origin and significance of the described changes.

**Case outline** „Mystery corneal ring“ is found incidentally as a bilateral, asymptomatic, almost perfectly round in shape, white and situated adjacent to limbus. The appropriate diagnostics performed did not give an answer as to the origin of these symmetrical opacities.

**Conclusion** We present previously undescribed symmetrical bilateral corneal opacities, in search of an answer as to whether any of our fellow ophthalmologists have had similar cases in their practice or know what type of disorder it is.

**Keywords:** cornea; opacity; dystrophy

#### САЖЕТАК

**Увод** Представљамо случај случајног налаза необичних прстенастих билатералних замућења рожњаче на иначе провидним рожњачама код особе без других офталмолошких болести осим катаракте. Клинички налази, ин виво конфокална микроскопија и налази топографије рожњаче не одговарају ниједној описаној дегенерацији рожњаче, па је циљ ове презентације консултација са колегама офталмологима у вези са пореклом и значајем описаних промена.

**Приказ случаја** „Мистериозни прстен рожњаче“ је случајно уочен као билатерални, асимптоматски, готово савршено округлог облика, беле боје и смештен уз лимбус. Одговарајућа дијагностика није дала одговор на порекло ових симетричних замућења.

**Закључак** Представљамо раније неописана симетрична билатерална замућења рожњаче, у потрази за одговором на питање да ли је неко од наших колега офталмолога имао сличне случајеве у својој пракси или зна о каквој врсти поремећаја се ради.

**Кључне речи:** рожњача; замућење; дистрофија

#### INTRODUCTION

Congenital anomalies of the cornea are changes of a wide spectrum and do not all have to lead to a decrease in visual acuity or other symptoms. Corneal findings in those cases are most often bilateral, although they can be asymmetric and are very well classified and described. However, occasionally in clinical practice we encounter a finding on the cornea that does not correspond to any entity described so far. The aim of this case report is to share our findings with a wider ophthalmological audience and to obtain the opinion of our colleagues regarding the origin of the described changes.

## CASE REPORT

A 75 years-old-woman presented for cataract surgery. Best corrected visual acuity (Snellen) was 0.4 in her right and 0.6 in her left eye. The corneas were otherwise normal, with single regular, ring shaped, opacification approximately 3 mm from the limbus. The epithelium overlying the hazed part of the cornea was regular. Cortical and nuclear opacities were noted in right lens. Intraocular pressures (Goldman applanation tonometry) were 14 and 16 mmHg. Cup to disc ratio was 0.3/0.3 in both of her eyes. Central corneal thickness was 525  $\mu\text{m}$  and 524  $\mu\text{m}$ . Corneal sensations were normal in both eyes. Corneal opacity did not affect visual acuity.

We did laser scanning in vivo confocal microscopy and corneal topography that revealed sharply demarcated single corneal ring, with smooth surface, and no deposits or pigmentations, and band like condensations in corneal stroma (Figure 1 and Figure 2).

Patient gave written consent for this case report to be presented and the Ethics Committee of the University Clinical Center of Serbia gave permission for the presentation (number of approval 192-22).

## DISCUSSION

Similar cases of bilateral ring-shaped opacities in the cornea have been published earlier, but none of them corresponds to the case that we are presenting [1, 2]. Opacities in the form of geometrically regular rings on the periphery of the cornea in the described case look almost like scars from corneal transplant, but the patient did not undergo this surgery. Some of the similar peripheral corneal opacities are part of the clinical picture of the well-known corneal dystrophies [3, 4, 5]. Common feature about these previously described corneal rings is that

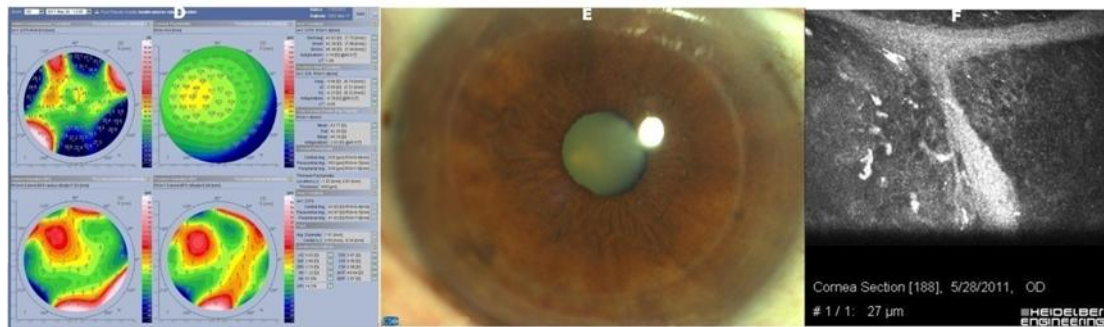
they become visible at older age and are non-progressive. In the case that we present, we do not have data on when the clouding of the cornea appeared, because the patient did not even register them considering that they do not affect visual acuity or cause any symptoms.

We do not have an answer to the question of why our patient developed bilateral, symmetrical, almost geometrically regular hazy corneal rings. Considering that the patient has no other ophthalmological problems apart from cataracts, it is unlikely that a cornea replacement will be planned, so we cannot expect a histological answer to our question. In this case, we would like to initiate a discussion of our fellow ophthalmologists who would share their experiences and opinion.

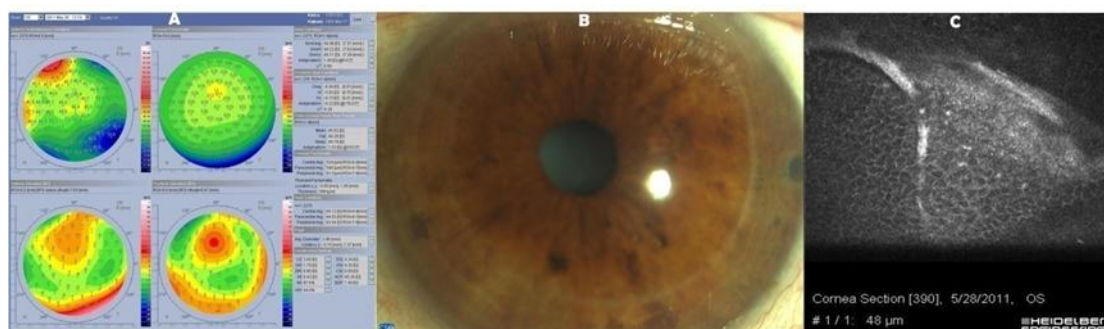
**Conflict of interests:** None declared.

## REFERENCES

1. Uddaraju M, Mascarenhas J, Das M, Prajna NV. A case of bilateral, multiple, symmetric, concentric ring-shaped opacities in the cornea. *JAMA Ophthalmol.* 2015 ;133(4):483–4. [DOI: 10.1001/jamaophthalmol.2014.5379] [PMID: 25569602]
2. Petrovic T, Stanojlovic S. Tomographic changes after corneal collagen cross-linking for progressive keratoconus – one-year follow-up study. *Srp Arh Celok Lek* 2022;150(7–8): 445–50. [DOI: 10.2298/SARH200731062P]
3. Melles GR, de Séra JP, Eggink CA, Cruysberg JR, Binder PS. Bilateral, anterior stromal ring opacity of the cornea. *Br J Ophthalmol.* 1998;82(5):522–5. [DOI: 10.1136/bjo.82.5.522] [PMID: 9713059]
4. Megalla M, Li E, Branden P, Chow J. Bilateral idiopathic corneal opacity: A report of Ascher ring and a review of the literature. *Am J Ophthalmol Case Rep.* 2021;22(23):101176. [DOI: 10.1016/j.ajoc.2021.101176] [PMID: 34368499].
5. Nofal N, Darvish-Zargar M, Teboul B. A case of symmetric bilateral ring-shaped corneal opacities. *Can J Ophthalmol.* 2022;57(2):e42-e44. [DOI: 10.1016/j.cjco.2021.07.006] [PMID: 34419420]



**Figure 1.** Topography, slit lamp photography and Heidelberg Retinal Tomography of the right eye



**Figure 2.** Topography, slit lamp photography and Heidelberg Retinal Tomography of the left eye