



CASE REPORT / ПРИКАЗ БОЛЕСНИКА

Left ventricular assist device implantation and concomitant aortic valve replacement

Aleksandar Mikić^{1,2}, Emilija Nestorović², Ilija Bilbija^{1,2}, Duško Terzić², Svetozar Putnik^{1,2}¹University of Belgrade, Faculty of Medicine, Belgrade, Serbia;²Clinical Center of Serbia, Clinic for Cardiac Surgery, Belgrade, Serbia**SUMMARY**

Introduction The implantable device for mechanical support of the left ventricular circulation (LVAD) is widely applied as a therapeutic option for survival and improvement of the quality of life in patients with the end-stage heart failure.

The objective of our paper was to present the implantation of the aforementioned device together with the aortic valve replacement in the same procedure.

Case outline The patient was admitted to the hospital during his terminal stage of heart failure, with ejection fraction of 18%. The ergospirometry test showed that the maximum VO_2 was 10.1 ml/kg/min. Because the medication therapy hadn't provided adequate results, the LVAD device was implanted as a bridge until transplantation. Due to severe aortic insufficiency, the aortic valve was concomitantly replaced with bioprosthesis in order to prevent the negative effect of this valvular disease on pump work and clinical outcome.

Conclusion This case report confirms that LVAD implantation with the correction of a significant aortic insufficiency is a procedure with satisfactory short-term and long-term results.

Keywords: cardiac failure; LVAD; aortic valve

INTRODUCTION

The implantation of the left ventricular assist device is a therapeutic option for the treatment of end-stage heart failure patients. However, this group of patients often suffers from different associated pathological changes of the heart, most commonly cardiac valves. Some of these defected valves require surgical correction at the same time when LVAD is being implanted. If not, they could interfere with the function of the device and have unfavorable effect on the clinical outcome [1].

In addition, uncorrected aortic insufficiency (AI) at the time of LVAD implantation may progress and affect the effectiveness of the pump by limiting forward flow [2].

We present the first case report in Serbia of the implantation of the LVAD and concomitant aortic valve replacement in patients with the end-stage heart failure.

CASE REPORT

A 64-year-old male patient presented in the end-stage heart failure due to ischemic cardiomyopathy. The patient mentioned fatigue and continuous squeezing chest pains as symptoms. He had also been treated for bronchial asthma and frequent respiratory infections. In the previous two years, the patient had been hospitalized four times due to heart failure symptoms. Selective coronarography showed that

left anterior descending artery had a proximal stenosis around 90–95%, while the circumflex artery was occluded in its medial segment. The proximal part of the right coronary artery was also occluded.

Ergospirometry (cardiopulmonary exercise testing) showed reduced exercise capacity with peak oxygen consumption (VO_2 peak) 10.1 ml/kg/min.

Single-photon emission computerized tomography showed the absence of viable myocardium of the apex, lateral, and inferior walls.

Echocardiography recorded severely impaired ejection fraction (EF) of the left ventricle with combined aortic defect. The complete aortic defect manifesting with aortic stenosis and low flow gradient due to extremely impaired systolic function of the left ventricle was evident (aortic valve area was 1.1 cm^2 , peak gradient was 27, V max 2,6). AI of 2–3+ was recorded. The left ventricle dimensions were enlarged, end-diastolic diameter (EDD) was 7.2 cm, end-systolic diameter (ESD) was 6.6 cm with EF of 20% by Biplane and 18% by Teicholz. Echocardiography also recorded akinetic septum and basal segment of the anterior wall, akinetic posterior wall, as well as fibrously modified and dyskinetic basal inferior wall. Mitral valve morphology was preserved. The left moderate to severe atrial mitral regurgitation of 2–3+ with its normal dimensions, i.e. 3.9 cm, was noted. The right ventricular dimension was normal (1.8 cm), with good systolic and longitudinal functions, fractional area change

Received • Примљено:
June 14, 2018

Revised • Ревизија:
May 13, 2019

Accepted • Прихваћено:
May 27, 2019

Online first: June 19, 2019

Correspondence to:

Duško TERZIĆ
Clinic for Cardiac Surgery
Clinical Center of Serbia
Dr. Koste Todorovića 8
11000 Belgrade, Serbia
terzic.dusko@gmail.com

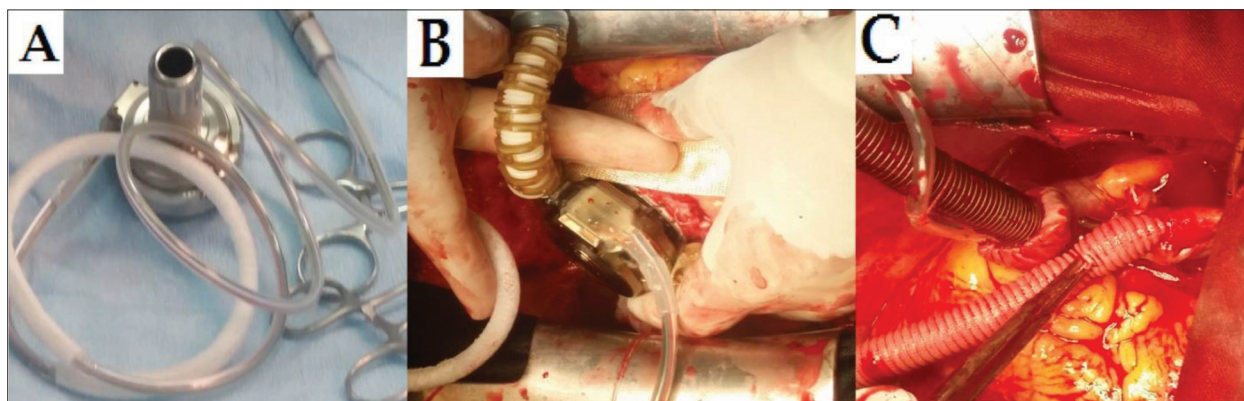


Figure 1. A) Preparation of the Heart Ware device – connecting the outflow graft to the pump and rinsing the pump; B) after the circular opening of the left ventricle and fastening of the ring, the pump was fixed and hemostasis was checked; C) outlet graft fastened to the ascending aorta

of 50% and (tricuspid annular plane systolic excursion) TAPSE of 24 mm.

The patient was categorized as New York Heart Association (NYHA) class IV, Interagency Registry for Mechanically Assisted Circulatory Support (INTERMACS) class 4.

Upon the complete preoperative preparation, the patient was operated on in the conditions of extracorporeal circulation. After median sternotomy, the patient was heparinized and cannulated. Aortic valve replacements preceded pump implantation. Myocardial protection was achieved using antegrade cardioplegia solution. The aortic valve was replaced with a St. Jude Medical Biocor Bioprosthesis (Number 23).

The aortotomy was closed. After releasing the clamp, HeartWare LVAD (Medtronic, Minneapolis, MN, USA) was implanted on the beating heart. The inflow cannula device was installed over the top of the left ventricle, the output graft was connected with the ascending aorta, while the power cable was drawn through the skin (Figure 1).

The patient became fully activated in the postoperative period. The patient and his family members were educated on hygiene maintenance of the spot where the power cable exits the skin as well as interpretation of basic findings and LVAD controller alarm.

Echocardiography finding on discharge showed biological artificial aortic valve closing with each cardiac cycle. The left ventricle had mildly enlarged dimensions, EDD 5.8 cm and ESD 5 cm, and EF in basal segment was estimated to 29%. The right ventricle had normal dimension – 2.6 cm, good systolic and poorer longitudinal function, TAPSE 12 mm (underestimated due to the opening of the pericardium).

The pump speed was set at 2,600 rpm, pump flow at 6.7 l/min., pump power at 4.1 W, and spare controller at 2,600 rpm.

The therapy prescribed on discharge included the following: warfarin (according to therapeutic protocol so that international normalized ratio would be 2–3); acid acetylsalicylic 100 mg, ramipril tab. 2 × 5 mg, bisoprolol fumarate 1 × 5 mg, amiodarone 200 mg, furosemide tab. 1 × 20 mg, spironolactone 1 × 25 mg, trimetazidine 2 × 35 mg, pantoprazole 2 × 20 mg, and atorvastatin 1 × 10 mg.

On 30-day, two-month, six-month, and one-year control visits, the patient did not manifest the signs of heart failure, and LVAD parameters on the controller were stable.

The pump speed was set at 2,700 rpm, in order to achieve better unloading of the LV, with pump flow of 5 l/min and pump power of 4.4 W. Echocardiography examination at 15 months showed biological artificial aortic valve closing with each cardiac cycle, with normal flow gradients, improvement in EDD and ESD from baseline values of 7.2 cm and 6.6 cm to 6.4 cm and 4.9 cm, respectively and mild mitral regurgitation. For EF and B-type natriuretic peptide (pg/ml), the baseline values of 20% and 960, improved to 46% and 176, respectively. The dimension of the right ventricle was sustained in the normal range (2.6 cm) with good systolic function. There was normal flow through both inflow and outflow cannula.

DISCUSSION

The prevalence of a heart failure is roughly around 1–2% in adults and goes all the way up to 10% in patients older than 70 years [3].

The therapy of choice for treating end-stage heart failure is the heart transplantation. However, the insufficient number of donors has accelerated the development of mechanical circulatory support (MCS) devices. In the last couple of decades, the biggest improvement (leap) in the treatment of heart failure was made in the usage of short-term MCS for cardiogenic shock, and long-term MCS for destination or bridge-to-transplant therapy [4].

Current indications for LVAD implantation are bridge-to-transplant patients, implantation as a permanent or destination therapy and a bridge to recovery of the heart's function in cases when there is a significant improvement of the heart's structure and function that is enough to achieve long-term disappearance of symptoms (in these cases, the explanation of the device is considered) [5].

The number of LVADs that are implanted worldwide is continuously rising. The growing experience of LVAD implantation has led to a substantial improvement of the outcome, with one-year survival rates approaching those

in patients with heart transplantation. These refinements have caused growing interest for expanding the clinical indications for LVAD therapy, especially in patients with less advanced heart failure [6, 7].

The criteria for LVAD implantation are NYHA class IV heart failure refractory to optimal medical therapy, left ventricular EF less than 25%, systolic blood pressure < 80 mmHg, pulmonary capillary wedge pressure > 20 mmHg, cardiac index < 2.0 l/min/m² despite continuous intravenous inotropic therapy and intra-aortic counterpulsation. In addition to these criteria, malignant cardiac arrhythmias, as well as patients who are on the transplantation waiting list can also be considered for the LVAD therapy. Patients who suffer from an advanced congestive heart failure are a bigger challenge and, therefore, physicians must monitor the symptoms closely in order to identify the right timing for the implantation of the LVAD. If the LVAD is implanted too early, benefits and the potential of this medical treatment to recover heart function will not be fully utilized. If the LVAD is implanted too late, the outcome may worsen due to a secondary organ damage caused by a prolonged heart failure.

It is important to note that valvular heart disease is often present. The decision to surgically manage valvular disease at the same time as LVAD implantation depends on several factors such as the influence of valvular disease on post-implantation period and indications for surgical management of a valvular disease [8].

It is known that AI is a complication in approximately 25% of patients with a non-pulsatile MCS device. Although the increase in LVAD speed improves hemodynamics, it also deteriorates aortic regurgitation (AR). AI in patients with LVAD support contributes to higher baseline central venous pressure, peak capillary wedge pressure, and lower pulmonary artery pulsatility index. [9].

Mitral stenosis must be managed during LVAD implantation, since the presence of the mitral valve prosthesis (biological or mechanical) is not a contraindication for LVAD implantation [10].

Secondary tricuspid regurgitation (TR) is frequent in patients with the associated failure of the right cardiac ventricle who are undergoing a LVAD implantation. The decision to perform a tricuspid valve repair during LVAD implantation is in correlation with moderate-to-severe degree of TR. If TR was corrected, it might have benefit on venous flow and renal perfusion and also improve post-operative morbidity [11].

Truby et al. [12] reported that out of 10,603 eligible patients, 1,399 patients on CF-LVAD support developed moderate to severe AI. The prevalence of a significant AI progressively increased over time. The predictors of AI worsening included older age, female sex, smaller body mass index, mild pre-implantation AI, and destination

therapy strategy. Moderate to severe AI was associated with significantly higher left ventricular EDD, reduced cardiac output, and higher levels of brain natriuretic peptide. Significant AI was associated with higher rates of rehospitalization (32.1% vs. 26.6%, respectively, at two years; $p = 0.015$) and mortality (77.2% vs. 71.4%, respectively, at two years; $p = 0.005$), conditional upon survival to one year. [12, 9].

The surgical strategy and timing of significant AR surgical management have not been fully defined. There have been several articles describing a few treatments of AR at the time of LVAD implantation. Understanding of the AI after MCS is evolving; however, continuous closure of the aortic valve is thought to be the main cause. Careful attention to outflow cannula orientation in order to prevent direct flow towards the aortic valve can minimize the stress on the valve [9].

Today, the most common procedure is a simultaneous aortic valve replacement with bioprosthesis. However, you may also find reports of patch closure of the outflow tract, primary aortic cusp closure with felt strips, and coaptation stitching of the valve cusps that are more rare procedures [13].

The bioprosthetic valve replacement has the advantage of eliminating valve pathology altogether and not rendering the patient LVAD-dependent. It is very important to know that the controlled work pump and heart beat ratio provide occasional opening of the aortic valve (or bioprosthesis) that could potentially prevent the development of clot formations and fusion of the aortic root washout [14].

Timing of the aortic valve replacement is a unique clinical challenge as well, and the decision is made based on the degree of AR, as well as indications for LVAD implantation. Patients with mild to moderate AR who belong to the “bridge-to transplant” group, where a shorter time of organ donation is expected, the replacement of aortic valve is not necessary. On the other hand, in the “destination therapy” group and in patients with significant AR, aortic valve replacement during LVAD implantation is a reasonable option [15].

The case presented in our report underwent implantation of LVAD for maintaining vital parameters and eliminating the symptoms of heart failure. The significant aortic failure was repaired simultaneously with LVAD implantation by replacing the impaired valve with bioprosthesis. This case report shows that LVAD implantation, along with correction of significant AI by replacing the aortic valve with bioprosthesis, is a procedure that has satisfying results.

This case report was approved by the institutional ethics committee, and written consent was obtained from the patient for the publication of this case report and any accompanying images.

Conflict of interest: None declared.

REFERENCES

- Potapov EV, Stepanenko A, Krabatsch T, Hetzer R. Managing long term complications of left ventricular assist device therapy. *Curr Opin Cardiol.* 2011; 26(3):237–44.
- Atkins BZ, Hashmi ZA, Ganapathi AM, Harrison JK, Hughes GC, Rogers JG, et al. Surgical correction of aortic valve insufficiency after left ventricular assist device implantation. *J Thorac Cardiovasc Surg.* 2013; 146(5):1247–52.
- Ponikowski P, Voors AA, Anker SD, Bueno H, Cleland JGF, Coats AJ, et al. 2016 ESC guidelines for the diagnosis and treatment of acute and chronic heart failure: The Task Force for the diagnosis and treatment of acute and chronic heart failure of the European Society of Cardiology (ESC): developed with the special contribution of the Heart Failure Association (HFA) of the ESC. *Eur J Heart Fail.* 2016; 37(27):2129–200.
- Crespo-Leiro MG, Metra M, Lund LH, Milicic D, Costanzo MR, Filippatos G, et al. Advanced heart failure: a position statement of the Heart Failure Association of the European Society of Cardiology. *Eur J Heart Fail.* 2018; 20(11):1505–35.
- Drakos SG, Pagani FD, Lundberg MS, Baldwin JT. Advancing the science of myocardial recovery with mechanical circulatory support: a working group of the national, heart, lung, and blood institute. *JACC Basic Transl Sci.* 2017; 2(3):335–40.
- Lima B, Bansal A, Abraham J, Rich JD, Lee SS, Soleimani B, et al. Controversies and Challenges of Ventricular Assist Device Therapy. *Am J Cardiol.* 2018; 121(10):1219–24.
- Takeda K, Takayama H, Kalesan B, Uriel N, Colombo PC, Jorde UP, et al. Long-term outcome of patients on continuous-flow left ventricular assist device support. *J Thorac Cardiovasc Surg.* 2014; 148(4):1606–14.
- Sugiura T, Kurihara C, Kawabori M, Critsinelis AC, Wang S, Civitello AB, et al. Concomitant valve procedures in patients undergoing continuous-flow left ventricular assist device implantation: A single-center experience. *J Thorac Cardiovasc Surg.* 2019; 158(4):1083–89.e1.
- Cook JL, Colvin M, Francis GS, Grady KL, Hoffman TM, Jessup M, et al. Recommendations for the use of mechanical circulatory support: ambulatory and community patient care: a scientific statement from the American Heart Association. *Circulation.* 2017; 135(25):e1145–e1158.
- Dranishnikov N, Stepanenko A, Potapov EV, Dandel M, Siniawski H, Mladenow A, et al. Simultaneous aortic valve replacement in left ventricular assist device recipients: single-center experience. *Int J Artif Organs.* 2012; 35(7):489–94.
- Meineri M, Van Rensburg AE, Vegas A. Right ventricular failure after LVAD implantation: prevention and treatment. *Best Pract Res Clin Anaesthesiol.* 2012; 26(2):217–29.
- Truby LK, Garan AR, Givens RC, Wayda B, Takeda K, Yuzefpolskaya M, et al. Aortic insufficiency during contemporary left ventricular assist device support: analysis of the INTERMACS registry. *JACC Heart Fail.* 2018; 6(11):951–60.
- Lima B, Chamogeorgakis T, Mountis M, Gonzalez-Stawinski GV. Replacement of the aortic valve with a bioprosthesis at the time of continuous flow ventricular assist device implantation for preexisting aortic valve dysfunction. *Proc (Bayl Univ Med Cent).* 2015; 28(4):454–6.
- Feldman CM, Silver MA, Sobieski MA, Slaughter MS. Management of aortic insufficiency with continuous flow left ventricular assist devices: bioprosthetic valve replacement. *J Heart Lung Transplant.* 2006; 25(12):1410–2.
- Goda A, Takayama H, Pak SW, Uriel N, Mancini D, Naka Y, et al. Aortic valve procedures at the time of ventricular assist device placement. *Ann Thorac Surg.* 2011; 91(3):750–4.

Имплантација уређаја за механичку циркулаторну потпору леве коморе и придружена замена аортне валвуле

Александар Микић^{1,2}, Емилија Несторовић², Илија Билбија^{1,2}, Душко Терзић², Светозар Путник^{1,2}

¹Универзитет у Београду, Медицински факултет, Београд, Србија;

²Клинички центар Србије, Клиника за кардиохирургију, Београд, Србија

САЖЕТАК

Увод Имплантабилни уређаји за механичку потпору циркулације леве коморе (LVAD) широко се користе као терапијска опција за преживљавање и побољшање квалитета живота болесника са терминалном срчаном слабашћу.

Циљ рада је презентација имплантације уређаја за трајну механичку циркулаторну потпору леве коморе уз замену аортне валвуле у истој процедури.

Приказ болесника Болесник је хоспитализован у терминалном стадијуму срчане инсуфицијенције са ејекционом фрак-

цијом од 18%. Ергоспирометријски тест је показао максимум VO_2 од 10,1 ml/kg/min. С обзиром на то да медикаментозна терапија није дала задовољавајуће резултате, уграђен је LVAD као мост до трансплантације срца. Због значајне аортне инсуфицијенције валвула је замењена биопротезом да би се спречио неповољни утицај на рад пумпе и клинички исход.

Закључак Имплантација LVAD-а уз корекцију значајне аортне инсуфицијенције је процедура са задовољавајућим краткорочним и дугорочним резултатима.

Кључне речи: срчана слабост; LVAD; аортна валвула