

## CASE REPORT / ПРИКАЗ БОЛЕСНИКА

# Extraskeletal Ewing sarcoma in the anterior abdominal wall

Dorđe Savić<sup>1,2</sup>, Slaviša M. Đuričić<sup>1,3</sup>, Maja Miličković<sup>1,2</sup>, Dragomir Đokić<sup>1</sup>, Blagoje Grujić<sup>1,2</sup>, Miroslav Vukadin<sup>1</sup>, Gordana Samardžija<sup>1</sup>

<sup>1</sup>Mother and Child Health Care Institute of Serbia "Dr Vukan Čupić", Belgrade, Serbia;

<sup>2</sup>University of Belgrade, Faculty of Medicine, Belgrade, Serbia;

<sup>3</sup>University of Banja Luka, Faculty of Medicine, Banja Luka, Republic of Srpska, Bosnia and Herzegovina



## SUMMARY

**Introduction** Extraskeletal Ewing sarcoma (ES) is a highly malignant neoplasm occurring most commonly in the thoracic wall and the paravertebral region. ES belongs to the group of small round cell tumors and displays pathognomonic structural abnormalities of the *EWS* gene.

The aim of this article was to present extraskeletal ES in an extremely rare anatomic location, an unusual clinical presentation, and modified treatment strategy.

**Case outline** A 15-year-old boy was admitted to the hospital with acute abdominal pain in the right iliac region. During urgent operation, because of suspected appendicitis with periappendicular infiltrate, partly hemorrhagic tumor tissue was discovered in the preperitoneal space. Histopathological and immunohistochemical analyses revealed a tumor resembling extraskeletal ES. A postoperative CT scan showed the tumor rest, which was completely removed in the second operation. Molecular genetic analysis confirmed extraskeletal ES by finding the *EWSR1-FLI1* fusion gene. Chemotherapy and radiotherapy according to the VAC protocol were started, and the patient is free of the disease eight months after the first operation.

**Conclusion** Our case is the fourth case of extraskeletal ES located in the abdominal wall, the second case confirmed by the molecular genetic finding, and the first case described in children at this anatomic site. Due to an extremely rare location, unusual clinical presentation, and needed genetic analysis, the tumor treatment strategy was modified with good short-term results.

**Keywords:** extraskeletal Ewing sarcoma; primitive neuroectodermal tumor; soft tissue; abdominal wall; surgery

## INTRODUCTION

Ewing sarcoma (ES) is an uncommon neoplasm, with an incidence reported at one to three per million people per year, mainly appearing in patients younger than 20 years, with peak incidence during the second decade of life. After osteosarcoma, ES is the second most common bone sarcoma in children and young adults, with slight male predominance. About 10–20% of cases arise in extraskeletal sites, most commonly in the soft tissue of the thoracic wall, paravertebral region, lower extremities, head, neck, and pelvis [1, 2].

ES belongs to a group of small, round cell tumors. It shows a varying degree of neuroectodermal differentiation, and typically demonstrates diffuse membranous immunohistochemical CD99 positivity. The cells of origin of ES are either neural crest-derived stem cells or mesenchymal stem cells. Most of the ES harbor a somatic reciprocal chromosomal translocation, t(11;22)(q24;q21), which results in pathognomonic fusion of *EWSR1* to *FLI1* genes, generating the *EWSR1-FLI1* oncoprotein. In about 15% of ES, the *EWSR1* gene can be involved in alternative translocations with *ERG*, *ETV1*, *ETV4*, or *FEV* genes [1, 2].

The term ES comprises tumor entity formerly differentiated into classical bone ES, Askin's tumor of the chest wall, and peripheral neuroectodermal tumor (PNET). Formerly, PNET had been defined as ES with more prominent neural differentiation, predominant extraskeletal location, and closely related with central nervous system PNETs [2, 3]. This is why some authors still use the term ES/PNET for this group of neoplasms.

The aim of this work was to present a case of a 15-year-old boy with extraskeletal ES/PNET in an extremely rare anterior abdominal wall location, unusual clinical presentation, and modified strategy of treatment.

## CASE REPORT

A 15-year-old boy was admitted to our department as an emergency case with acute abdominal pain that started on the previous day after he took part in a football match. There was no clear evidence of trauma. Clinical examination revealed a painful mass in the right iliac region. Ultrasound examination confirmed the existence of well-localized hyperechogenic mass, with smaller hypoechogenic zones inside, mea-

**Received • Примљено:**  
March 23, 2017

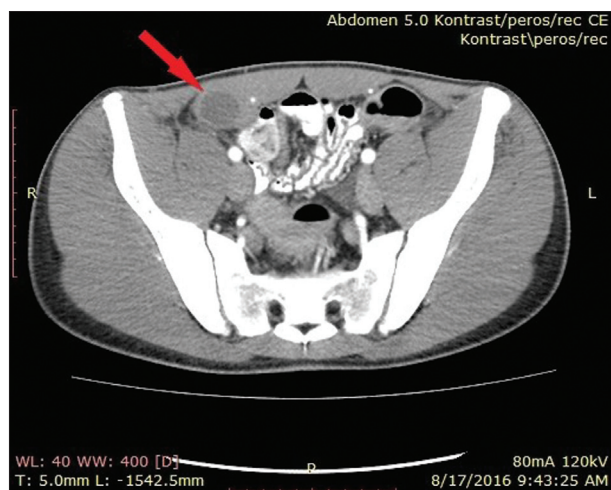
**Revised • Ревизија:**  
May 30, 2017

**Accepted • Прихваћено:**  
May 31, 2017

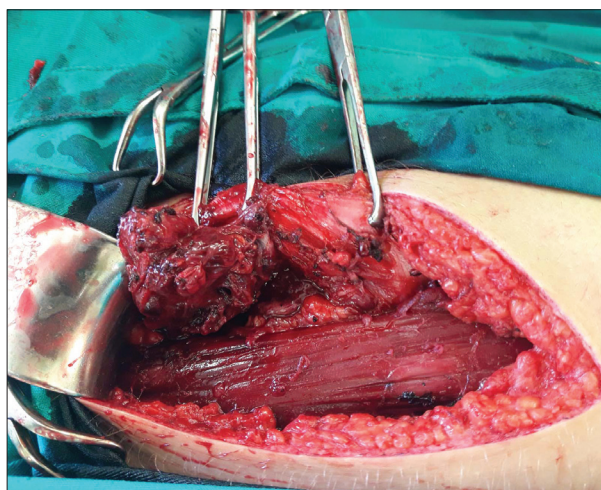
**Online first:** June 6, 2017

## Correspondence to:

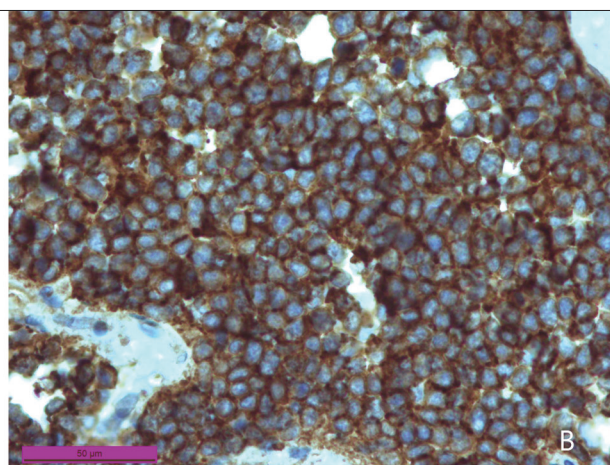
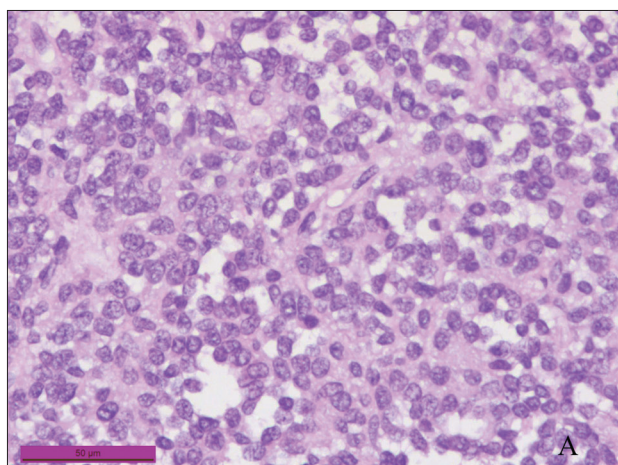
Dorđe SAVIĆ  
Mother and Child Health Care  
Institute of Serbia "Dr Vukan  
Čupić"  
Belgrade 11000  
Serbia  
[savic.60.djordje@gmail.com](mailto:savic.60.djordje@gmail.com)



**Figure 1.** CT finding of the tumor in the abdominal wall



**Figure 2.** Intraoperative finding of ES/PNET beyond rectus abdominis muscle



**Figure 3.** Microscopic features of the tumor tissue; A) typical characteristics of the small round cell tumor in childhood; B) intense CD99 immunopositivity of all tumor cells indicating the extraskeletal Ewing sarcoma

measuring 50 × 40 mm, without internal color Doppler signal, which could resemble periappendicular infiltrate. There were neither any changes in the abdominal organs nor enlarged lymphatic nodes. Abdominal plain radiography was normal. Moderate leukocytosis ( $12.6 \times 10^9/L$ ) was present, and all other standard hematological and biochemical analyses were within normal ranges. The patient had no previous diseases, and there were no significant data in the family history, including the absence of malignancies.

Because of the persistence of the right iliac tenderness, with the suspicion of periappendicular inflammatory infiltrate, the patient was operated on on the same day, using the McBurney incision. After the division of muscular layers, in the preperitoneal fat tissue, a large amount of mushy semiliquid hemorrhagic masses with tissue parts appeared. The visible mass was removed and sent to histopathological (HP) examination. There was a clinical suspicion of an old abdominal wall hematoma, considering the patient's intense sports activities (football training and matches). Microbiological culture of the tissue revealed no growth of microorganisms. The patient's recovery was uneventful.

HP examination revealed necrotic tissue, with inflammatory component and hemorrhage, but parts of viable

tumor tissue were also found. Small round tumor cells were hyperchromatic with a lack of cytoplasm, forming pseudorosettes, and showing numerous mitoses and apoptoses. Immunohistochemistry revealed strong positive membranous staining for CD99, partly on vimentin and sporadically on synaptophysin, and negative staining for the leukocyte common antigen, desmin, myogenin, epithelial membrane antigen, CD68, chromogranin, and Wilms tumor-1 antigen (WT-1). Results of immunostaining with anti-FLI1 antibody were assessed as unreliable. The pathologists' conclusion was that mostly necrotic small round cell malignant tumor had immunohistochemical characteristics that typically indicate ES/PNET. It was emphasized that genetic analyses are necessary for an accurate definitive diagnosis. The tissue sample was sent to a foreign medical institution for these analyses. It took a relatively long time to obtain the genetic results. In the meantime, computed tomography (CT) showed a partly solid, partly cystic heterodense mass measuring  $3.8 \times 2.6 \times 3.7$  cm beside and beyond the right rectus muscle. There were changes neither in the intraperitoneal lymphatic nodes and abdominal organs nor in the thoracic cavity (Figure 1). A new operation was undertaken. A partly colliquated

tumor, measuring 4 cm, was found close to the rectus abdominis muscle, not infiltrating the muscle but infiltrating the underlying peritoneum (Figure 2). The whole tumor was removed with underlying peritoneum. It was obvious that the tumor generated from preperitoneal fat tissue. The recovery was uneventful. The new HP analysis confirmed the high probability of ES/PNET, and the reverse transcriptase polymerase chain reaction analysis of the tumor specimen confirmed the *EWSR1-FLI-1* transcript, so the diagnosis of extraskelatal ES in the anterior abdominal wall was proved (Figure 3). The tumor process was classified as the second stage. The boy received six courses of chemotherapy according to CWS protocol from 2012, consisting of ifosfamide, vincristine, and doxorubicin and is now on radiotherapy regimen. The patient has neither clinical nor CT scan evidence of tumor recurrence or metastatic spreading eight months after the initial surgical treatment, but further follow-up will show the overall result of the treatment.

## DISCUSSION

Histopathological aspect, immunohistochemical profile, and, especially, genetic finding of *EWSR1-FLI-1* fusion gene indicate extraskelatal ES in our patient. Some cases of ES have been reported in patients between 14 months and 77 years of age, but peak incidence is during the second decade of life, as was in our patient [1, 2].

Anatomic site of extraskelatal ES in the preperitoneal fat tissue of the abdominal wall in our patient is exceptionally rare, considering that the most common locations of this highly aggressive neoplasm are the thoracic wall, paravertebral region, lower extremities, head, neck and pelvic region [1, 2]. However, there are several case reports or small series of extraskelatal ES/PNET with primary location in the kidney, lung, pancreas, uterus, urinary bladder, ovary, testis, parotid gland, mesenterium, skin, and subcutaneous tissue [4, 5]. After an extensive literature search on the PubMed, using keywords "Ewing sarcoma," "primitive neuroectodermal tumor," and "abdominal wall," we found only three cases of neoplasms in this primary location [6, 7, 8]. Another three cases of extraskelatal ES in the abdominal wall location were reported, but all of them were described as tumors confined to the subcutaneous adipose tissue, so we consider that they should not be included in the group of abdominal wall neoplasms [4, 9, 10].

To the best of our knowledge, the first case of extraskelatal ES in the abdominal wall was reported by Aydinli et al. [6] in 2006. They described a 65-year-old male patient with a painless mass, measuring 5 cm in diameter, in the left upper quadrant of the abdominal wall, infiltrating the left rectus muscle. After probably complete tumor resection, the chemotherapy was carried out including vincristine, doxorubicin, cyclophosphamide, and etoposide for six cycles, and the patient had no evidence of tumor recurrence during a one-year follow-up. The second case was extraskelatal ES with the largest diameter of 6.5 cm, involving the left anterolateral muscle group of the abdominal wall in a 35-year-old woman. After the diagnostic incisional

biopsy, neoadjuvant chemotherapy was started including vincristine, cyclophosphamide, and Adriamycin for three cycles. Because of poor response to chemotherapy, surgery was required, but authors did not report any data of the follow-up [7]. Roncati et al. [8] reported a third case of small extraskelatal ES/PNET measuring 1.5 cm, located in the subcutaneous tissue with deep muscle infiltration, appearing in a 45-year-old man. After elemental microanalysis, the authors described findings of a heavy metal bioaccumulation into the tumor cells, correlating with the chronic exposure to a transdermal delivery of heavy metal salts during local therapy of the irritated skin. Common *EWSR1-FLI-1* translocation was also found, and after a complete tumor excision and chemotherapy, the patient was without tumor recurrence one year after surgery [8].

Our case is the fourth case of extraskelatal ES located in the abdominal wall, the second case confirmed by the molecular genetic finding of characteristic structural abnormality of the *EWS* gene on 22q12, and the first case described in children in this anatomic location.

Extraskelatal ES/PNET has a high malignant potential. Kushner et al. [11], on a series of 43 patients without distant metastases at the time of diagnosis, reported the tumor recurrence rate of 25% during the first 24 months. Another 11 patients had metastases at the time of the diagnosis. Kimber et al. [12], on a series of 26 patients, reported an overall survival rate of 42%, while Zimmermann et al. [13] reported survival rate of 53% on a series of 13 patients. Sarkar and Bähr [14] made a meta-analysis and reported an overall number of 102 patients with Askin tumor, with a mortality rate of 41%, and the recurrence rate of 14% in the follow-up period in survivors. The treatment of ES/PNET consists of surgery, chemotherapy and radiotherapy [15–18]. There are controversies in the literature about the timing of the operative treatment, but nowadays the majority of authors prefer pre-operative chemotherapy, with tumor regression in up to 95% of the cases, enabling surgeons a radical tumor excision, without spilling and disseminating tumor cells. The initial surgery, if undertaken, must not be mutilated or too risky if the tumor infiltrates adjacent organs or vascular structures [15, 16, 17]. We believe that initial surgery should be performed and the tumor removed, if imaging methods indicate that adjacent organs are not infiltrated, as was in our patient. Even after successful radical surgery, postoperative chemotherapy and radiotherapy must be performed, because extraskelatal ES/PNET carries a great risk of local recurrence and distant metastases. The operation must be performed even if preoperative chemotherapy has achieved complete tumor regression, in order to remove scattered viable malignant cells [12].

In our patient, extraskelatal ES was located in the preperitoneal fat tissue, manifested by spontaneous pain and tenderness on examination in the right iliac region, the symptom and sign quite unusual for malignant tumors. The initial operation had been performed under suspicion of acute abdominal disease, i.e. for acute appendicitis with periappendicular infiltrate formation. The second operation was undertaken before the chemotherapy regimen started,

because of the delay in obtaining molecular genetic analysis results needed for the accurate diagnosis. The standard therapy protocol could have been changed because imaging analyses indicated the possibility of radical surgery.

In this paper, an extremely rare case of extraskeletal ES with primary location in the abdominal wall is presented.

## REFERENCES

- De Alava E, Lessnick SL, Sorensen PH. Ewing sarcoma. In: Fletcher CDM, Bridge JA, Hogendoorn PCW, Mertens F, editors. World Health Organization Classification of Tumours of Soft Tissue and Bone. IARC Press, Lyon: 2013; 306–9.
- Potratz J, Dirksen U, Jurgens H, Craft A. Ewing sarcoma: clinical state-of-the-art. *Pediatr Hematol Oncol.* 2012; 29(1):1–11.
- Batsakis JG, El-Naggar AK. Ewing's sarcoma and primitive neuroectodermal tumours: cytogenetic cytoses seeking a common histogenesis. *Adv Anat Pathol.* 1997; 4:207–20.
- Betal D, Shaygi B, Babu R, Jamil K, Sainsbury RJ. Primitive neuroectodermal tumour (PNET) in subcutaneous abdominal wall: a case report. *Intern Sem Surg Oncol.* 2009; 6:10.
- Marić H, Cvijanović R, Ivanov I, Gvozdenović L, Ivanov D, Lalović N. Peripheral primitive neuroectodermal tumor of the small bowel mesentery – report of a case. *Srp Arh Celok Lek.* 2015; 143(9-10):619–22.
- Aydinli B, Ozturk G, Yildirman MI, Polat Yalcin K, Basoglu M, Gundogdu C, et al. Extraskeletal Ewing's sarcoma in the abdominal wall: a case report. Letter to the editor. *Acta Oncol.* 2006; 45(4):484–6.
- Askri A, Ben Farhat L, Ghariani B, Rabeh A, Dali N, Said W, et al. Extraskeletal Ewing sarcoma of the abdominal wall. *Cancer Imaging.* 2008; 8:156–8.
- Roncati L, Gatti AM, Capitani F, Barbolini G, Maiorana A, Palmieri B. Heavy metal bioaccumulation in an atypical primitive neuroectodermal tumor of the abdominal wall. *Ultrastruct Pathol.* 2015; 39(4):286–92.
- Somers GR, Shago M, Zielenska M, Chan HS, Hgan BY. Primary subcutaneous primitive neuroectodermal tumor with aggressive behavior and an unusual karyotype: case report. *Pediatr Dev Pathol.* 2004; 7(5):538–45.
- Taylor GB, Chan YF. Subcutaneous primitive neuroectodermal tumour in the abdominal wall of a child: long-term survival after local excision. *Pathology.* 2000; 32(4):294–8.
- Kushner BH, Hajdu SI, Gulati SC, Erlandson RA, Exelby PR, Lieberman PH. Extracranial primitive neuroectodermal tumors: the Memorial Sloan-Kettering Cancer Center experience. *Cancer.* 1991; 67(7):1825–9.
- Kimber C, Michalski A, Spitz L, Pierro A. Primitive neuroectodermal tumors: anatomic location, extent of surgery, and outcome. *J Pediatr Surg.* 1998; 33(1):39–41.
- Zimmermann T, Blütters-Sawatzki R, Flechsenhar K, Padberg WM. Peripheral primitive neuroectodermal tumor: challenge for multimodal treatment. *World J Surg.* 2001; 25(11):1367–72.
- Sarkar MR, Bähr R. Der Askin-Tumor. *Chirurg.* 1992; 63:973–6.
- Bernstein M, Kovar H, Paullusen M, Randall RL, Schucke A, Teot LA, et al. Ewing's sarcoma family of tumors: current management. *The Oncologist.* 2006; 11(5):503–19.
- Vukašinić Z, Stevanović V, Spasovski D, Živković Z. Savremeno shvatanje Juingovog (Ewing) sarkoma. *Srp Arh Celok Lek.* 2006; 134(7-8):348–55.
- Marinova L. Retroperitoneal primitive neuroectodermal tumour (PNET). A case report and review of the literature. *Rep Pract Oncol Radiother.* 2009; 14(6):221–4.
- Soma S, Shetty SK, Bhat S. PNET of the Abdominal Wall: A Rare Presentation. *J Clin Diagn Res.* 2015; 9(8):XD01–XD02.

## Екстраскелетни Јуингов сарком у предњем трбушном зиду

Ђорђе Савић<sup>1,2</sup>, Славиша М. Ђуричић<sup>1,3</sup>, Маја Миличковић<sup>1,2</sup>, Драгомир Ђокић<sup>1</sup>, Благоје Грујић<sup>1,2</sup>, Мирослав Вукадин<sup>1</sup>, Гордана Самарџија<sup>1</sup>

<sup>1</sup>Институт за здравствену заштиту мајке и детета Србије „Др Вукан Чупић“, Београд, Србија;

<sup>2</sup>Универзитет у Београду, Медицински факултет, Београд, Србија;

<sup>3</sup>Универзитет у Бањој Луци, Медицински факултет, Бања Лука, Република Српска, Босна и Херцеговина

### САЖЕТАК

**Увод** Екстраскелетни Јуингов сарком (ЈС) веома је малигна неоплазма која се најчешће развија у зиду грудног коша и паравертебралној регији. Спада у групу тумора малих округлих ћелија са патогномичном структурном абнормалношћу гена *EWS*.

Циљ овог рада је да прикаже случај екстраскелетног ЈС са изузетно ретком локализацијом, необичном клиничком презентацијом и модификованом стратегијом лечења.

**Приказ болесника** Дечак стар 15 година примљен је у болницу због акутног абдоминалног бола у десној илијачној регији. У току хитне операције због сумње на апендицитис са периапендикуларним инфилтратом, у преперитонеалном простору је нађено делимично хеморагично туморско ткиво. Патохистолошка и имунохистохемијска анализа указале су на вероватни екстраскелетни ЈС. Постоперативна КТ указала је на локални остатак тумора, који је комплетно

одстрањен другом операцијом. Молекуларно-генетичким налазом фузионог гена *EWSR1-FLI1* потврђена је дијагноза екстраскелетног ЈС. Лечење је настављено хемиотерапијом и радиотерапијом по *VAC* протоколу и осам месеци после прве операције код болесника нема знакова рецидива болести.

**Закључак** Екстраскелетни ЈС у предњем трбушном зиду код нашег болесника представља четврти случај ЈС на тој локализацији приказан у литератури, од тога други случај са дијагнозом потврђеном молекуларно-генетичком анализом и први описан у дечјем узрасту. Због екстремно ретке локализације, необичне презентације и неопходне генетичке анализе, стратегија лечења тумора је модификована са добрим краткорочним резултатом.

**Кључне речи:** екстраскелетни Јуингов сарком; примитивни неуроектодермални тумор; мека ткива; трбушни зид; хирургија