

Unilateral Adie's Tonic Pupil and Viral Hepatitis – Report of Two Cases

Jelena Karadžić¹, Natalija Jaković^{1,2}, Igor Kovačević^{1,2}

¹Clinic for Eye Diseases, Clinical Center of Serbia, Belgrade, Serbia;

²University of Belgrade, School of Medicine, Belgrade, Serbia

SUMMARY

Introduction Adie's (tonic) pupil is a neuro-ophthalmological disorder characterized by a tonically dilated pupil, which is unresponsive to light. It is caused by damage to postganglionic fibers of the parasympathetic innervation of the eye, usually by a viral or bacterial infection. Adie's syndrome includes diminished deep tendon reflexes.

Outline of Cases We report data of a 59-year-old female with unequal pupil sizes. She complained of blurred vision and headache mainly while reading. She had a 35-year history of hepatitis B and liver cirrhosis. On exam, left pupil was mydriatic and there was no response to light and at slit lamp we saw segments of the sphincter constrict. We performed 0.125% pilocarpine test and there was a remarkable reduction of size in the left pupil. The second case is a 55-year-old female who was referred to the University Eye Clinic because of a headache and mydriatic left pupil. She had diabetes mellitus type 2, as well as hepatitis A virus 20 years earlier. On exam, the left pupil was mydriatic, with no response to light. Test with diluted pilocarpine was positive. Neurological examinations revealed no abnormality in either case so we excluded Adie's syndrome.

Conclusion Adie's tonic pupil is benign neuro-ophthalmological disorder of unknown etiology. Most patients commonly present no symptoms and anisocoria is noticed accidentally. Although the etiology is unknown, there are some conditions that cause tonic pupil. It may be a part of a syndrome in which tonic pupil is associated with absent deep tendon reflexes.

Keywords: Adie's tonic pupil; viral hepatitis; Adie's syndrome

INTRODUCTION

Adie's tonic pupil, also known as Holmes-Adie's tonic pupil, is a neuro-ophthalmological disorder characterized by tonically dilated pupil, which is unresponsive to light and is moderately responsive to accommodation [1]. It is caused by damage to postganglionic fibers of the parasympathetic innervation of the eye, usually by a viral or bacterial infection which causes inflammation, and affects the pupil of the eye and the autonomic nervous system. Adie's tonic pupil is typically unilateral at first and is found most often in young women [2, 3]. Diagnostic features of a tonic pupil are pupillary light-near dissociation and slow redilatation after near effort. Slit-lamp evaluation reveals sectorial vermiform movements which represent sectorial pupillary paralysis [3]. Adie's syndrome has other features including diminishing deep tendon reflexes in nearly 90% of patients. Most often, knee or ankle jerks are involved, but occasionally arm reflexes are also depressed [2]. The eye and reflex symptoms may not appear at the same time. People with Adie's syndrome may also sweat excessively, sometimes only on one side of the body. The combination of these three symptoms – abnormal pupil size, loss of deep tendon reflexes and excessive sweating – is usually called Ross's syndrome, although some doctors will still diagnose the condition as a variant of

Adie's syndrome [4]. The prevalence of Adie's pupil is about two cases per 1,000 population. Although patients of all ages are affected, the mean age is 32 years, and there is a female predominance (2.6:1) for the idiopathic variety (Adie's tonic pupil) [5]. Trauma is the most common cause of a tonic pupil. Other causes associated with tonic pupils include viral illness, diabetes, syphilis and giant cell arteritis. When the etiology cannot be identified, particularly in young females, the condition is termed Adie's tonic pupil [6].

CASE REPORTS

Case 1

We present data of a 59-year-old Caucasian female who was referred to the University Eye Clinic, Clinical Center of Serbia, with unequal pupil sizes. This finding was detected during routine ophthalmological examination. She complained of blurred vision and headaches, mainly manifested while reading. She had a 35-year history of chronic hepatitis B and subsequent liver cirrhosis, developed after blood transfusion. No other positive findings for local or systemic inflammation or any other disease were found. No anamnesis of recent or old traumas, or complaints of any kind. Family eye or systemic disorders anamneses were

Correspondence to:

Jelena KARADŽIĆ
Clinic for Eye Diseases
Clinical Centre of Serbia
Pasterova 2, 11000 Belgrade
Serbia
bkjelena@gmail.com

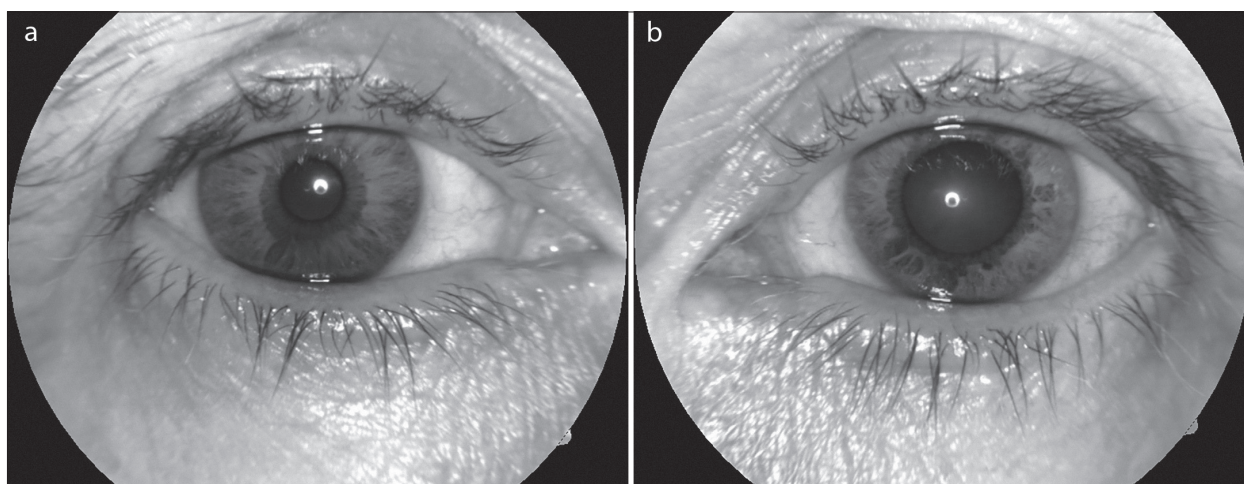


Figure 1. Slit lamp photography of right (a) and left eye (b); left pupil is mydriatic and round in shape

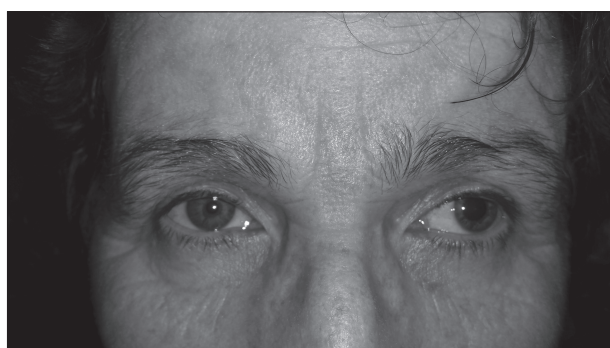

Figure 2. A 59-year-old female presenting with asymmetric pupils

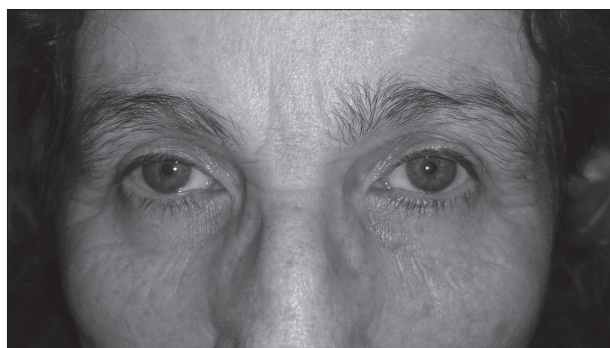

Figure 3. Photograph taken after pilocarpine 0.125% test: a significant response in the left pupil with remarkable reduction of its size, while the normal, right pupil does not constrict with this dilute dose of pilocarpine

negative. Patient underwent complete ophthalmological and neuro-ophthalmological examination at baseline including medical history, visual acuity assessment (measured by Snellen chart), applanation tonometry, slit lamp examination, indirect ophthalmoscopy with 90D lens, optical coherence tomography, fundus photography and immunological and biochemical investigation. Admission visual acuity on both eyes was 1.0 and intraocular pressure was within range. In the neurological examination, left pupil was mydriatic (of about 5 mm) and round in shape and the right pupil was midsize (3.5 mm) (Figures 1 and 2). There was no response to light in the left pupil. At slit lamp, we saw segments of the sphincter constrict (ver-

form movements). No abnormalities in the eye movement as well as during fundus examination were detected. In the examination of near reflex, the size of the left pupil reduced slowly but not completely. The results of perimetry and visual acuity examination were normal. In the 0.125% pilocarpine test there was a significant response in the left pupil with remarkable reduction of its size to about 3 mm after about 20 minutes (Figure 3), while the normal pupil did not constrict with this dilute dose of pilocarpine. The positivity of pilocarpine test confirmed the diagnosis of Adie's tonic pupil. Neurologic and internist consultations were obtained. Tumor, actual infection, ischemic disease, trauma and mechanical compression were excluded. Neurological examinations revealed no abnormality. Deep tendon reflexes were normal in all extremities. Cell count, sedimentation rate and routine blood chemistries were normal. Brain magnetic resonance imaging and angiography showed no abnormality.

Case 2

The second case we present is a 55-year-old Caucasian female who was referred to University Eye Clinic, Clinical Center of Serbia, because of headaches that occurred while reading and because of unequal pupil size for about 10 months. She had had transient unilateral mydriasis a few weeks before the anisocoria become persistent. She had a history of hepatitis A virus 20 years ago, and she had been diagnosed diabetes mellitus type 2 six months previously. There was no anamnesis of recent or old trauma. On the examination, her left pupil was mydriatic (of about 6 mm), round in shape and sluggishly reactive to light, while the right pupil was midsize (3.5 mm), reactive to light. At slit lamp, we saw segments of the sphincter constrict (ver-

this dilute dose of pilocarpine. Neurologic and internist consultation was obtained. Neurological examinations revealed no abnormality. Deep tendon reflexes were normal in all extremities. Internist examination revealed regulated diabetes mellitus type 2 with an oral antiglycemic and hypertension.

DISCUSSION

Adie's tonic pupil is a neuro-ophthalmological disorder of unknown etiology. Seventy percent of patients are female. The pupillary condition is unilateral in 80% of cases [2, 3]. In Adie's pupil, denervation of postganglionic parasympathetic fibers occurs, leading to a supersensitive response to weak cholinergic agonists (e.g. pilocarpine, 0.125%). Sometimes it may be a part of the Holmes-Adie's syndrome, in which tonic pupil is associated with absent or reduced deep tendon reflexes [7]. Any damage to postganglionic parasympathetic fibers can lead to manifestations of Adie's pupil [8]. The most common causes are idiopathic, but also orbital trauma or infection, herpes zoster infection, viral hepatitis, autonomic neuropathies, Guillain-Barré syndrome, inflammation, autoantibodies, dysautonomia (as in Harlequin and Ross syndrome) or ischemia can lead to this disorder [8, 9]. Tumors, actual infection, ischemic disease, trauma or mechanical compression which can damage the ciliary ganglion, were excluded in our patients. Since no other cause of Adie's pupil had been found, it is a logical hypothesis that the neurological abnormalities including damage of postganglionic parasympathetic nerves are connected with pathomechanism characteristic features in viral hepatitis. [10]. Symptoms of Adie's tonic pupil are accommodative symptoms or photophobia, but they just as often have no symptoms and

patients commonly say that anisocoria was noticed by a friend or relative [9]. Right eyes and left eyes are involved at approximately the same rate. The incidence of the second eye involvement in unilateral cases was about 4% per year during the first decade of the disease. If this rate of the second eye involvement (4% per year) persists during subsequent decades, then most Adie's pupils will eventually become bilateral [5]. Diagnostic features of tonic pupil are minimal and amount to no reaction to light, slow constriction to convergence, and slow redilatation [3, 9]. In the initial stages, the pupil is dilated and poorly reactive. With the time, the Adie's tonic pupil gets smaller [2, 3]. In our patients, we did not find neurological disorders, so we excluded Holmes-Adie's syndrome. With diluted 0.125% pilocarpine test, we demonstrated supersensitivity to local parasympathomimetics. Almost all patients with Adie's syndrome had an accommodative paresis at the time of onset [5]. Accommodative symptoms are difficult to treat, but they usually resolve during several months of onset. We treat these patients with pilocarpine drops for photophobia caused by a dilated pupil or we prescribe glasses for near vision. Reading glasses given to a patient with a fresh Adie's pupil were soon discarded as accommodation recovered [5].

Adie's tonic pupil is benign neuro-ophthalmological disorder of unknown etiology. Most common patients are with no symptoms and anisocoria is accidentally noticed. Others have blurred near vision or photophobia. Although the etiology is unknown, there are some conditions that cause tonic pupil. Sometimes it may be part of the Holmes-Adie's syndrome, in which tonic pupil is associated with absent or reduced deep tendon reflexes [7]. Accommodative symptoms are difficult to treat, but fortunately they usually resolve spontaneously within a few months of onset [2].

REFERENCES

1. Iannetti P, Spalice A, Iannetti L, Verrotti A, Parisi P. Residual and persistent Adie's pupil after pediatric ophthalmoplegic migraine. *Pediatr Neurol.* 2009; 41:204-6.
2. Slamovits T, Hedges T, Kupersmith M, Newman N, Sadun A, Sedwick L. *Neuro-ophthalmology*. San Francisco: American Academy of Ophthalmology; 1997.
3. Kanski JJ. *Clinical Ophthalmology*. 5th ed. Philadelphia: Elsevier; 2003.
4. NINDS Holmes-Adie syndrome Information Page. National Institute of Neurological Disorders and Stroke (NINDS). February 13, 2007; [accessed 15/5/2014]. Available from: http://www.ninds.nih.gov/disorders/holmes_adie/holmes_adie.htm.
5. Thompson HS. Adie's syndrome: some new observations. *Trans Am Ophthalmol Soc.* 1977; 75:587.
6. Sowka JW, Gurwood AS, Kabat AG. *Handbook of Ocular Disease Management*. 14th ed. Review of Optometry. 2012; 148(6):Supplement; 1a-67a.
7. Tafakhori A, Aghamollaii V, Modabbernia A, Pourmahmoodian H. Adie's pupil during migraine attack: case report and review of literature. *Acta Neurol. Belg.* 2011; 111:66-8.
8. Shin RK, Galetta SL, Ting TY, Armstrong K, Bird SJ. Ross syndrome plus. Beyond Horner, Holmes Adie, and Harlequin. *Neurology.* 2000; 26:1841-6.
9. Kunitomo D, Kanitkar K, Makar M. *The Wills Eye Manual – Office and Emergency Room, Diagnosis and Treatment of Eye Disease*. 4th ed. Philadelphia: Lippincott Williams and Wilkins; 2004.
10. Csak T, Folhoffer A, Horvath A, Halasz J, Diczhazi CS, Schaff ZS, et al. Holmes-Adie syndrome, autoimmune hepatitis and celiac disease: a case report. *World J Gastroenterol.* 2006; 12(9):1485-7.

Једнострана Адијева тонична зеница и вирусни хепатитис – приказ два болесника

Јелена Караџић¹, Наталија Јаковић^{1,2}, Игор Ковачевић^{1,2}

¹Клиника за очне болести, Клинички центар Србије, Београд, Србија;

²Универзитет у Београду, Медицински факултет, Београд, Србија

КРАТАК САДРЖАЈ

Увод Адијева тонична зеница је неуроофталмолошко обољење које се одликује тоничном дилатираном зеницом. Настаје као последица оштећења постганглијских влакана парасимпатичке инервације ока, обично вирусном или бактеријском инфекцијом. Често је удружено са губитком дубоких тетивних рефлекса, и тада говоримо у Адијевом (*Adie*) синдрому.

Прикази болесника Жена стара 59 година јавила се у Клинику за очне болести Клиничког центра Србије због случајно откривене широке леве зенице, која јој није стварала проблеме с видом. Болесница је боловала од хепатитиса Б и цирозе јетре. Клинички је уочена дилатирана зеница на левом оку, која је веома тромо реаговала на светлост, а на биомикроскопу запажена је сегментна констрикција руба зенице. Добијен је позитиван пилокарпински тест с

пилокарпином у концентрацији од 0,125%. Друга болесница, стара 55 година, упућена је на Клинику за очне болести због вишемесечних главобоља и неједнаке ширине зенице. Анамнестички је добијен податак о *de novo* откривеној шећерној болести и о прележаном хепатитису А двадесет година раније. Клинички је уочена проширена, тромо реактивна лева зеница која је позитивно одреаговала на тест са разблаженим пилокарпином. Неуролошки налаз је у оба случаја био нормалан, чиме смо искључили Адијев синдром.

Закључак Адијева тонична зеница је неуроофталмолошко обољење непознате етиологије које се чешће јавља код жена средње животне доби, а код 80% болесника је на једном оку. Често је удружено са губитком дубоких тетивних рефлекса, када говоримо у Адијевом синдрому.

Кључне речи: тонична зеница; вирусни хепатитис; Адијев синдром

Примљен • Received: 20/05/2014

Прихваћен • Accepted: 03/07/2014