

CASE REPORT / ПРИКАЗ БОЛЕСНИКА

Dysgerminoma and pregnancy

Jasmina Popović^{1,2}, Sonja Pop-Trajković^{1,2}, Milan Stefanović^{1,2}, Milan Trenkić^{1,2}, Aleksandra Aracki-Trenkić³¹Clinical Center of Niš, Department of Obstetrics and Gynecology, Niš, Serbia;²University of Niš, Faculty of Medicine, Niš, Serbia;³Clinical Center of Niš, Department of Radiology, Niš, Serbia**SUMMARY**

Introduction Dysgerminomas are germ cell ovarian tumors. They affect young females, prevalently during childhood. The problem arises when dysgerminoma is diagnosed in women of reproductive age who have never given birth and require a surgical procedure.

Case outline A 28-year-old patient was admitted to hospital in week 26 of her first pregnancy. The reason for patient hospitalization was the growth of the isthmic myoma diagnosed by her obstetrician-gynecologist in the primary care unit. By examining the medical history of the patient, the following was revealed: A year and a half before pregnancy she was diagnosed with left ovary dysgerminoma. The patient's medical history led us to conclude that uterine myoma was a misdiagnosis and that the actual diagnosis was dysgerminoma of the right ovary. The surgery was performed after the fetal viability had been achieved.

Conclusion Malignant ovarian tumours may occur in young women during pregnancy and increase in size significantly in a short period of time, although their recurrence is not expected in such a short period of time after surgical treatment. This poses a great challenge for obstetricians.

Keywords: dysgerminoma; malignant; ovarian germ cell tumor; pregnancy

INTRODUCTION

Dysgerminomas are germ cell ovarian tumors. About 20% of all ovarian tumors originate from germ cells, whereas only 3% of them are malignant. Dysgerminomas account for about 1% of all germ cell tumors but they are frequently malignant [1]. They affect young females, prevalently during childhood, and the vast majority of them need and respond well only to chemotherapy. The problem arises when dysgerminoma is diagnosed in women of reproductive age who have never given birth and require a surgical procedure. A more serious situation occurs if dysgerminomas develop in young patients during pregnancy, which poses many medical and ethical dilemmas. We present a case of a young patient with a previous history of a dysgerminoma managed by left adnexectomy. The patient conceived two years after the surgery. However, a dysgerminoma of the right ovary was diagnosed in the sixth month of pregnancy. The surgery was performed after the fetal viability had been achieved.

CASE REPORT

A 28-year-old patient was admitted to hospital in week 26 of her first pregnancy. The reason for hospitalization was the growth of the isthmic myoma diagnosed by her obstetrician-gynecologist in the primary care unit. Ultrasonography revealed a viable pregnancy at

24 weeks of gestation and a solid mass of uncertain origin, 100 × 100 mm in size, detected on the right side of the uterus. An ultrasound examination performed four weeks earlier showed a mass 60 × 60 mm in size.

By examining the medical history of the patient, the following was revealed: a year and a half before pregnancy, the patient was diagnosed with a left ovary dysgerminoma. She had undergone left adnexectomy and the partial resection of the right ovary. Dysgerminoma with a negative immunoprofile (alpha-fetoprotein, inhibin, and epithelial membrane antigen) and a positive immunoprofile of the tumor (reticulin and a high level of Ki67) was confirmed by histopathology. The pathology of a part of the right ovary showed only corpus luteum. The surgery was the only management option. The control ultrasound as well as tumor markers six months before pregnancy were normal. The patient's history led us to conclude that uterine myoma was a misdiagnosis and that the actual diagnosis was dysgerminoma of the right ovary. The laboratory findings were as follows: D-dimer 5,022 ng/mL, lactate dehydrogenase 12,715 IU/L, aspartate transaminase 95 U/L, alanine transaminase 174 U/L. The magnetic resonance imaging (MRI) finding in week 27/28 of the pregnancy showed a giant tumor in the pelvis, 200 × 200 mm in size, ascites, lymphomegaly, and bilateral hydroureteronephrosis (Figure 1). The pregnancy was terminated at week 31/32 of gestation by Caesarean section and a viable preterm female baby was

Примљено • Received:
September 23, 2016

Ревизија • Revised:
December 8, 2016

Прихваћено • Accepted:
December 8, 2016

Online first: March 17, 2017

Correspondence to:

Milan TRENKIĆ
Sterijina 32
18000 Niš, Serbia
trenkic@gmail.com

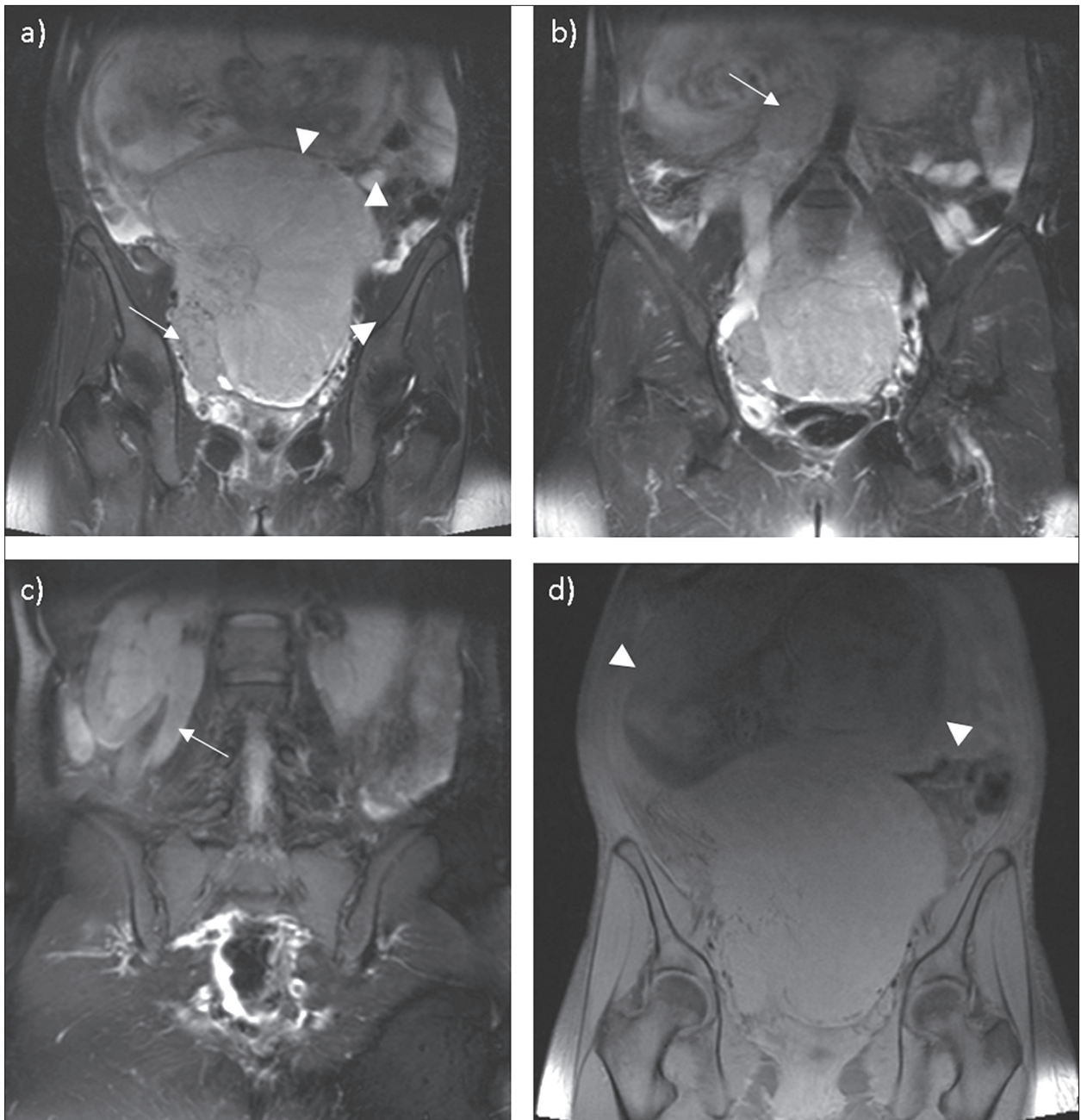


Figure 1. Pelvic MRI; coronal reconstructed T2-weighted images show: a) a large intermediate signal solid mass with prominent fibrovascular septa, occupied pelvic cavity with upward extension into abdominal cavity (arrowhead); in the caudal part of the mass another lobulated mass corresponding to a conglomerate of lymph nodes is shown (arrow); b) para-aortic lymph node mass (arrow); c) mass effect on adjacent structures with consequent hydronephrosis; the diameter of the ureter measured up to 13 mm (arrow); d) coronal fat-saturated T1-weighted image shows the displacing of fetus cranially (arrowhead)

born with birth weight of 1,630 g and the Apgar score of 7/10, 8/10 at the first and fifth minute of life, respectively. Afterwards, the total abdominal hysterectomy with right adnexectomy, omentectomy, para-aortic, iliac, and obturator lymphadenectomy was done. The distal part of the right ureter was also resected and the ureterocystostomy was performed. The patient subsequently underwent chemotherapy with bleomycin, etoposide, and platinum (BEP, four cycles). The patient is currently free of the disease two years post-treatment, with a healthy baby.

DISCUSSION

As mentioned above, dysgerminomas are tumors originating from the primordial ovarian germ cells. Dysgerminoma has a classic correlation with seminoma of the testis, having an identical histological structure. Germ cell tumors account for about 70% of ovarian neoplasm cases during the first decades of life, and are rarely found after this period [2]. Approximately 80% of cases are reported in patients under 30 years of age (mean age: 21 years), which is a finding consistent with our case.

The incidence of adnexal masses associated with pregnancy varies from 1 in 80 to 1 in 8,000 pregnancies, based on different studies. The frequency of ovarian tumors in such adnexal masses is between 1 in 80 and 1 in 2,200 pregnancies [3]. The reported rate of malignant tumors in the total number of ovarian tumors associated with pregnancy was from 1.3% to 7.9%. In fact, in a study by Ueda et al. [4], among 106 cases of ovarian tumors discovered during pregnancy, only five (4.7%) were malignant. The most common diagnosis was dermoid, while dysgerminoma was noted in only one case.

Over a 10-year period, only two cases of dysgerminoma during pregnancy have been diagnosed at our clinic, which represents less than 1% of cases. This fact may lead to a conclusion that the rate of the malignant ovarian tumors associated with pregnancy is very low. This discrepancy of ovarian malignancy incidence between pregnant and non-pregnant women can be explained by the age difference among women [5]. Most patients with a malignant ovarian tumor were over 40 years of age, and these patients were rarely pregnant. Thus, dysgerminoma may be the only malignant ovarian tumor to be kept in mind when detecting adnexal mass during pregnancy.

Taking into account the rarity of this tumor, a misdiagnosis during pregnancy is not uncommon, as it was the case here. A literature review reveals that it is not unusual to misdiagnose dysgerminoma by an ultrasound examination and diagnose uterine fibroids instead. In our case, dysgerminoma was misdiagnosed as a fibroid uterus not only by ultrasound but also by the MRI. MRI has a sensitivity of about 98% for detecting the origin of an ovarian tumour. However, there have been reports of mistaking a malignant ovarian tumor for pedunculated uterine fibroid with areas of cystic degeneration, as in our case [6]. Ovarian tumors generally remain asymptomatic, until they are discovered due to their large size or related complications.

In the current case, dysgerminoma was diagnosed as a result of the enlargement of the pelvic mass thought to be a uterine fibroid. The 14-week obstetric ultrasound showed a corpus luteum cyst in the enlarged right ovary, but all diameters were within the normal range. The 20-week obstetric ultrasound showed a pelvic mass diagnosed as uterine fibroid with a diameter of 60 mm, while the mass was twice as large four weeks later. The specialist literature indicates that certain neoplasms may undergo geometric growth of up to 20% of their original size in a very short

period of time (one to two months). The structure, consistency, and contiguity with the uterus all pointed to uterine fibroid, as was demonstrated by the ultrasound examination. For this reason, the above finding was perceived as uterine myomatosis, and if there is a suspicion of a uterine myoma in pregnancy, the diagnostic procedure is not the same as in a case of a malignant ovarian tumor, when testing for tumor markers, pelvic MRI, and other diagnostic methods are performed. Although dysgerminoma is highly suspected when a patient has phenotypic signs of certain syndromes associated to states like Cowden syndrome, ataxia telangiectasia syndrome, Swyer syndrome (pure gonadal dysgenesis associated with the XY 46 karyotype), and Apert syndrome (an autosomal dominant disorder), in this particular case, the suspicion should be based on the previous medical history of the patient [7–10].

Our patient was diagnosed with the left ovary dysgerminoma one and a half years before the pregnancy and she underwent surgery. No precise recommendations for further outpatient follow-up are known based on any randomized controlled trials. However, follow-up should maximize the ability to identify recurrences while minimizing risks. Follow-up care depends on the stage of the disease, which is typically predictive of recurrence risk. Ovarian dysgerminomas tend to recur most often in the first two to three years after treatment. Therefore, most authors suggest follow-up observation and a physical examination every three to four months for the first three years, every six months during the fourth and fifth year, and annual surveillance thereafter. Typically, the authors do not recommend any adjuvant chemotherapy for stage Ia dysgerminomas as was the case with the first surgery. Although 10–15% of stage Ia tumors may recur, essentially all of them are salvaged with chemotherapy [11]. This patient underwent all postoperative checkups. However, since she conceived afterwards, she was probably not provided with an adequate follow-up. It may also be hypothesized that pregnancy induces rapid growth of tumor, although further studies are needed to confirm the hypothesis.

By publicizing this case, we aim to raise awareness of malignant ovarian tumors possibly affecting young females in pregnancy, the volume of which may rapidly increase within a very short period of time although the recurrence of previous malignant disease is not expected in such a short period after surgery. This poses a great challenge for obstetricians.

REFERENCES

- Quirk JT, Natarajan N. Ovarian cancer incidence in the United States, 1992-1999. *Gynecol Oncol*. 2005; 97(2):519-23.
- Smith HO, Berwick M, Verschraegen CF, Wiggins C, Lansing L, Muller CY, et al. Incidence and survival rates for female malignant germ cell tumors. *Obstet Gynecol*. 2006; 107(5):1075-85.
- Akhtar K, Ahmad SS, Kumar A, Afshan N. Dysgerminoma with pregnancy and viable baby: a case report. *Oman Med J*. 2011; 26(3):198-200.
- Ueda M, Ueki M. Ovarian tumors associated with pregnancy. *Int J Gynaecol Obstet*. 1996; 55(1):59-65.
- Lee YK, Yoo CY, Lee GL, Park DC. Ovarian dysgerminoma associated with pregnancy. *Korean J Obstet Gynecol*. 2011; 54(4):218-22.
- Anwar S, Rehan B, Hameed G. MRI for the diagnosis of ultrasonographically indeterminate pelvic masses. *J Pak Med Assoc*. 2014; 64(2):171-4.
- Cho MY, Kim HS, Eng C, Kim DS, Kang SJ, Eom M, et al. First report of ovarian dysgerminoma in Cowden syndrome with germline PTEN mutation and PTEN-related 10q loss of tumor heterozygosity. *Am J Surg Pathol*. 2008; 32(8):1258-64.

8. Koksal Y, Caliskan U, Ucar C, Yurtcu M, Artac H, Ilerisoy-Yakut Z, et al. Dysgerminoma in a child with ataxia-telangiectasia. *Pediatr Hematol Oncol.* 2007; 24(6):431–6.
9. Nisolle M, Kridelka F, Fridman V, Claudot A, Lorquet S, Foidart JM. A bilateral dysgerminoma: a rare presentation of the Swyer syndrome. *Rev Med Liege.* 2005; 60(9):703–6.
10. Rouzier C, Soler C, Hofman P, Brennetot C, Bieth E, Pedeutour F. Ovarian dysgerminoma and Apert syndrome. *Pediatr Blood Cancer.* 2008; 50(3):696–8.
11. Zanetta G, Bonazzi C, Cantù M, Binidagger S, Locatelli A, Bratina G, et al. Survival and reproductive function after treatment of malignant germ cell ovarian tumors. *J Clin Oncol.* 2001; 19(4):1015–20.

Дисгермином и трудноћа

Јасмина Поповић^{1,2}, Соња Поп-Трајковић^{1,2}, Милан Стефановић^{1,2}, Милан Тренкић^{1,2}, Александра Арацки-Тренкић³

¹Клинички центар Ниш, Клиника за гинекологију и акушерство, Ниш, Србија;

²Универзитет у Нишу, Медицински факултет, Ниш, Србија;

³Клинички центар Ниш, Одељење за радиологију, Ниш, Србија

САЖЕТАК

Увод Дисгерминоми су тумори герминативних ћелија јајника. Најчешће се јављају код млађих особа и то у дечјем добу. Проблем настаје када се постави дијагноза дисгерминома у репродуктивном периоду и када је потребно лечити га хируршки а болесница још увек није остварила своје потомство.

Приказ болесника Примигравида, 26 година стара, примљена је у клинику у 26. недељи гестације због сумње на експанзиван раст истмичног миома откривеног ултразвучком од гинеколога у примарној здравственој заштити. Код

болеснице је годину и по дана раније урађена левострана аднексектомија због оваријалног дисгерминома. Дијагноза миома материце је била погрешна и радило о дисгерминому десног јајника. Хируршко лечење дисгерминома обављено је након постизања феталне одрживости.

Закључак Малигни тумори јајника могу се јавити код младих жена током трудноће убрзо после хируршког лечења и значајно увећати у кратком периоду.

Кључне речи: дисгермином; тумори герминативних ћелија оваријума; трудноћа