

No Recurrence in Otoplasty: Is That Possible?

Katarina Andjelkov¹, Marcos Sforza², Renato Zaccheddu³, Goran Lazović⁴, Miodrag Colić⁴

¹General Hospital "Belmedic", Belgrade, Serbia;

²UNIFESO School of Medicine, Rio de Janeiro, Brasil;

³Private Practice, Milan, Italy;

⁴Clinic for Burns, Plastic and Reconstructive Surgery, Clinical Centre of Serbia, Belgrade, Serbia

SUMMARY

Introduction Otoplasty or correction of prominent ears, is one of most commonly performed surgeries in plastic surgery both in children and adults. Until nowadays, there have been more than 150 techniques described, but all with certain percentage of recurrence which varies from just a few up to 24.4%.

Objective The authors present an otoplasty technique, a combination of Mustardé's original procedure with other techniques, which they have been using successfully in their everyday surgical practice for the last 9 years. The technique is based on posterior antihelical and conchal approach.

Methods The study included 102 patients (60 males and 42 females) operated on between 1999 and 2008. The age varied between 6 and 49 years. Each procedure was tailored to the aberrant anatomy which was analysed after examination. Indications and the operative procedure are described in step-by-step detail accompanied by drawings and photos taken during the surgery.

Results All patients had bilateral ear deformity. In all cases was performed a posterior antihelical approach. The conchal reduction was done only when necessary and also through the same incision. The follow-up was from 1 to 5 years. There were no recurrent cases. A few minor complications were presented. Postoperative care, complications and advantages compared to other techniques are discussed extensively.

Conclusion All patients showed a high satisfaction rate with the final result and there was no necessity for further surgeries. The technique described in this paper is easy to reproduce even for young surgeons.

Keywords: otoplasty; ear deformity; combined technique; recurrence rate

INTRODUCTION

More than 150 techniques were described in the last 100 years to correct the main causes of the prominent ears [1]. Full thickness cartilage incisions were described by Converse [2] and Pitanguy [3]. Mustardé's [4, 5] otoplasty applies sutures alone to reshape and reposition the prominent ear. Stenstrom's [6] and Chongchet [7] techniques follow the principle described by Gibson and Davis [8] in 1958, that cartilage warps away from the injured surface. Both authors used an anterior approach. Spira [9], in 1969, presented a combination of Mustardé's and Stenstrom techniques. In 1970, Farrior [10] published his technique that combined elements of cartilage sculpturing and suturing. Independently of the approach (anterior or posterior) or the technique used to form the antihelix, recurrence has been a common problem to all [11-20].

OBJECTIVE

The objective of this paper was to present the otoplasty technique used successfully by authors over the last 9 years. The cartilage-breaking technique used by the authors to treat antihelix deformity consists of parallel partial cartilage incisions along the length of the antihelical fold combined with scraping the incised cartilage

and adding horizontal conchoscaphal mattress sutures. The idea of a multiprocedure weakening the cartilage associated with permanent sutures was to decrease the incidence of recurrence.

METHODS

This procedure was employed when ear protrusion was caused by incomplete development of the antihelix with or without some degree of accompanying conchal enlargement. Each procedure was thus tailored to the aberrant anatomy.

Surgeries were performed between 1999 and 2008, total of 102 patients (60 males and 42 females). All patients had bilateral ear deformity. The age varied between 6 and 49 years. In all cases, there was used the posterior approach.

Children up to 12 years old had the procedure under general anaesthesia with local infiltration associated; adults had local infiltration plus sedation. All patients received one dose of Cefalotin Sodium 1 g before surgery.

Surgical technique

Two-percent Xylocaine with epinephrine 1:200,000 is infiltrated subcutaneously on the posterior surfaces of the ear and in the post-auricular sulcus and mastoid area. A posterior

Correspondence to:

Katarina ANDJELKOV
General Hospital "Belmedic"
Koste Jovanovića 87,
11000 Belgrade, Serbia
kandjelkov@hotmail.com

skin excision (ovoid or elliptic) is centred over the depth of the postauricular groove. The contents of the postauricular groove are dissected – the postauricular muscle and the fibrocollagenous tissue surrounding it. Care should be taken to identify the posterior surface of the cartilaginous portion of the external auditory canal, to prevent inadvertent injury. Haemostasis is secured. After that, the scapha is lightly folded onto the concha, and a row of ink marks is made on the anterior ear skin that run from just lateral to the superior portion of the superior crus of the anti-helix down to the scapha near the tail of the helix (Figure 1).

A 27 gauge needle is passed through the ink mark from the anterior to the posterior surface of the ear. A cotton bud dipped in methylene blue is used to wet the distal end of the

needle and its shaft; the needle is then withdrawn, marking the posterior skin and underlying cartilage. The ear is maintained on a light stretch while this marking procedure is carried out, and all previously made ink marks are temporarily tattooed in this fashion (Figure 2). The tattoo points are identified and unified in an ink line that determines our folding point for the new anti-helix. Two additional rows of ink marks are drawn with 2 mm distance from this central line (one above, one below). These three lines are incised only half of the cartilage thickness. It is crucial that this incision does not transfix the cartilage; otherwise the folding point will be very noticeable on the skin – a non-natural result. After the incisions, this area is lightly scored with the blade itself, to weaken this cartilage and facilitate a smooth fold-

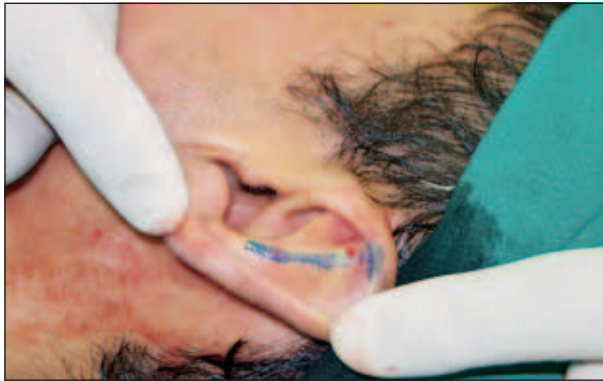

Figure 1. The scapha is lightly folded onto the concha, and a row of ink marks is made

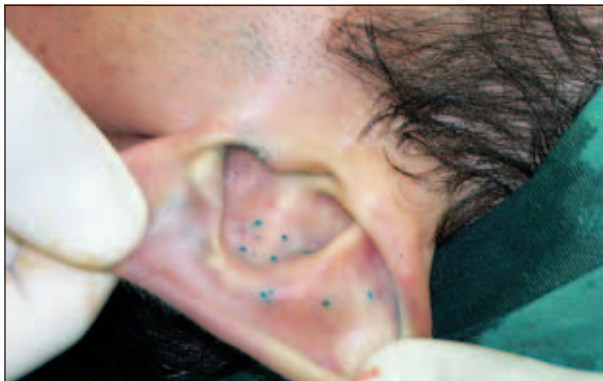

Figure 2. We can see the marks of the needle on the anterior skin. Also the excess concha was marked in this case.

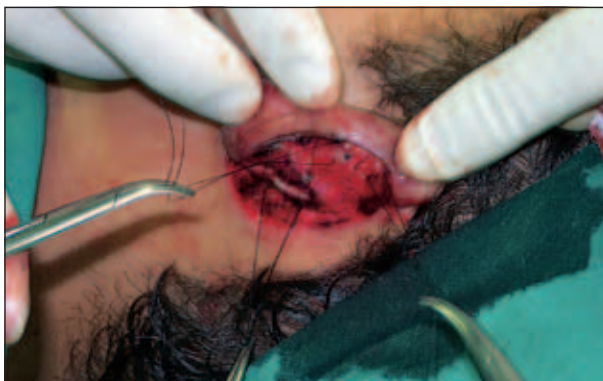

Figure 3. The excess of concha has been removed and we can see the three incisions at the antihelix cartilage, which was also scored. The initial mattress sutures are positioned.

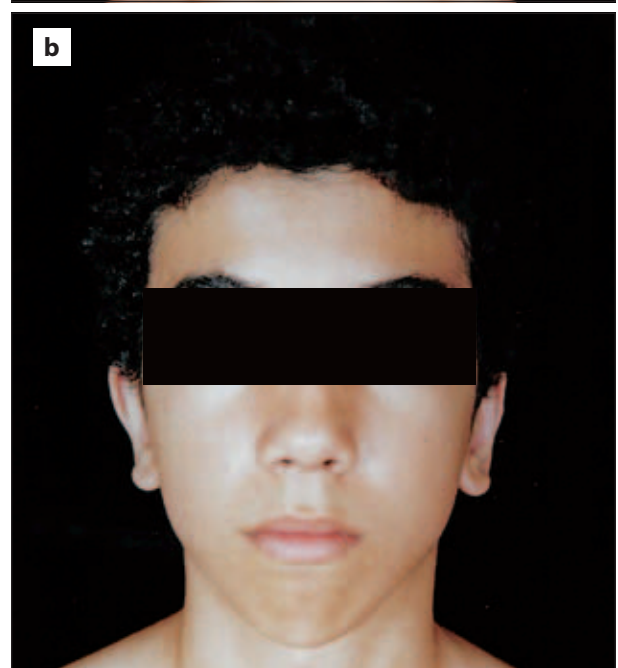
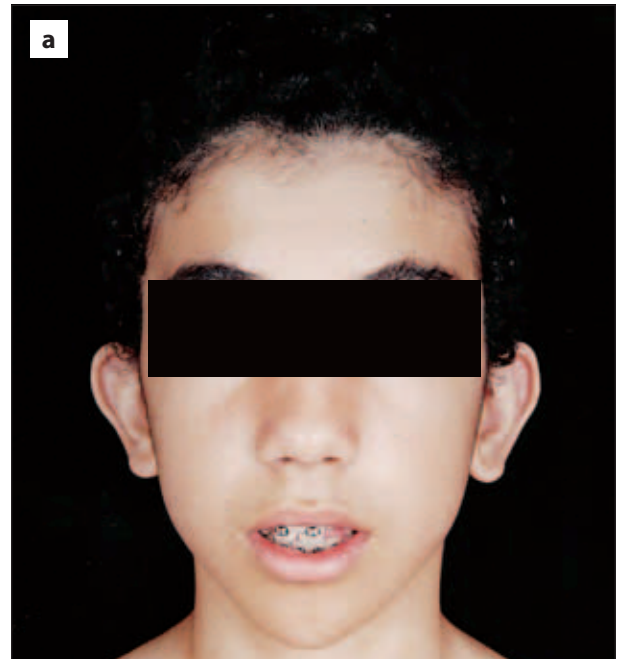

Figure 4. Patient 1, 9 years old: a) preoperative front view; b) postoperative view at 2 years, showing a persistent result

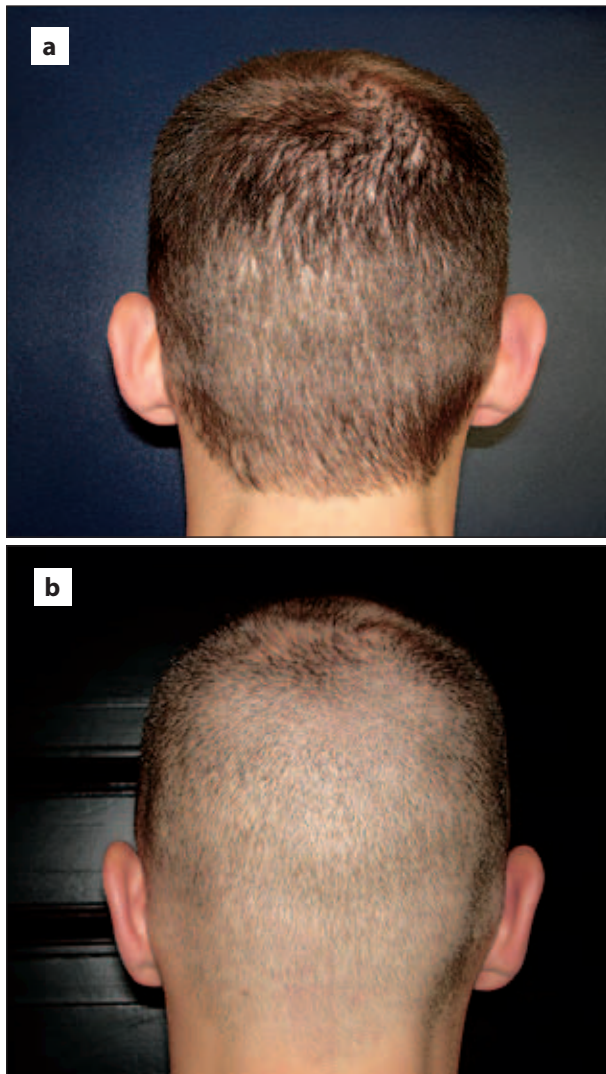


Figure 5. Patient 2, 27 years old: a) preoperative back view; b) postoperative back view after 1 year

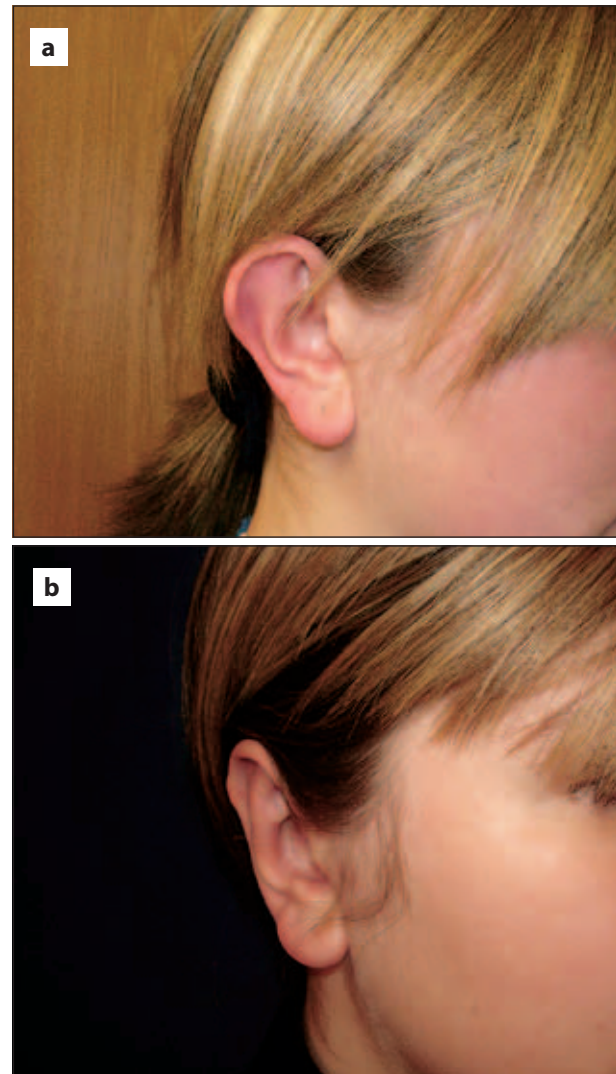


Figure 6. Patient 3, 19 years old: a) preoperative close view; b) postoperative view at 1 year showing a natural and persistent result

ing. Care is taken to align the mattress sutures at the proper distances from the apex of the new antihelical fold to prevent distortion and warping. All sutures are placed before any are permanently tied (Figure 3). The sutures cannot transfix the cartilage either, otherwise it will be visible through the skin. Usually three to six separate sutures of Nylon 4.0 are required. Once the desired antihelical fold is achieved, each suture is then permanently secured, in sequence, from superior to inferior, which allows the tension to secure the desired fold to be adjusted sequentially. The knots are usually tied “blindly” while observing the development of the fold from the anterior aspect.

If the concha is large or angulated, another row of marks is made just medial to the markings described above, usually in a half moon shape. These marks represent conchal excess to be removed. A tattooing procedure is done as described above. The concha malposition is corrected by a conchal setback, a procedure performed very easily through the posterior incision. Resection of the postauricular muscle and fibrofatty tissue bare the conchal cartilage and the mastoid fascia suture placement sites between the concha and mastoid periosteum. Using the posterior approach, only one suture fixation with Nylon 3.0 can be used to hold the retroposition.

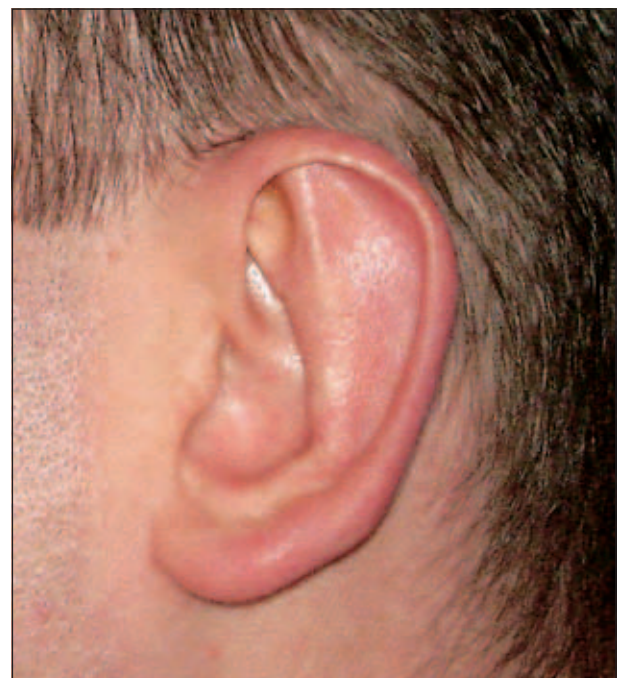

Figure 7. Patient 7, 22 years old: postoperative view at 2 years showing a non-natural contour on the antihelix

At this point, we do a correction of a prominent earlobe, if necessary. Usually it is done by excision of skin in modified "fish tail" shape and placing a single stitch in subcutaneous tissue-to-mastoid periosteum. The opposite ear is marked and done in the same way.

Wet cotton is positioned on the new folds of the ear and vaseline sterile gauzes are put on top of the ears and are held with an Ace bandage. This dressing is left in place for 24 hours. At the next morning postoperative visit, the entire dressing is removed. The patient is then instructed to wear a tennis sweat band day and night for 2 weeks and each night for a month after.

RESULTS

During a period of 9 years, we operated on 102 patients with this technique (Figures 4a,b and 5a,b). All patients had bilateral deformity. The follow-up was from 1 to 5 years (Figure 6a,b).

The required surgery time for each ear was 30-40 minutes. In all cases, the recovery was uneventful, postoperative oedema resolution was fast, with good, unimpaired vascularization and innervation. We did not have any recurrence cases. There were no haematomas, infections, distortions of the auditory canal, psychological complications, hypertrophic scars, or keloid formations. The removal of excess concha in some of our cases resulted in some redundancy of skin which took from three to six months to resolve. Ten percent of patients experienced a moderate postoperative pain or tenderness, which lasted approximately 1-3 days and treated with Nimesulid 100 mg a day. There were no postoperative malpositions of the ears. Three ears (1.5%) did not have a completely smooth and natural shape of the antihelix (Figure 7).

DISCUSSION

In 1968, McDowell [12] proposed the goals of a successful otoplasty. These goals are still appropriate and we should add that the antihelix should have the most natural look as possible, not stigmatize the otoplasty patient [21-25].

REFERENCES

1. Janis JE, Rohrich RJ, Gutowski KA. Otoplasty. *Plast Reconstr Surg.* 2005; 115:60e-72e.
2. Converse JM, Nigro A, Wilson FA, Johnson N. A technique for surgical correction of lop ears. *Plast Reconstr Surg* (1946). 1955; 15:411-8.
3. Pitanguy I, Muller P, Piccolo N, Ramalho E, Solinas R. The treatment of prominent ears: a 25-year survey of the island technique. *Aesthetic Plast Surg.* 1987; 11(2):87-93.
4. Mustardé JC. The correction of prominent ears using simple mattress sutures. *Br J Plast Surg.* 1963; 16:170-8.
5. Mustardé JC. The treatment of prominent ears by buried mattress sutures: a ten-year survey. *Plast Reconstr Surg.* 1967; 39:382-6.
6. Stenstrom SJ. A "natural" technique for correction of congenitally prominent ears. *Plast Reconstr Surg.* 1963; 32:509-18.
7. Chongchet V. A method of antihelix reconstruction. *Br J Plast Surg.* 1963; 16:268-72.
8. Gibson T, Davis W. The distortion of autogenous cartilage grafts: its cause and prevention. *Br J Plast Surg.* 1958; 10:257-74.
9. Spira M, McCrea R, Gerow FJ, Hardy SB. Correction of the principal deformities causing protruding ears. *Plast Reconstr Surg.* 1969; 44:150-4.
10. Farrior RT. Otoplasty for children. *Otolaryngol Clin North Am.* 1970; 3(2):365-74.
11. Luckett WH. A new operation for prominent ears based on the anatomy of the deformity. *Surg Gynecol Obstet.* 1910; 10:635-7.
12. McDowell AJ. Goals in otoplasty for protruding ears. *Plast Reconstr Surg.* 1968; 41:17-27.
13. Stal S, Klebuc M, Spira M. An algorithm for otoplasty. *Oper Tech Plast Reconstr Surg.* 1997; 4:88-103.
14. Hyckel P, Schumann D, Mansel B. Method of Converse for correction of prominent ears: comparison of results. *Acta Chir Plast.* 1990; 32:164-71.

Techniques that apply single treatment of cartilage (only sutures – Mustardé, or only trimming – Stenstrom) are widely used, but have relatively high recurrence rates that vary from 8 to 9.9% for Stenstrom's technique [14, 15] and up to 24.4% for Mustardé's technique [16, 17, 18]. On the other hand, Scharer et al. [20], in a 15-year retrospective study of patients who had Farrior technique, found more than 10% incidence of persistent or recurrent ear protrusion. We believe that such high incidence of recurrence can be avoided with further weakening of cartilage (scoring) [26]. Also, we believe that the combination of procedures was the reason that we did not have cases of cartilage bending in opposite rather than desired direction.

The removal of the excess concha from the posterior side can lead to large redundancy of skin, which takes up to six months to resolve, but with no need for further correction in our experience. That is why many authors prefer doing it through an anterior skin and cartilage excision of the concha [27]. It has been successfully reported that the scar totally fades long before the redundant skin is naturally resolved. So, a long time waiting for the final result is avoided.

The shape and contours obtained by this approach were both aesthetic and natural. Overall, the patient and physician satisfaction during the 9 years that we have been using this technique have continued to be very high. We experienced only a few minor complications that were not directly related to the technique (antihelix contour irregularities). In our opinion, the combination of buried sutures and shallow incisions with scoring to facilitate formation of new antihelix were probably the main reason of very low complication rate that we have with this technique.

CONCLUSION

Using this technique, we obtained favourable results with very low complication rates and no recurrence in all patients. We believe that this is due to the association of multiple cartilage weakening procedures and permanent sutures. One reduces the strength of the cartilage (allowing an easier fold back) and the other holds its position perfectly secure.

This surgical procedure was easier and more effective than other approaches in our hands.

15. Heftner J. Follow-up study on 167 Stenstrom otoplasties. *Clin Plast Surg.* 1978; 5:465-70.
16. Tan KH. Long-term survey of prominent ear surgery: a comparison of two methods. *Br J Plast Surg.* 1986; 39:270-3.
17. Mustarde JC. Results of otoplasty by the author's method. In: RM Goldwyn, editor. *Long-Term Results in Plastic and Reconstructive Surgery.* Boston: Little Brown; 1980. p.139-144.
18. Spira M, Hardy SB. Mustardé's otoplasty: a critical second look. In: Marchac D, Hueston JT, editors. *Transactions of the Sixth International Conference of Plastic and Reconstructive Surgery.* Paris: Masson; 1975. p.297-299.
19. Calder JC, Nasan A. Morbidity of otoplasty: a review of 562 consecutive cases. *Br J Plast Surg.* 1994; 47:170-4.
20. Scharer SA, Fariior EH, Fariior RT. Retrospective analysis of the Fariior technique for otoplasty. *Arch Facial Plast Surg.* 2007; 9:167-73.
21. Elliott RA Jr. Otoplasty: a combined approach. *Clin Plast Surg.* 1990; 17:373-81.
22. Janz BA, Cole P, Hollier LH Jr, Stal S. Treatment of prominent and constricted ear anomalies. *Plast Reconstr Surg.* 2009;124(1 Suppl): 27-37.
23. Da Silva Freitas R, Shin JH, Persing JA, Alonso N, Busato L. Solving sharpness borders in otoplasty. *Plast Reconstr Surg.* 2009; 123(6):197-9.
24. Mathur BS, Shokrollahi K. Precision and suture positioning in otoplasty. Experience with 380 cases. *J Plast Reconstr Aesthet Surg.* 2010; 63(3):571-2.
25. Owsley TG, Biggerstaff TG. Otoplasty complications. *Oral Maxillofac Surg Clin North Am.* 2009; 21(1):105-18.
26. Schlegel-Wagner C, Pabst G, Muller W, Linder T. Otoplasty using a modified anterior scoring technique: standardized measurements of long-term results. *Arch Facial Plast Surg.* 2010; 12(3):143-8.
27. Maslauskas K, Astrauskas T, Viksraitis S, Samsanavidius D. Comparison of otoplasty outcomes using different types of suture materials. *Int Surg.* 2010; 95(1):88-93.

Да ли је изводљива отопластика без рецидива?

Катарина Анђелков¹, Marcos Sforza², Renato Zaccheddu³, Горан Лазовић⁴, Миодраг Цолић⁴

¹Општа болница „Belmedic“, Београд, Србија;

²Медицински факултет УНИФЕСО, Рио де Жанеиро, Бразил;

³Приватна пракса, Милано, Италија;

⁴Клиника за опекотине, пластичну и реконструктивну хирургију, Клинички центар Србије, Београд, Србија

КРАТАК САДРЖАЈ

Увод Отопластика је хируршка корекција клемпавих ушију и једна од најчешће извођених операција у пластичној хирургији како код деце, тако и код одраслих особа. До данас је описано више од 150 техника за корекцију овог деформитета ушне шкољке, али свака с различитим степеном његовог поновног појављивања након извесног времена. Та учесталост варира од неколико процената до 24,4%.

Циљ рада Циљ рада је био да се прикаже техника отопластике коју аутори успешно користе последњих девет година у свакодневној пракси, а која представља комбинацију оригиналне Мистардеове (*Mustardé*) технике и других познатих техника. Описана техника је заснована на инцизији која се налази на задњој страни ушне шкољке преко које се приступа моделирању антихеликса и конхе.

Методе рада Студија је обухватила 102 пацијента (60 мушког и 42 женског пола) старости 6-49 година која су оперисана у

периоду 1999-2008. године. Хируршки план одређиван је понаособ за сваког пацијента у зависности од анатомске структуре ушних шкољки. Индикације и операција су детаљно описани и појашњени одговарајућим фотографијама начињеним током операција.

Резултати Код свих пацијената установљен је деформитет обеју ушних шкољки. У свим случајевима антихеликсу се приступило са задње стране ушне шкољке. Смањење конхе је урађено по потреби и кроз исти рез. Пацијенти су после операције надгледани најдуже пет година. Током овог периода није било рецидива деформитета, али јесте неколико мањих компликација.

Закључак Сви пацијенти били су задовољни крајњим резултатом, те није било потребе за поновном операцијом. Описану технику лако могу да изведу чак и мање искусни хирурзи.

Кључне речи: отопластика; деформитети ушне шкољке; комбинована техника; рекурентни случајеви

Примљен • Received: 16/09/2009

Прихваћен • Accepted: 09/10/2009