

Accidental Macular Hole Following Neodymium:YAG Posterior Capsulotomy

Mihnea Munteanu¹, Žarko Petrović², Horia Stanca³, Cosmin Rosca⁴, Adelina Jianu⁵, Ovidiu Boruga¹

¹Department of Ophthalmology, "Victor Babeș" University of Medicine and Pharmacy, Timisoara, Romania;

²Department of Ophthalmology, "Đorđe Joanović" General Hospital, Zrenjanin, Serbia;

³Department of Ophthalmology, "Carol Davila" University of Medicine and Pharmacy, Bucharest, Romania;

⁴"Optilens" Clinic of Ophthalmology, Cluj-Napoca, Romania;

⁵Department of Anatomy and Embryology, "Victor Babeș" University of Medicine and Pharmacy, Timisoara, Romania

SUMMARY

Introduction Posterior capsular opacification (PCO) is the commonest complication of cataract surgery, occurring in up to one-third of patients in a period of five years. The treatment of choice is the Neodymium:YAG laser posterior capsulotomy. This treatment can be associated with several complications, some of them severe. A rare complication of this procedure is the accidental induced macular hole.

Case Outline A 54-year-old female patient was referred to our Department because of a severe loss of vision and a central scotoma at the right eye. The patient underwent a Nd:YAG posterior capsulotomy 2 days ago, for a PCO. The fundus examination at presentation revealed a round retinal defect in the macular region, a massive inferior preretinal hemorrhage and a mild vitreous hemorrhage. A 6-months follow-up of the case, including retinography and fluorescein angiography, is presented.

Conclusion Although the Nd:YAG laser capsulotomy is a safe, noninvasive, and effective outpatient procedure to improve vision hindered by PCO, it must be recognized that it carries a low but definite risk of serious complications. Physicians and patients should be aware of these rare but severe complications regarding this otherwise safe procedure. Fortunately, most of the complications related to this procedure are transient and can be managed by proper medication.

Keywords: Neodymium:YAG laser; posterior capsulotomy; macular hole

INTRODUCTION

Posterior capsular opacification (PCO) is the commonest complication of cataract surgery, occurring in up to one-third of patients in a period of five years [1]. The treatment of choice is the Neodymium:YAG laser posterior capsulotomy, technique first reported by Aron-Rosa et al. in 1980 [2]. The Nd:YAG laser works on the principle of photodisruption, works at a wavelength of 1064 nm, and can be associated with several complications: transient elevation of the intraocular pressure, damage of the intraocular lens (IOL), glaucoma, cystoid macular edema, iritis, retinal detachment, endophthalmitis, macular hole, macular hemorrhage, vitreous hemorrhage, corneal endothelial damage [3-7]. A particular case of laser-induced traumatic injury is the full thickness macular hole; the minimum energy required to produce it is between 1 and 3 mJ. Injury can occur in the retina adjacent to the impact area, resulting in a fibrovascular scar, possibly associated with retinal or choroidal neovascularization [8]. In those cases, the YAG laser produces photodisruptive and thermal damage to the retina by absorbing the energy on the retinal pigment epithelium, where it can generate heat, producing thermal damage in surrounding tissue.

We report a case of an accidental laser-induced macular hole following ND:YAG pos-

terior capsulotomy; a 6-months follow-up by retinophotography and fluorescein angiography was performed.

CASE REPORT

We report the case of a 54-year-old female patient which was referred to our Department because of a severe loss of vision and a central scotoma at the right eye. The patient underwent cataract surgery by phacoemulsification one year ago, an uncomplicated lens extraction with foldable IOL implantation in the bag being performed; the patient had no history of refractive errors or preexisting retinal diseases (e.g. macular hole). Postoperative evolution was favorable, with a postoperative vision of 1.0. Because the patient was diagnosed with PCO on the right eye, she underwent, 2 days before, a Nd:YAG posterior capsulotomy. Immediately after the laser therapy, the patient noticed a decrease in visual acuity, a central blind spot and floaters in his right eye. From the patient's medical record resulted the following laser parameters: energy of 5 mJ per pulse, pulse duration of 8 ns, and a total of 32 laser pulses. At the time of examination in our Department, 48 h after the laser procedure, the best corrected visual acuity (BCVA) was 20/200 in the right eye and 20/20 in the left eye. The

Correspondence to:

Mihnea MUNTEANU
Department of Ophthalmology
"Victor Babeș" University of
Medicine and Pharmacy
Piata E. Murgu 3
300041 Timisoara
Romania
mihneam1@gmail.com

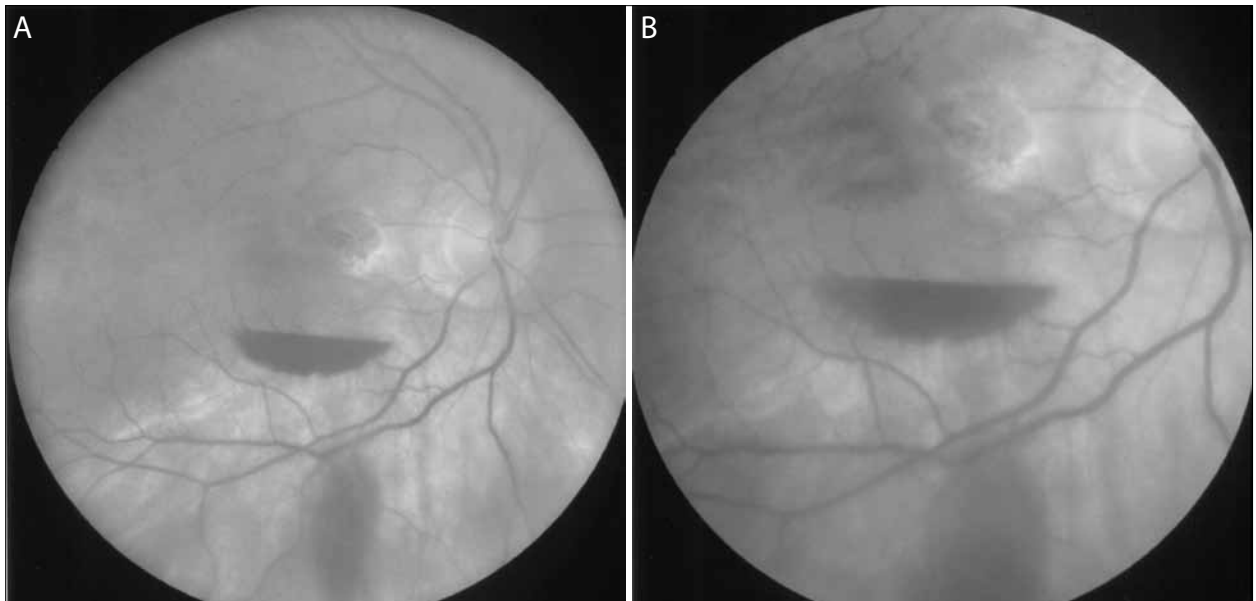


Figure 1. Retinography at presentation – white, crater-shaped, juxtamacular burn, a large preretinal „swallow’s nest” hemorrhage and mild vitreous hemorrhage; (A) overview image; (B) detailed image.

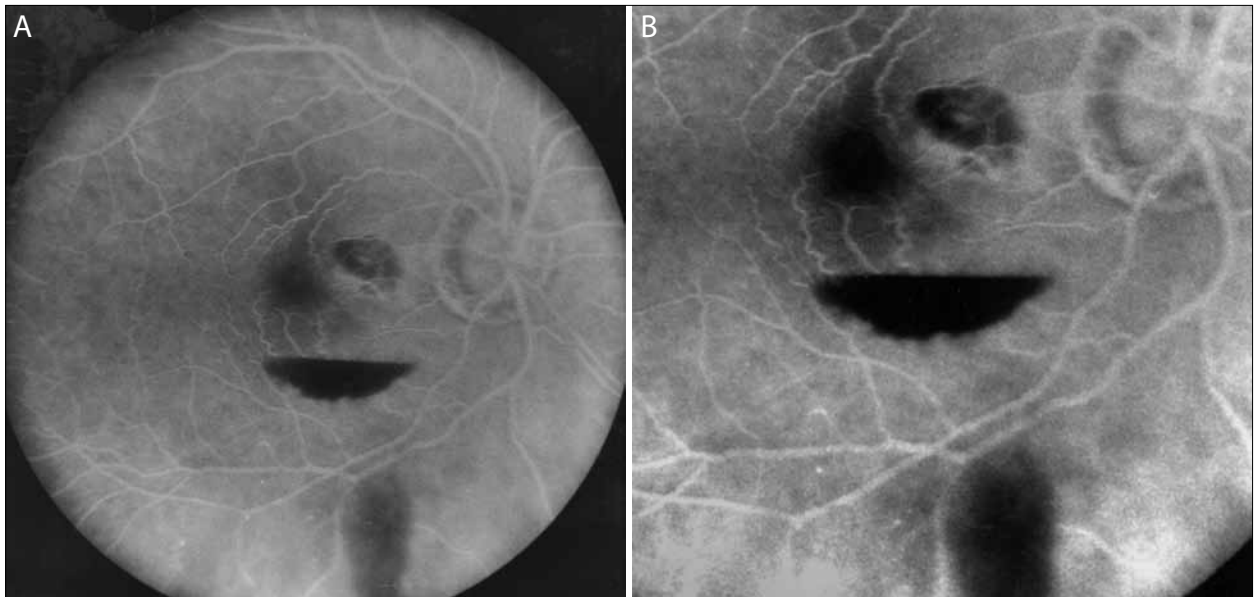


Figure 2. Fluorescein angiography at presentation – round, juxtamacular area of hypofluorescence, with discrete early hyperfluorescence at the base of the hole (window defect), a larger, inferior located area of hypofluorescence, corresponding to the preretinal hemorrhage; (A) overview image; (B) detailed image.

examination of the right fundus revealed a marked white, crater-shaped, juxtamacular burn, a large preretinal „swallow’s nest” hemorrhage and vitreous hemorrhage (Figures 1A and 1B). The fluorescein angiography (FAG) revealed at the right eye a round, juxtamacular area of hypofluorescence, with discrete early hyperfluorescence at the base of the hole (window defect), and a larger, inferior located area of hypofluorescence, corresponding to the preretinal hemorrhage (Figures 2A and 2B).

After 6 months, the retinophotography revealed the complete resorption of the hemorrhage, and a full-thickness retinal, juxtamacular hole resulting from the YAG laser impact; the lesion expanded compared to the first retinography and included partially the macular area, turning into an atrophic hole (Figure 3). The FAG re-

vealed a round hypofluorescent chorioretinal scar, with visibility of the large choroidal vessels at the base of the hole, revealing the obliteration of the choriocapillaris at the laser site (Figure 4). The final visual acuity at the right eye was 20/50.

DISCUSSION

Although the Nd:YAG laser capsulotomy is a safe, non-invasive, and effective outpatient procedure to improve vision hindered by PCO, still many authors described retinal lesions induced by Nd:YAG lasers, mostly during laser adjustment and alignment. Liu et al. [9] presented a series of 31 eyes (29 cases) of ocular injuries by accidental

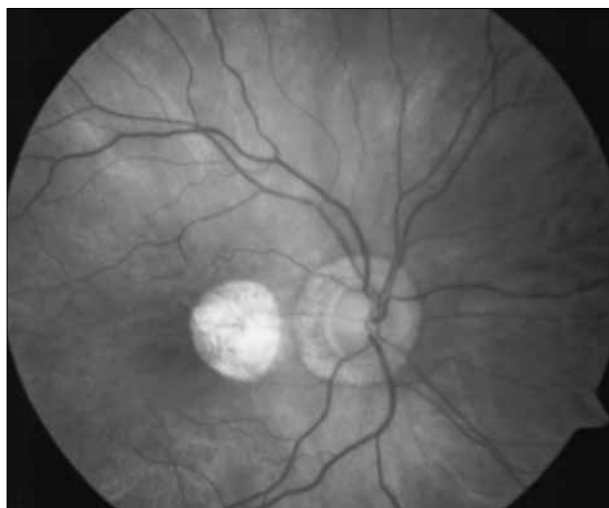


Figure 3. Retinography at 6 months – full-thickness retinal hole

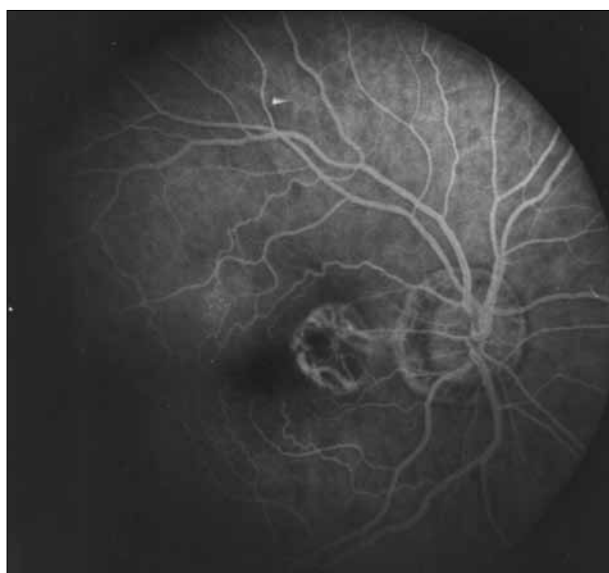


Figure 4. Fluorescein angiography at 6 months – round hypofluorescent chorioretinal scar, with visibility of the large choroidal vessels at the base of the hole, revealing the obliteration of the choriocapillaris at the laser site

laser exposure and 28 eyes (90%) were injured during the time of laser adjustment and alignment; the macula was involved in 25 eyes. Other authors report an incidence of 2% of macular holes induced by Nd:Yag laser regarding to the clinical data of 497 eyes of 497 patients receiving Nd:YAG capsulotomy [10]. The nature and severity of the laser-induced retinal injury is determined by multiple laser-related and eye-related factors, the most important being the duration and amount of energy delivered and the retinal location of the lesion [11]. The minimum total intraocular laser energy needed to cause a macular hole is reported to be at the order of 1–3 mJ [12]. The evolution of most retinal laser injuries is characterized by a sudden loss of vision, often followed by marked improvement over a few weeks, and sometimes severe late complications. Medical treatment is, however, limited in these cases.

The indications of surgery have not been clearly defined; there have been reports of laser-induced macular holes being successfully treated by early surgical intervention, performed at 4 and 6 weeks after the injury [13, 14]. In most cases, the surgery was performed by pars plana vitrectomy, peeling of internal limiting membrane, with or without internal tamponade with gas or silicone oil. We considered this type of surgical treatment, given the large size of the patient's macular hole, but because of her unwillingness to undergo another procedure, no medical or surgical management was performed at this stage.

Interesting is the natural evolution of such lesions; there are reported cases in which macular hole closed spontaneously, with improved visual function or with stationary evolution [15, 16]. In contrast to the idiopathic macular hole, the Nd:YAG laser-induced macular hole is produced by direct laser photothermolysis with destruction all retinal layers [17]. Therefore those patients with laser-induced macular lesions are not regaining vision because of the permanent damages at the photoreceptor and retinal pigment epithelium layer at the fovea region during the injury, the laser energy being absorbed by the melanin granules in the retinal pigment epithelium and choroidal melanocytes. In severe injuries, like in our case, the damage can extend to the choroidal level and might impair the choroidal circulation [12]. With the expanding use of laser devices, the frequency with which they produce accidental injuries increases. Many cases of the accidental laser-induced injuries have been reported during the calibration of the device; also, many accidents happen in salons or cosmetic dermatology offices where the Nd:Yag laser is used to remove skin lesions or tattoos [18]. Few cases are reported after posterior capsulotomy, like in our patient. Laser energy, distance from the fovea, and dimensions of lesions are important prognostic factors of visual function. Although the lesion looked to be at some distance from the fovea, the visual acuity was not entirely recovered. This may be due to the shock wave that starts from the laser impact to the surrounding areas, causing significant mechanical damage, and also because the initial, relatively small retinal lesion expanded in time, including a part of the macular region. The evolution in our case was similar to the ones described in the literature, evolving towards an atrophic retinal hole, with a reasonable, partially, and spontaneous recovery of vision. It is important to emphasize that a good anatomic result (closed hole) is not necessarily accompanied by good functional results, because the laser impact is associated with a thermolitic destruction of retinal layers, permanent damage to the photoreceptors and retinal pigment epithelium [19]. The lesions can also extend to the choroid, like in our case, leading to a poor prognosis.

As a preventive measure, we strongly suggest that laser energy should be kept to a minimum level when performing posterior capsulotomy, and also that the procedure should be performed by an experienced physician in order to avoid such severe complications.

REFERENCES

- Schaumberg DA, Dana MR, Christen WG, Glynn RJ. A systematic overview of the incidence of posterior capsule opacification. *Ophthalmology*. 1998; 105:1213-21.
- Aron-Rosa D, Aron JJ, Griesemann M, Thyzel R. Use of the neodymium-YAG laser to open the posterior capsule after lens implant surgery: a preliminary report. *J Am Intraocul Implant Soc*. 1980; 6(4):352-4.
- Dawood Z, Mirza SA, Qadeer A. Review of 560 cases of YAG laser capsulotomy. *Lumhs*. 2007; 6(1):3-7.
- Khan MY, Jan S, Khan MN, Khan S, Kundi N. Visual outcome after Nd:YAG capsulotomy in posterior capsular opacification. *Pak J Ophthalmol*. 2006; 22(2):87-91.
- Kanski JJ. Acquired macular disorders and related conditions. In: Kanski JJ, editor. *Clinical Ophthalmology. A Systematic Approach*. 6th ed. London: Butterworth-Heinemann; 2007. p.627-661.
- Burq MA, Taqui AM. Frequency of retinal detachment and other complications after neodymium:Yag laser capsulotomy. *J Pak Med Assoc*. 2008; 58(10):550-2.
- Kerr Muir MG, Sherrard ES. Damage to the corneal endothelium during Nd:YAG photodisruption. *Br J Ophthalmol*. 1985; 69(2):77-85.
- Ying HS, Symons RC, Lin KL, Solomon SD, Gehlbach PL. Accidental Nd:YAG laser-induced choroidal neovascularization. *Lasers Surg Med*. 2008; 40(4):240-2.
- Liu HF, Gao GH, Wu DC, Xu GD, Shi LS, Xu JM, et al. Ocular injuries from accidental laser exposure. *Health Phys*. 1989; 56(5):711-6.
- Li J, Li Z, Wu M, Hu Z. Complications of the posterior ocular segment following the Nd:YAG capsulotomy. *Chinese Ophthalmic Research*. 2010; 28(4):365-7.
- Barkana Y, Belkin M. Laser eye injuries. *Surv Ophthalmol*. 2000; 44(6):459-78.
- Allen RD, Brown J Jr, Zwick H, Schuschereba ST, Lund DJ, Stuck BE. Laser-induced macular holes demonstrate impaired choroidal perfusion. *Retina*. 2004; 24(1):92-7.
- Ben-Simon GJ, Nemet A, Moisseiev J. Vitrectomy with indocyanine green-guided inner limiting membrane peeling for a Q-switched Nd:YAG laser-induced macular hole. *Retina*. 2003; 23(5):714-6.
- Sou R, Kusaka S, Ohji M, Gomi F, Ikuno Y, Tano Y. Optical coherence tomographic evaluation of a surgically treated traumatic macular hole secondary to Nd:YAG laser injury. *Am J Ophthalmol*. 2003; 135:537-9.
- Thach AB, Lopez PF, Snady-McCoy LC, Golub BM, Frambach DA. Accidental Nd:YAG laser injuries to the macula. *Am J Ophthalmol*. 1995; 119:767-73.
- Newman DK, Flanagan DW. Spontaneous closure of a macular hole secondary to an accidental laser injury. *Br J Ophthalmol*. 2000; 84:1075-82.
- Gao L, Dong F, Chan WM. Traumatic macular hole secondary to Nd:YAG laser. *Eye (Lond)*. 2007; 21(4):571-3.
- Kim DB, Jung MO, Lee DW, Choi GJ, Kim DH. A case of macular hole after exposure to tattoo removal by q-switched Neodymium:YAG laser. *J Korean Ophthalmol Soc*. 2011; 52(3):373-7.
- Chuang LH, Lai CC, Yang KJ, Chen TL, Ku WC. A traumatic macular hole secondary to a high-energy Nd:YAG laser. *Ophthalmic Surg Lasers*. 2001; 32(1):73-6.

Задесна руптура макуле након задње капсулотомије Nd:YAG ласером

Михнеа Мунтеану¹, Жарко Петровић², Хориа Станка³, Космин Роска⁴, Аделина Жијану⁵, Овидију Боруга¹

¹Офталмолошко одељење, Медицински и фармацеутски факултет „Виктор Бабеш“, Темишвар, Румунија;

²Офталмолошко одељење, Општа болница „Ђорђе Јоановић“, Зрењанин, Србија;

³Офталмолошко одељење, Медицински и фармацеутски факултет „Карол Давила“, Букурешт, Румунија;

⁴Офталмолошка клиника „Оптиленс“, Клуж-Напока, Румунија;

⁵Одељење за анатомију и ембриологију, Медицински и фармацеутски факултет „Виктор Бабеш“, Темишвар, Румунија

КРАТАК САДРЖАЈ

Увод Замућење задње капсуле (енгл. *posterior capsule defect – PCD*) је најчешћа компликација хируршког лечења катаракте, а јавља се код трећине болесника током петогодишњег периода. Лечење избора је задња капсулотомија Nd:YAG ласером. Ову врсту лечења могу да прате одређене компликације, од којих су неке веома тешке и ретке. У раду је описана једна таква компликација – индукована задесна руптура макуле.

Приказ болесника Болесница стара 54 године упућена је на наше одељење због тешког губитка вида и централног скотома десног ока. Лечена је због *PCD* задњом капсулотомијом Nd:YAG ласером током два дана. Преглед фундуса на пријему у болницу показао је округли ретинални пореме-

ћај макуларне регије, обилно крварење доње предретине и слабо крварење очног желатина. Болесница је клинички праћена шест месеци, током којих су обављена испитивања ретинографијом и флуоресцентном ангиографијом.

Закључак Премда је задња капсулотомија Nd:YAG ласером безбедан, неинвазиван и ефикасан амбулантни захват који се примењује ради побољшања вида оштећеног због *PCD*, мора се имати на уму да поступак прати ретка, али тешка компликација овог иначе поузданог поступка. Срећом, већина компликација које прате овај поступак су видљиве и могу да се излече применом одговарајуће терапије.

Кључне речи: Nd:YAG ласер; задња капсулотомија; руптура макуле

Примљен • Received: 09/08/2013

Ревизија • Revision: 20/11/2013

Прихваћен • Accepted: 14/01/2014